

From the Division of Periodontology
Department of Dental Medicine
Karolinska Institutet, Stockholm, Sweden

EVALUATION OF COMPUTER-ASSISTED VIRTUAL TREATMENT PLANNING AND TEMPLATE- GUIDED SURGERY IN DENTAL IMPLANT TREATMENT

Ai Komiya



**Karolinska
Institutet**

200
1810 – 2010 *Ark*

Stockholm 2010

External Examiner

Professor Lars Sennerby D.D.S., Odont Dr.
Department of Biomaterials, Institute for Surgical Sciences, Sahlgrenska Academy,
Gothenburg University, Gothenburg, Sweden

Examining Committee

Professor Ulf Lekholm D.D.S., Odont Dr.
The Specialist Clinic of Oral and Maxillofacial Surgery, Public Dental Health Service of
Västra Götaland and the Sahlgrenska Academy, Gothenburg University, Gothenburg,
Sweden

Docent Helene Thorstensson D.D.S., Odont Dr.
Department of Periodontology, The Institute for Postgraduate Dental Education,
Jönköping, Sweden.

Docent Mats Trulsson D.D.S., Ph.D.
Division of Prosthetic Dentistry, Department of Dental Medicine, Karolinska Institutet,
Huddinge, Sweden

Supervisors

Margareta Hultin D.D.S., Odont.Dr.
Assistant Professor; Division of Periodontology, Department of Dental Medicine,
Karolinska Institutet, Huddinge, Sweden

Björn Klinge D.D.S., Odont.Dr.
Professor, Chair of Division; Division of Periodontology, Department of Dental Medicine,
Karolinska Institutet, Huddinge, Sweden

Author's address

Ai Komiyama, D.D.S.

Division of Periodontology,
Department of Dental Medicine,
Karolinska Institutet,
P.O. Box 4064, SE-141 04
Huddinge, Sweden

e-mail: ai.komiyama@me.com

(Address in Japan)
6-4-1304, Sanbancho,
Chiyoda-ku,
Tokyo 102-0075
Japan

All published papers are reproduced with permission from the respective publisher.

Published by Karolinska Institutet.

Printed by Larserics Digital Print AB, Landsvägen 65 Sundbyberg.

© Ai Komiyama, 2010

ISBN 978-91-7409-917-1

"The living tissue is wiser than the human being!"

Yataro Komiyama

ABSTRACT

One of the newly introduced concepts in implant dentistry is computer-guided surgery. The development of 3D implant planning software and imaging technology provide clinicians with 3D information of patients' bony structures. Furthermore, the combination of such image technologies and the CAD/CAM technology allows fabrication of surgical templates and implant supported prostheses preoperatively based on the virtual treatment planning. However, whether the new method can offer patients as successful and reliable treatment as the conventional methods has not yet been shown scientifically.

The general aim of this thesis was to evaluate computer-assisted virtual treatment planning and template-guided implant surgery. *Study I* and *Study II* aimed to evaluate the clinical performance, including survival rates, complications, soft tissue conditions, and marginal bone changes following the template-guided surgery in combination with immediate loading of a prefabricated prosthesis. In *Study III and Study IV*, the aim was to verify the accuracy of virtually planned and template-guided implant surgery.

Patients with edentulous maxilla, mandible or both, consecutively treated using the NobelGuide™ and Teeth-in-an-Hour™ were included in this project. In *Study I*, survival rates and complications during the follow-up period were investigated. The results showed that survival rates of implants and prostheses were lower compared to those following conventional treatment protocols. Furthermore, complications occurred in as many as 42 % of the treated cases. Most observed complications were related to this specific technique or hardware. *Study II* assessed soft tissue conditions and marginal bone changes at ≥ 1 year follow-up. A pressure-like-ulcer was one of the most frequently observed complications during the follow-up period. Although the mean marginal bone loss after functional loading in *Study II* was within the range of other reports presenting mean bone loss data after immediate loading, our patients showed a wide range of bone loss at several sites, where the bone loss was greater than commonly used successful level (< 1.5 mm after 1 year of prosthesis connection). *Study III and IV* showed that there were significant differences between virtually planned implant positions and the clinically placed implant positions. In *Study III*, the accuracy was assessed by matching the implant planning data based on the pre-operative CT

scan and the post-operative CT scan from ≥ 1 year follow-up. In this matching method, patient movement during CT scan was one of the main factors that contributed to the deviations. In *Study IV*, we developed a novel method. In this method, two plaster models were compared, one created from the surgical template and the other made from impressions on copings attached to the implants in patients at ≥ 1 -year follow-up. The matching procedure, best-fit alignment, might have led to the smaller deviations compared to the results of CT matching method.

In the guided-surgery technique used in these studies, the surgery including prosthesis connection was completed within 30-45 minutes, with minimal surgical trauma in the majority of individuals. In addition, the patients' post-operative discomfort such as pain and swelling was almost negligible in successfully treated cases. However, the results in the present studies imply that the method of computer-assisted treatment and template-guided surgery must still be regarded as being in an exploratory phase. Further investigations regarding the clinical performance and products as well assessments from the patient's viewpoint will lead to more optimal results and improvement of the system.

Keywords: dental implant, computer-guided surgery, surgical template, flapless surgery, immediate loading, CAD/CAM technique, marginal bone loss, soft tissue condition, accuracy

LIST OF PUBLICATIONS

This thesis is based on the following papers, which will be referred to in the text by their Roman numerals:

- I. Komiyama A, Klinge B, Hultin M
Treatment outcome of immediately loaded implants installed in edentulous jaws following computer-assisted virtual treatment planning and flapless surgery. *Clinical Oral Implants Research* 2008; 19: 677-685
- II. Komiyama A, Hultin M, Näsström K, Benchimol D, Klinge B
Soft tissue conditions and marginal bone changes around immediately loaded implants inserted in edentate jaws following computer guided treatment planning and flapless surgery: A \geq 1-year clinical follow-up study. *Clinical Implant Dentistry and Related Research* 2009; Published online
- III. Pettersson A, Komiyama A, Hultin M, Näsström K, Klinge B
Accuracy of virtually planned and template guided implant surgery on edentate patients. *Clinical Implant Dentistry and Related Research*; in-press
- IV. Komiyama A, Pettersson A, Hultin M, Näsström K, Klinge B
Impression model matching and accuracy of virtually planned and template-guided implant surgery on edentate patients
Clinical Oral Implants Research; Submitted

CONTENTS

Introduction.....	1
Background	1
Developments of dental implant treatment.....	1
Osseointegration.....	1
History	1
Bone healing process	2
Time of implant loading	2
Imaging technology	6
CAD/CAM technology	7
Flapless surgery.....	7
Computer-assisted surgery.....	8
Assessments of computer-guided implant treatment.....	10
Clinical assessments.....	10
Clinical outcome of template-guided implant surgery; Survival rate and complications	10
Marginal bone loss.....	11
Clinical inflammation	12
Probing depth.....	13
Oral hygiene.....	13
Implant stability	14
Accuracy of template-guided implant placement	15
Patient-centered assessments	16
Aims.....	19
General aim	19
Specific aims of studies.....	19
Material and methods	20
Subjects.....	20
Ethical considerations	21
Methods	22
Treatment protocol.....	23
Protocol of ≥ 1 -year follow-up	26
Clinical examination	27
Treatment outcome; Survival rate and complications.....	27
Plaque.....	27
Probing depth.....	27
Clinical inflammation	28
Implant stability	28
Radiographic examination	28
Evaluation of marginal bone changes.....	28
<i>Panoramic Radiograph</i>	28
<i>Intraoral Radiograph</i>	29
Evaluation of accuracy.....	30
CT matching.....	30
Impression model matching.....	31
Statistical analyses	31

Results	33
Clinical examination	33
Survival and losses	33
Complications.....	34
Soft-tissue condition.....	37
Implant stability.....	38
Radiographic examination	39
Marginal bone changes	39
Evaluation of accuracy	43
Discussion.....	46
Clinical performance	46
Radiographic marginal bone changes	49
Accuracy of template-guided implant placement	52
Main findings.....	56
Concluding remarks	57
Acknowledgements	58
References	60

LIST OF ABBREVIATIONS

ANOVA	Analysis of Variance
BoP	Bleeding on Probing
CAD/CAM	Computer-Aided Design / Computer-Aided Manufacturing
CBCT	Cone Beam Computed Tomography
CSR	Cumulative Survival Rate
CT	Computed Tomography
DICOM	Digital Imaging and Communications in Medicine
ISQ	Implant Stability Quotient
MSCT	Multi Slice Computed Tomography
PAL	Probing Attachment Level
PD	Probing Depth
PI	Plaque Index
PIB	Procera® Implant Bridge
RCT	Randomized Controlled Trial
RFA	Resonance Frequency Analysis
ROC curve	Receiver Operating Characteristic curve
RP	Regular Platform
2D	Two-Dimensional
3D	Three-Dimensional

INTRODUCTION

BACKGROUND

Osseointegrated dental implant treatment is one of the most innovative concepts in the history of modern dentistry. Today, dental implants are routinely used in the rehabilitation of lost teeth. Over the last decades, a tremendous amount of research has been conducted in order to evaluate the long-term stability of the original protocol as well as to further improve the treatment. In keeping with the rapid development in computer technology, the mode of the implant treatment has also changed. Computer-assisted implant treatment is becoming a trend in implant dentistry and new systems are introduced on the market one after another. This thesis evaluates the NobelGuide™ (Nobel Biocare AB, Gothenburg, Sweden), one of the newly introduced computer-assisted surgical techniques.

DEVELOPMENTS OF DENTAL IMPLANT TREATMENT

Osseointegration

History

The concept of osseointegration arose from an unexpected occurrence during experimental work by Professor P-I Brånemark and collaborators nearly half a century ago in Sweden. A rigid integration between the bone and titanium surface was discovered when he tried to extract a valuable titanium chamber that had been inserted into a rabbit fibula in order to observe the formation of blood cells in the bone marrow. The remarkable fact was that foreign-body reactions, commonly observed as inflammation, did not exist around the titanium chamber. This phenomenon, found by chance, was afterwards named “osseointegration” by Brånemark. Until now, the term osseointegration has been defined from various aspects. The original definition attributed to microscopic findings by Brånemark et al. was “direct structural and functional connection between ordered, living bone and the surface of a load-carrying titanium implant”. It was also defined from a clinical point of view, as “a process whereby clinically asymptomatic rigid fixation of alloplastic materials is achieved and maintained in bone during functional loading“ (Zarb & Albrektsson 1991).

Based on meticulously investigated scientific data, the concept of osseointegration was first applied to a patient for rehabilitation of the edentulous mandible in 1965 (Brånemark et al. 1977). Since then, successful long-term results of

implant-supported prosthesis have been presented in numerous studies (Adell et al., 1990, Hultin et al., 2000, Ekelund et al., 2003, Lekholm et al., 2006, Åstrand et al., 2008), which allowed implant treatment to become a routine method in the rehabilitation of partially and completely edentulous jaws. The application of the osseointegration concept has broadened beyond the dental field, and today it is widely utilised for reconstruction of defects in various parts of the body, such as faces, ears, hands, and legs.

Bone healing process

Titanium is an excellent biocompatible material that generally does not cause any foreign body reaction, if minimising trauma during surgery. Nonetheless, the fact is that the recipient bone is mechanically injured by osteotomy for the canal preparation and insertion of implant during the surgery. The damages initiate a sequence of healing events that arise both in the cortical and the cancellous bone following implant insertion. The dynamic relation between inserted implant and bone tissue is comprised of three periods, healing period (implant insertion-12 months), remodelling period (3-12 months) and dynamic equilibrium period (18 months-) (Brånemark et al., 1977). Around implants immediately after insertion, the pitches of the threads have close contact with the surrounding bone tissue while the cavities of the threads are filled with hematoma. The hematoma transforms into new bone via callus formation and the surgically damaged bone heals, accompanying vascular structures during the first three months of healing period. It has been shown that the bone formation process starts already during the first week of the healing (Berglundh et al., 2003). After the healing phase, the bone tissue close to the interface of the implant surface undergoes a remodelling, which is regarded as an adaptation to the new functional situation where the abutment is connected onto the implants and masticatory load is applied. In the dynamic equilibrium period, about 18 months after the implant insertion, a balance between the remodelling capacity of the bone and the stress transmitting onto the implant is established.

Time of implant loading

The semantics describing implant loading are still a subject of controversy and confusing on many occasions, though some definitions have been propounded in the consensus statements (Cochran et al., 2004, Aparicio et al., 2003). According to the Implant World Congress consensus meeting in Barcelona in 2002 (Aparicio et al.,

2003), the terminology for implant loading and the timing for implant loading protocol was proposed as follows:

Implant loading

- ***Occlusal loading:*** The crown/bridge is in contact with opposing dentition in centric occlusion.
- ***Non-occlusal loading:*** The crown/bridge is not in contact in centric occlusion with opposing dentition in natural jaw positions.

Timing of implant loading

- ***Delayed loading:*** The prosthesis is attached at a second procedure after a conventional healing period of 3-6 months.
- ***Early loading:*** The prosthesis is attached at a second procedure, earlier than the conventional healing period of 3-6 months; time of loading should be stated in days/weeks.
- ***Immediate loading:*** The prosthesis is attached to the implants the same day the implants are placed.

The original protocol proposed by Brånemark was designed to be a two-stage surgical protocol. In this protocol, the implants were recommended to be submerged underneath the mucosa during the initial healing period, usually 3 to 4 months in the mandible and 6 months in the maxilla after implant insertion. Abutments that penetrate the mucous membrane are attached on the implants after the healing period. This procedure aims to minimise the risk of infection, prevent apical downgrowth of mucosal epithelium, and minimise the risk of excessive loading onto the implants (Brånemark et al., 1969, Brånemark et al., 1977). In 1970's and 80's, several experimental studies showed that implant loading during the conventional unloaded phase leads to formation of fibrous tissue instead of formation of bone tissue (Brunski et al., 1979, Akagawa et al., 1986, Cameron et al., 1973). However, the conventional healing period of 3 to 6 months was empirically determined and was not based on conclusive data.

Although the conventional two-stage protocol with delayed loading may still be considered as the most reliable and safe method for achieving osseointegration, many studies have been conducted in order to guide the way towards further developments, especially aiming to minimise the patient's discomfort between implant

insertion and delivery of a fixed prosthesis. The first longitudinal report on immediate loading of Brånemark implants was made by Schnitman and collaborators in 1990 (Schnitman et al., 1990). They also published ten-year follow-up results in 1997 (Schnitman et al., 1997). In their study, 63 implants were installed in the mandible, 28 of which were implants immediately loaded using fixed provisional prostheses. The ten-year survival rate of the immediately loaded implants was 84.7 % (24/28). Following the Schnitman study, a number of studies have reported favourable results of early/immediately loaded implants, showing data comparable with those of the conventional two-stage surgery with delayed loading (Brånemark et al., 1999, Balshi et al., 2005, Degidi et al., 2005, Östman et al., 2005, Sanna et al., 2007).

These clinical results have also been supported in some ways by several experimental literatures. In histological evaluations, it was shown that BIC (bone-implant contact) of immediately/early loaded implants was comparable, or in some cases even better, to that of conventionally loaded implants (Piattelli et al., 1998, Testori et al., 2002, Rocci et al., 2003). Regarding exposure of implant to micromotion in the healing process, Szmukler et al. concluded in their review of experimental literature, that micromovements during the healing process may not deteriorate the integration process if the movements were not excessive (Szmukler-Moncler et al., 1998). Søballe et al. reported that a threshold of micromovements of 50-150 µm may be tolerated for porous plasma-sprayed implants (Søballe et al., 1993). Another study by Brunski stated that approximately 100 µm might be a suitable threshold for turned implant surface (Brunski, 1999). These data suggested that conventional healing period without loading might not be mandatory to achieve osseointegration under the optimal loading condition.

A recently updated systematic review published by the Cochrane Collaboration (Esposito et al., 2009) investigates treatment outcomes of immediately or early loaded implants compared to implants loaded after a conventional healing period. In this systematic review, 22 RCTs (Randomised Controlled Trials) having a follow-up period of 4 months to 1 year, were included. The analyses of the review showed that there were no statistically significant differences regarding prosthesis success, implant success or marginal bone levels, among the different loading regimens. Despite the non-statistical relevance, they reported some clear tendencies. The risk of failure seemed to be higher in immediately loaded implants than in conventionally loaded implants, but lower than early loaded implants. The authors concluded that it is possible to successfully load implants immediately or early after implant insertion in selected

patients, though not all clinicians may be able to achieve optimal results. It was also noted that more well-designed studies are required in order to understand further details about predictabilities of implants loaded at differing time points.

Survival rates of immediately loaded implants inserted in completely edentulous jaws have been reviewed (Del Fabbro et al., 2006, Östman, 2008). According to the literature, immediately loaded implants in a completely edentulous mandible could be a predictable treatment option, with a survival rate of 98%. As for immediately loaded implants placed in the completely edentulous maxilla, the survival rate was 97 %, though the number of long-term studies is still rather limited. It has been shown that the use of slightly tapered implants with a moderately rough surface or a bone density-adapted surgical protocol improved the implant survival rates in soft bone such as the maxilla (Glaser et al., 2005, Östman et al., 2005). More than 70 % of the implant failures were recorded within six months from the time of immediate loading of the implants. These reviews emphasised that the key factor for the success of immediate loading is adequate initial stability, and therefore several factors such as patient selection, implant micromorphology , rigid sprinting, occlusal control should also be thoroughly considered.

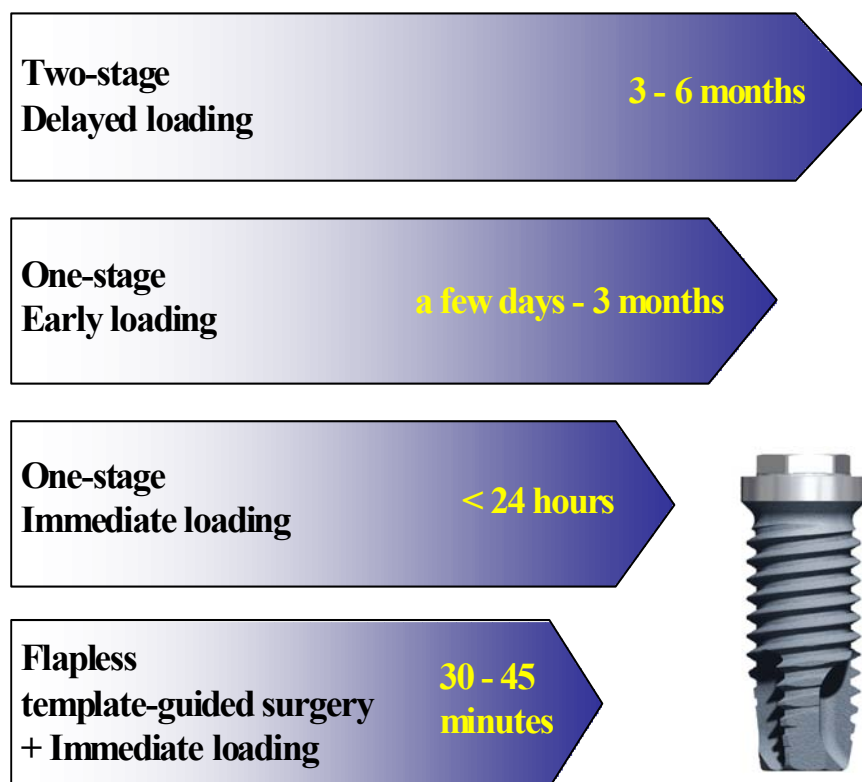


Figure 1. Timing of implant loading

Imaging technology

Conventional radiographic techniques, such as intraoral, panoramic and cephalometric radiographs, have been commonly used as standard diagnostic tools during the last decades of dental implant treatment. However, 2D (two dimensional) radiographic images have not always provided sufficient information for pre-operative assessments and planning, especially in cases with severe bone loss and complex osseous morphology. In implant treatment, it is also crucial to correctly identify the anatomically important structures such as the mandibular canal, maxillary sinus, nasal cavity, and incisor canal in order to avoid damage during the surgery. In addition, it is also important to assess the bone width, height and bone quality.

Conventional tomography has been available since the late 40's, but has mainly been used in hospitals for medical diagnoses. Although this examination technique could also be used for cross sectional analyses of the jaws and implant planning, its application to maxillo-facial evaluation, including examinations for the implant treatment was limited. Later on, a special tomograph was developed only for the maxillo-facial imaging. However, the use of this techniques involved high doses of radiation especially in the full-arch examination and the method had some limitations due to artefacts.

The development of medical CT (Computed Tomography), which was originally designed as a head scanner, enabled the evaluation of maxillofacial structures in cross-sectional images. In this technique, a series of sectional images are created from a row of datasets, which can be used for multiplanar reconstruction into 2D or 3D (three dimensional) images. Improving the original CT technology, MSCT (Multi Slice Computed Tomography) has further expanded diagnostic possibilities in the medical field. Despite the excellent imaging performance of the equipment, the utility of the medical CT was limited in dentistry before the late 80's. This was due to a high cost, the fact that the scanner required a large space not available in most dental clinics, and limited access to hospital scanners. High radiation doses have also been a matter of concern especially in the machines of an early date.

In the late 1990's, CBCT (Cone Beam Computed Tomography) was introduced into the field of dento-maxillofacial imaging (Mozzo et al., 1998, Arai et al., 1999). In this technique, image datasets are acquired through a single or partial rotation of a cone-shaped X-ray beam and detectors around the region of interest. A series of 2D images obtained by the scanning are then reconstructed into both multiplanar and 3D images (Feldkamp et al. 1984) with low radiation dosage. (Schulze et al., 2004, Ludlow

and Ivanovic, 2008, Loubele et al., 2009). In addition, the lower cost and more compact device compared to medical CTs, have enabled even private practitioners to install it in their clinics.

Today, 3D image techniques are increasingly utilised for pre-operative assessments of jaws for dental implants as well as for implant planning by the aid of implant planning software.

CAD/CAM technology

CAD/CAM (Computer-Aided Design / Computer-Aided Manufacturing) systems were applied to dentistry in the 1980's to 90's (Duret and Preston, 1991, Mormann et al., 1989, Andersson et al., 1996). In this technology, digitised data of objects are transformed into a 3D construction file and the data is transferred to the milling device (Persson A, *Thesis* 2008). Thereby, the copy of the object is milled from a solid block of material such as metal or ceramic. During the first two decades, dental applications of CAD/CAM technology were limited in ceramic restorations, such as inlays and crowns. In implant dentistry, CAD/CAM technology was introduced for the production of implant abutments and frameworks in the early 1990's (Priest, 2005). The digital information of the products are usually created either by scanning a wax or acrylic resin pattern of the final design of the object, or by virtually making the final design of the object using a special software program (Kapos et al., 2009, Miyazaki et al., 2009). The digitised data is today transferred to the production plant via internet, where the computer-controlled processing machines keep manufacturing the products effectively. The product sent back to the dental laboratory is finalised by a dental technician. This technique, in combination with 3D implant planning software, allows pre-operative fabrication of implant-supported prostheses for immediate loading. CAD/CAM technology is also utilised for the fabrication of the surgical template for implant installation (van Steenberghe et al., 2005, Sanna et al., 2007, Johansson et al., 2008, Yong and Moy, 2008).

Flapless surgery

The traditional open-flap surgery frequently causes patients post-operative discomfort, such as pain, bleeding and swelling. The flap elevation causes damage in the periosteal attachment and interrupts its blood circulation flowing into the bone tissue.

Due to the recent development of diagnostic tools for evaluation of potential implant sites, such as CT and 3D implant planning software, the application of flapless procedure has become popular. It has been reported that the minimally invasive flapless implant placement significantly reduced postoperative discomfort compared to the conventional open-flap surgery. (Fortin et al., 2006, Nkenke et al., 2007, Cannizzaro et al., 2008). A high predictability of implants inserted using flapless approach has also been shown in several studies. Campello and Camara reported, in their retrospective study, that the cumulative survival rate of implants that were inserted using flapless procedure increased from 74.1% to 100 % during ten years according to a learning curve (Campello and Camara, 2002). A multicenter study that evaluated 79 implants following flapless surgery presented implant survival rate of 98.7 %, with an average of 0.8 mm marginal bone loss at 3-4 years follow-up (Becker et al., 2009). The same author also conducted histological evaluation of implants inserted without flap reflection. The study demonstrated that high bone-implant contact (mean: 54.7 %) was observed around implant placed using flapless procedure at three months, which was comparable to that around implants inserted with open-flap procedure (mean: 52.2 %) (Becker et al., 2002). On the other hand, Van de Velde et al. insisted that flapless procedure may cause complications related to a blind surgical procedure, especially in performing freehanded flapless surgery. In their *in vitro* study, 72 implants were inserted in the resin models simulating flapless surgery. Perforations due to malposition were seen in as much as 59.9 % (43/72) of the placed implants (Van de Velde et al., 2008). Recently, a combination of flapless implant surgery and implant planning software has also been reported in a number of literatures (van Steenberghe et al., 2004, van Steenberghe et al., 2005, Marchack, 2005, Sanna et al., 2007, Johansson et al., 2008).

It can be concluded that flapless implant placement may offer a favourable outcome if proper diagnosis, the meticulous planning, and careful surgery are implemented.

Computer-assisted surgery

In addition to advancements of imaging technology and CAD/CAM technique previously mentioned, the development of 3D implant planning software has led to an evolution of novel treatment concepts in dental implant treatment. CT and 3D implant software provide clinicians with 3D information of patient's bony structures. Furthermore, the combination of such image technologies and the CAD/CAM

technology allows fabrication of surgical templates and implant supported prostheses preoperatively based on the virtual treatment planning.

Today, computer-assisted surgery can be broadly divided into two types, computer-guided (static) surgery, which is evaluated in this thesis, and computer-navigated (dynamic) surgery. According to the recent consensus statements, the terms were defined as follows (Hämmerle et al., 2009):

- ***Computer-guided (static) surgery:*** The use of a static surgical template that reproduces the virtual implant position directly from CT data and does not allow for intra-operative modification of the implant position.
- ***Computer-navigated (dynamic) surgery:*** The use of a surgical navigation system that reproduces the virtual implant position directly from CT data and allows for intra-operative changes in implant position.

Computer-guided (static) surgery can be also called template-guided surgery. The concept of template-guided surgery is that the virtual implant placement planning data is transferred into the surgical field with the aid of a surgical template (= surgical guide), although the design of the surgical template and details of the protocol vary between systems. It is estimated that about 20 planning software for template-guided surgery are now available on the market (Neugebauer et al. 2010). According to a recent systematic review by Jung et al., regarding computer technology applications in implant dentistry, the number of static surgery systems commercially available is greater than that of computer-navigated systems, and today, the static guided systems are becoming a trend in dental implant treatment (Jung et al., 2009). Since a number of systems are available on the market, the general procedure of template-guided surgery is described here. Firstly, a patient and a radiographic guide are CT scanned. The data obtained from CT scan is then transferred into a 3D implant planning software, which converts the CT data into 3D reconstructions. The 3D image allows a clinician to make a diagnosis of a patient's bony structures as well as to virtually plan the implant positions. Based on the planning data, an individually customised surgical template is produced by manufacturers using either rapid prototyping or computer-driven drilling. The surgical templates can be categorised according to the supporting form, such as bone-, tooth- and mucosal-supported templates. Flapless surgical technique is feasible in cases in which tooth- and mucosal-supported surgical templates are applied. Some systems allow even for immediate loading of implants by providing a provisional or a

definitive implant supported prosthesis that is pre-operatively created from the digital planning data using CAD/CAM technique.

In the computer navigated surgery, the sensors attached to both the patient and the handpiece enable the surgeon to visualise the actual position of the intraoral surgical instruments on a 3D reconstructed image of the patient that is displayed on a monitor in the operating room. Although the applicability of the system has been presented in several articles (Siessegger et al., 2001, Ewers et al., 2004), high purchase price, maintenance cost and the size of the equipment seem to remain challenges for the future.

ASSESSMENTS OF COMPUTER-GUIDED IMPLANT TREATMENT

Clinical assessments

Clinical outcome of template-guided implant surgery; survival rate and complications

It has been reported in several studies that template-guided surgery based on computer-assisted virtual treatment planning can offer acceptable outcomes (van Steenberghe et al., 2005, Sanna et al., 2007, Malo et al., 2007, Johansson et al., 2008, Yong and Moy, 2008). The overall implant survival rate in these studies ranged 88.4 % to 100 %. However, in specific groups, e.g. smokers (81.2 %) (Sanna et al. 2007), the implant survival rate was rather low.

In these studies, prefabricated provisional or final prostheses were attached onto the implants immediately after surgery. The overall prosthetic survival rate was between 84 % and 100 %. Substantial long-term data is lacking with only a few studies having a mean follow-up period of more than two years (Sanna et al. 2007, Yong & Moy 2008).

The technical and biological complications could result in loss of implants or prostheses in the worst case. However, studies reporting such complications occurring during the implant treatment and follow-up are still limited, although implant losses are frequently described (Berglundh et al., 2002). Complications observed during the computer-assisted template-guided surgery have been reported in few studies and reviews (van Steenberghe et al. 2005, Johansson et al. 2008, Yong and Moy 2008, Schneider et al. 2009, Jung et al. 2009, D'haese et al. *in-press*). Complications could occur at any time in the treatment, during surgery, at prosthesis connection and in a follow-up period. In computer-assisted surgery, the problems are occasionally due to

the product rather than the technique. An example of these problems might be the accuracy and stiffness of the components, surgical templates and suprastructures. Misplacement or misfit of surgical templates, limited access of surgical tools, encounter with unexpected bone structures are examples of the complications observed during surgery. As for early prosthesis-related problems, misfit between the installed implants and the prefabricated prosthesis is a commonly observed complication, while the fracture of the prosthesis was frequently reported as a late prosthetic complication. It is reported in the systematic review by Schneider et al. that the surgical complications were observed in 9.1 %, early prosthetic complications in 18.8 % and late prosthetic complications in 12 % of the patients (Schneider et al. 2009).

Marginal bone loss

Intraoral and panoramic radiographs have been routinely applied to evaluate the marginal bone level around implants. Although the measurements are, in most situations, limited at the mesial and distal surfaces, such radiographic examination is regarded as a practical method to detect a longitudinal transition of the marginal bone level around implants (Pikner et al., 2009).

The bone loss during the first year in function has been regarded as a result from bone remodelling, adaptation, surgical trauma, and/or loading (Adell et al., 1986). Recent studies presented an additional finding, namely that a large amount of bone loss occurred already during the early healing period, before loading when implants were loaded after conventional healing period (Åstrand et al., 2004, Cochran et al., 2009). These reports showed that the bone loss between implant insertion and the time of loading was significantly larger than the bone loss that occurred between loading and the 5-year follow-up. After the first year of function, the marginal bone around implants generally appears stable and marginal bone changes are small (Ekelund et al., 2003, Åstrand et al., 2008, Åstrand et al., 2004). The major factors that cause peri-implant osseous destruction in this initial phase of osseointegration are considered to be poor bone quality and/or inappropriate surgical techniques such as overheating of bone, or implant surface contamination (Mouhyi et al., 2009).

On the other hand, ongoing marginal bone loss around functional implants can jeopardise the implants' success and survival. An inflammatory reaction accompanied by a continuous marginal bone loss of the supporting bone is called peri-implantitis. The origin of bone destructions can be lesions of the peri-implant attachment, presence of aggressive bacterial strains, excessive mechanical stress, and corrosion. Regardless

of what the triggering factor may be, a chain reaction of these factors can lead to progressive osseous destruction, which may eventually bring about loss of implants (Mouhyi et al. 2009).

The marginal bone changes following computer-assisted template-based surgery have been investigated in few studies. Sanna and co-workers reported that the mean marginal bone loss after four years following the template-based surgery in combination with immediate loading was 1.3 mm in non-smoking patients while it was 2.6 mm in smoking patients (Sanna et al., 2007). Malo et al. assessed marginal bone loss in edentulous jaws that had been treated using the same technique (Malo et al., 2007). They reported that the mean marginal bone loss examined at the one year follow-up was 2.0 mm in the maxilla and 1.7 mm in the mandible, but 28 % of the measured implants presented more than 2 mm of bone loss. This higher frequency of measurements of more than 2 mm of marginal bone loss, compared to that of the standard flap surgery, has been also reported by Johansson et al. In their study more than 19 % of the measured sites showed this higher degree of marginal bone loss at the one-year follow-up (Johansson et al., 2008). The mean marginal bone loss around the maxillary implants was, from implant insertion to the one-year follow-up, 1.3 mm in their study. At the moment, long-term data including a sufficient number of implants is lacking.

Clinical inflammation

Bleeding on probing (BoP) is used as a meaningful parameter to detect presence of mucosal inflammation around implants if a proper probing force is applied (Lang et al., 1994, Schou et al., 2002). It has been shown that absence of BoP is strongly associated with stable and healthy peri-implant conditions in animal and human studies (Jepsen et al., 1996, Luterbacher et al., 2000). Gentle probing force of approximately 0.25 N is generally recommended for assessing peri-implant tissue conditions. It has also been demonstrated that probing using a force of 0.25 N does not deteriorate the peri-implant tissue, and the mucosal seal was reformed five days after probing (Etter et al., 2002). On the other hand, a recent study by Gerber et al. reported that a probing pressure of 0.15 N may be a proper threshold to be applied to avoid false positive BoP readings around implants (Gerber et al., 2009). The study concluded that probing around implants demonstrate a higher sensitivity compared with probing around teeth.

Probing depth

One of the parameters frequently used in combination with BoP, to assess the peri-implant mucosal status is PD (Probing Depth). Several studies have shown that probe tip penetration around teeth and implants are similar under healthy mucosal conditions if gentle probing forces (0.2-0.3 N) are applied. However, in the presence of inflammation, deeper probe penetration was observed around implants than around teeth. (Lang et al., 1994, Abrahamsson and Soldini, 2006, Schou et al., 2002). Mombelli et al. found that peri-implant probing depth measurements are more sensitive to force variation than periodontal pocket probing (Mombelli et al., 1997). Therefore application of a force-controlled calibrated probe may be one option for a proper examination.

Correlations between peri-implant PD or PAL (Probing Attachment Level) and radiographic marginal bone level have been reported by several studies (Quirynen et al., 1991, Bragger et al., 1996, Hultin et al., 2002, Karoussis et al., 2004, Fransson et al., 2008). Other studies have stated that increased pocket depth could be associated with inflammation of peri-implant mucosa (Quirynen et al., 1991, Pontoriero et al., 1994). These results imply that measuring the probing depth around implants could be a good predictor of peri-implant bone loss when it is evaluated in combination with radiographic parameters. It is essential to measure PD regularly for long-term clinical monitoring of peri-implant mucosal tissue (Lang et al., 2000).

Oral hygiene

Plaque formation develops in a similar manner on both teeth and implants. It has also been observed that the peri-implant tissue response to plaque follows similar patterns to that of the periodontal tissue (Berglundh et al., 1992, Ericsson et al., 1992, Leonhardt et al., 1992, Pontoriero et al., 1994, Zitzmann et al., 2001).

Several studies have shown an association between oral hygiene and peri-implant tissue condition. Lindquist et al. showed in a ten-year prospective study that poor oral hygiene had an influence on marginal implant bone loss, especially in smokers (Lindquist et al., 1997). Ferreira et al. found that the association between plaque scores and peri-implant disease was dose dependent. In their study, subjects who had a higher plaque index showed a worse peri-implant condition (Ferreira et al., 2006). Another study demonstrated a relation between accessibility for oral hygiene at implant sites and peri-implantitis. The study concluded that a high proportion of implants diagnosed with peri-implantitis were associated with no accessibility for appropriate

oral hygiene measures, while accessibility was rarely associated with peri-implantitis (Serino and Ström, 2009). An association between oral hygiene and implant failures was also reported in a prospected multi-centre study in partially edentulous patients. The CSR (Cumulative Survival Rate) of implants after three years was 93.9 %. According to their data, failures appeared to be concentrated in patients with a high plaque score (van Steenberghe et al., 1993).

Implant stability

Bone quality/quantity at implant sites is one of the important factors to achieve high primary implant stability. The most commonly used classification of bone tissue is the one established by Lekholm and Zarb (Lekholm and Zarb 1985). This classification is based on pre-operative radiographic evaluation and drilling at implant site preparation. In several studies, higher implant failure rates have been reported in the soft bone, class 4 quality in the classification mentioned above, compared to those in the dense bone (Friberg et al., 1991, Jaffin and Berman, 1991). The bone quality/quantity has been regarded as a key factor especially in the cases of immediate loading (Glauser et al., 2001). However, this author later reported that the immediate loading protocol, in combination with a slightly tapered implant and a modified implant surface structure could achieve good initial stability, and therefore it can be a successful treatment alternative in regions exhibiting soft bone (Glauser et al., 2005). Besides the bone quality/quantity and macro/micro design of implants, surgical technique is also one of the factors that influences the primary stability. Östman et al. showed that the immediately loaded implants inserted in less dense bone could result in a favourable outcome, when a modified drill protocol was applied according to the varying bone quality of each implant site (Östman et al., 2005). It has been emphasised that the individual implant should be quickly splinted after implant placement with a rigid connection in order to prevent unfavourable micromotions in the case of immediate loading (Östman, 2008).

The frequently used method recently for monitoring degree of the implant stability is RFA (Resonance Frequency Analysis) introduced by Meredith and his co-workers (Meredith et al., 1996). This technique measures the first resonance frequency (RF) of a transducer attached onto an implant or an abutment. The RF is mainly dependent on the stiffness of the implant-tissue interface and the effective length above the marginal bone level. The RF value obtained from the transducer is

then automatically converted into an ISQ (Implant Stability Quotient) value by the instrument. The ISQ value, which runs from 1-100, reflects the degree of stability. Several experimental and clinical studies have presented the predictability of this method (Meredith et al., 1997, Friberg et al., 1999, Sennerby et al., 2005). This technique can be applied to objectively detect changes of implant stability as well as alteration in the level of bone-implant contact. Currently, two different types of the device are commercially available, Ostell™ (transducer with a cable) and Ostell Mentor™ (wireless type) (Integration Diagnostics AB, Gothenburg, Sweden).

Accuracy of template-guided implant placement

Although the surgical template allows accurate translation of the treatment plan to the surgical field in theory, the data concerning to what extent deviations occur between virtually planned implant positions and the placed implant positions are still limited especially in a clinical setting. The overall deviation is a sum of small errors that arise in each step during the whole treatment procedure (Figure 2) (Kero et al. 2007, 2008). It is rather difficult to detect deviations that possibly occur in each step. The analyses of accuracy are, however, of great interest to avoid severe injury of significant anatomical structures, interference between implants, and a misfit of an implant-supported bridge if it is a case of immediate loading of a prefabricated suprastructure. The most commonly used method in assessment of the accuracy is to compare the pre-operative planning data with the post-operative CT data. In this technique, it is required to re-CT scan the patient after implant insertion.

The literatures reporting accuracy of template guided surgery have been reviewed and analysed by some researchers (Jung et al., 2009, Schneider et al., 2009). Schneider et al. analysed the accuracy of template-guided surgery, comparing the mean accuracy between different groups. Their review included one model study, four cadaver studies and three studies in humans. The overall mean error was 1.07 mm (maximum: 4.7 mm) at the hex and 1.63 mm (maximum: 7.1 mm) at the apex. Mean deviation in angulations was 5.26 degrees (maximum: 21 degrees). If only looking at human studies, which include also zygoma and pterygoid implants, the deviation at the hex was 1.16 mm (maximum: 4.7 mm), at the apex was 1.96 mm (maximum: 7.1 mm) and 4.90 degrees (max: 21 degrees) in angulation. No statistically significant difference was detected in errors between studies in humans, cadavers and models. There was no difference in deviation among the bone-, tooth- and the mucosal-supported surgical guide in the review, although the deviation in bone-supported surgical template was

significantly smaller when those three types of templates were compared in one study (Ozan et al., 2009). Similar deviation values were presented in a recent review by D'haese et al (D'haese et al. *in-press*). In their report, the mean deviations in clinical studies (except studies using zygoma and pterygoid implants) were 1.04 mm (range: 0.2-1.45 mm) at the implant hex, 1.64 mm (range: 0.95-2.99 mm) at the implant apex. Mean angular deviation was 3.54 degrees (range: 0.17-7.9 degrees).

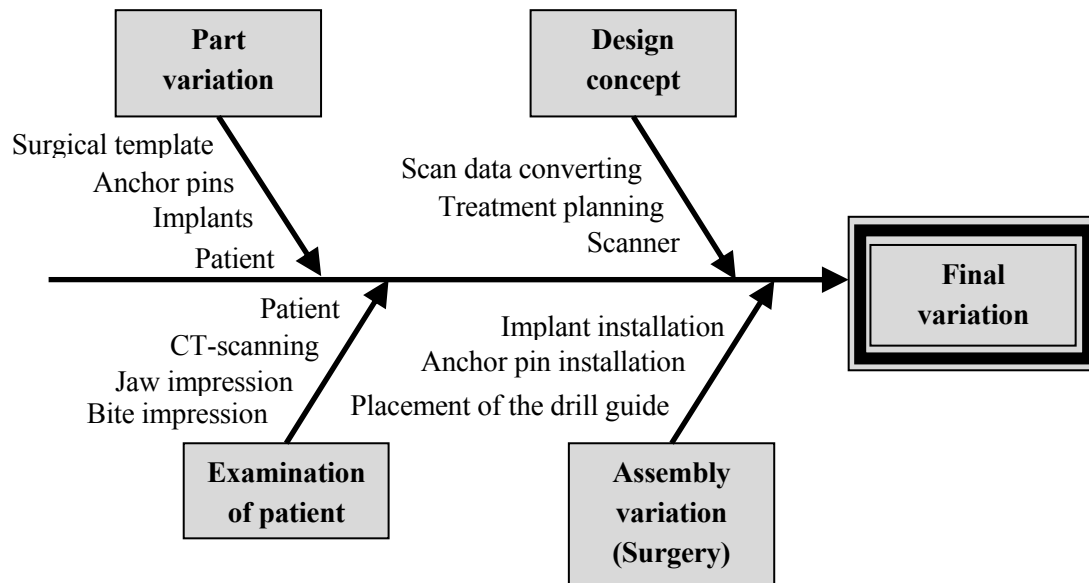


Figure 2. Cause and effect diagram for accuracy of computer-guided implant surgery (Kero et al. 2007, 2008)

Patient-centered assessments

Over the last decades, the focus of implant research has been shifted from whether dental implants function as a treatment option of missing teeth, to more specific issues, such as implant design and surface morphology, novel biomaterials, and advanced techniques etc. These studies have made great contributions to the development of a variety of implant products and techniques. Treatment outcomes of the new systems are generally presented using success and /or survival rate, which are evaluated from biological aspects based on various objective clinical parameters. On the other hand, patients' opinions about the treatment outcomes have scarcely been reported. According to Pjetursson et al., the patient-centered outcomes have been

presented in less than 2 % of the available publications that deal with dental implant in humans (Pjetursson et al., 2005). Although the amount of literature is limited, the available literature has shown that the dental implant treatment remarkably improved patients' oral functions and satisfaction. (Albrektsson et al., 1987, de Bruyn et al., 1997, Sandberg et al., 2000, Pjetursson et al., 2005).

Recently methods using immediate or early loading have become increasingly common. These methods may further enhance the patient's satisfaction and function during the healing period, if the patients are good candidates and properly treated. Dierens and co-workers recently presented patient-centred outcomes of immediately loaded implants in the rehabilitation of edentate jaws (Dierens et al., 2009). Their study showed that overall comfort, function and aesthetics significantly improved within one week of implant insertion with provisional restoration, something that is not achievable in the conventional two-stage surgical procedures. Computer-guided surgery also has great potential in terms of offering patients several benefits. Fortin et al. presented that patients who had been treated using computer-guided flapless surgery had less post-operative discomfort compared to patients treated with an open-flap method (Fortin et al., 2006). In another study, patients' opinions regarding speech, oral function, aesthetics and tactile sensation were evaluated after three months following template-based surgery in combination with immediate loading of a prefabricated prosthesis (van Steenberghe et al., 2005). Although these studies report that the patients' opinions on computer-guided surgery are positive, the data is limited. Therefore further research is necessary to evaluate if this new concept can offer patients results that are comparable to conventional methods, as well as a better experience from the patient's point of view.

Appendix: Table 1. Summary of studies on computer-assisted template-based implant placement in combination with a immediate loading of a prefabricated prosthesis

Reference	Subjects (No. of cases)	No. of implants	Follow-up period	Implant survival rate	Prosthetic Survival rate
van Steenberghe et al. 2005	Full Max (24)	164	1 yr	100 %	100 %
Malo et al. 2007	Full Max (18) Full Mand (5)	92	Mean: 13 mon (6 - 21 mon)	Max+Mand:97.8 % Max: 97.2 % Mand: 100 %	100 %
Sanna et al. 2007	Full Max (26) Full Mand (4)	212	Mean: 2.2 yr (up to 5 yr)	Non-smoker (17): 98.9% Smoker (13): 81.2 %	NR
Balshi et al. 2008	Full Max/Mand (23)	168	3 mon – 3 yr	97.6 %	100 %
Komiyama et al. 2008	Full Max (21) Full Mand (10)	176	Mean:19.6 mon (6 - 44 mon)	Max: 92 % Mand: 84 %	Max: 90 % Mand: 70 %
Yong & Moy 2008	Full Max (7) Full Mand (4) Part Max (2) Part Mand (1)	78	Mean: 26 mon	91 %	NR
Johansson et al. 2009	Full Max (52)	312	1 yr	99.4 %	96.2 %

Full Max: Fully edentulous maxilla, Full Mand: Fully edentulous mandible, Part Max: Partially edentulous maxilla, Part Mand: Partially edentulous mandible

AIMS

GENERAL AIM

The general aim of this thesis was to evaluate computer-assisted virtual treatment planning and template-guided surgery in dental implant treatment.

SPECIFIC AIMS OF STUDIES

Study I:

To evaluate the outcome of immediately loaded implants inserted in edentulous jaws following computer-assisted virtual treatment planning combined with flapless surgery

Study II:

To evaluate soft tissue conditions and marginal bone changes after 1 year of function around immediately loaded implants inserted in edentulous jaws following computer-assisted treatment planning and flapless surgery

Study III:

To verify if any variation exists between virtually planned implant positions and clinically placed implant positions by matching pre-operative planning data and post-operative CT data

Study IV:

To assess the deviation between virtually planned implant positions and clinically placed implant positions using an impression model matching method

To investigate whether there is any statistically significant difference in the deviation between the virtually planned implant positions and clinically placed implant positions compared to the results from *Study III*

MATERIAL AND METHODS

SUBJECTS

Study I

Study I included 29 patients with 31 edentulous jaws (21 maxillae and 10 mandibles), consecutively treated using the NobelGuide™ and Teeth-in-an-Hour™ (Nobel Biocare AB, Gothenburg, Sweden) between September 2003 and November 2006. In two patients, both maxilla and mandible were treated. The patients consisted of 9 females and 20 males. The mean age of the patients was 71.5 years with a range of 42-90 years. In total, 176 Brånemark System® MkIII TiUnite™ implants (Nobel Biocare AB) were installed, 124 implants in the maxilla and 52 implants in the mandible. All the patients were referred from their general dentists for treatment with implant-supported reconstructions.

Study II

After *Study I* was conducted, 3 additional mandibles were treated using the same procedure as *Study I*. In total, 30 patients including 34 jaws (21 maxillae and 13 mandibles) were consecutively treated between September 2003 and May 2007. Between implant insertion and ≥ 1 -year clinical examination, 5 out of 34 treated cases (number of cases = number of jaws) were lost to follow-up, due to implants' losses (4 cases), or misfit of bridge-implant (1 case), which resulted in disconnection of the suprastructure. Eventually, 26 patients including 29 edentulous jaws (19 maxillae and 10 mandibles) underwent the ≥ 1 -year follow-up. A total of 165 implants were examined in this study. Mean age of the 26 patients, 16 males and 10 females, at re-evaluation was 71.9 years with a range of 44-92 years. Two of the 26 patients (3 cases) were smokers.

Study III and Study IV

The data used for *Study III* and *Study IV* were also collected at the day of the ≥ 1 -year follow-up in *Study II*. Of the 29 cases included in *Study II*, 5 cases did not undergo further detailed examinations for *Study III* and *IV* due to poor health conditions (3 cases) and withdrawal by patients (2 cases). One case that was excluded from *Study II* because of misfit of bridge-implant which led to delayed loading, was included in *Study III* and *IV*. As a results, 25 jaws (15 maxillae and 10 mandibles) treated with 139

implants (89 in maxilla, 50 in mandible) were included in *Study III* and *IV*. Mean age of the patients at the time of re-evaluation was 72.1 years old (range: 44-92 years).

Ethical Considerations

This research project was approved by the Ethics Committee at the Karolinska University Hospital, Huddinge, Sweden (Dnr. 278/03) and the Swedish Radiation Safety Authority. All patients were informed of the study protocol and signed an informed consent.

METHODS

The patients included in this project were all treated by means of NobelGuide™ and Teeth-in-an-Hour™. All the patients were treated by the same surgeon (BK) and have been followed up at the Division of Periodontology, Department of Dental Medicine, Karolinska Institutet. According to the manufacturer, these systems are defined as follows:

NobelGuide™: Cases where a surgical template, based on model- or computer-based planning, is used to guide the clinician during surgery.

Teeth-in-an-Hour™: The screw retained, permanent prosthesis is attached in the same surgery session.

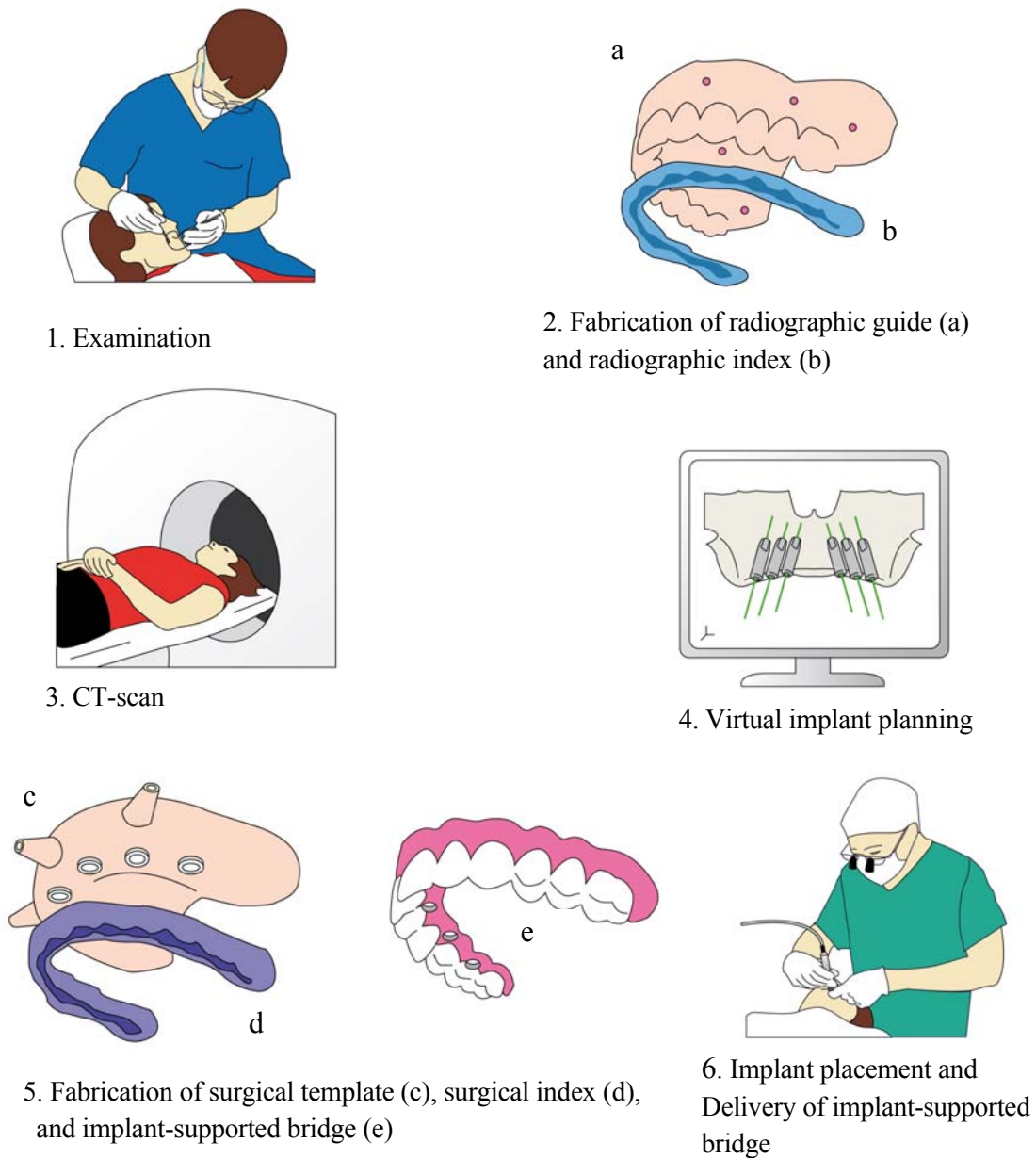


Figure 3. Working flow of NobelGuide™ and Teeth-in-an-Hour™

©Lina Odhe

Treatment protocol

1. Patient examination

Before treatment, patients underwent clinical and radiographic examinations.

To be included in the present study, patients must

- fulfill general health requirements for conventional implant treatments
- be able to open the mouth at least 50 mm (between the residual ridge and the incisal edge of the opposing anterior dentition)
- present sufficient bone volume for the installation of a minimum of 5 implants

2. Pre-surgical treatment

Patient's denture was evaluated regarding occlusion, teeth alignment and fitting to mucosa. The denture or its replica should be made of acrylic resin with non-radio-opaque properties since it is used as a radiographic guide during CT scan. If the denture was ideal, a minimum of 6 spherical gutta-percha markers (diameter of 1-1.5 mm and depth of 0.5 mm) were placed into the surface of the denture/replica. An occlusal index was taken to stabilise the radiographic guide. A study cast of the opposing jaw was also prepared.

3. CT-scan

All patients were scanned using a cone beam CT (NewTom QR-DVT 9000; QR s.r.l, Verona, Italy). The scan setting used was between 4 and 6 mAs and 110 KV with 0.3 mm in voxel size. The reconstructed slice thickness was 0.3 mm. The CT-scan was performed in two steps. The first scan was made of the patient wearing the radiographic guide together with the occlusal index. In the second scan, the radiographic guide was separately scanned. The data of axial reconstructed slices were exported in DICOM (Digital Imaging and Communications in Medicine) file format.

4. Surgical planning

The DICOM data was transferred into the Procera® Software (Procera Software version 1.5 build 75; Nobel Biocare AB) and converted into 3D images. The scanning data of the patients and the data of the radiographic guide were matched with the aid of the gutta-percha markers. All surgical planning was made by two clinicians (BK/MH) in the virtual 3D image on the computer screen. The planning data was then sent to a production plant.

5. Fabrication of surgical template and implant-supported bridge

Based on the planning data, a surgical template was manufactured using stereolithography. The surgical template contains horizontal guided sleeves for placement of anchor pins and guided sleeves for implant insertion. To create a master model, implant replicas were mounted to the guided sleeves using guided cylinders with pins, and anchor pins were inserted into anchor pin sleeves. Soft-tissue substitute material was then poured around the guided cylinders by using a small injection syringe. After the soft tissue replica had set, plaster was poured over the mimic soft-tissue. All the guided cylinders with pins and anchor pins were removed upon the setting of the plaster, and the plaster model was detached from the surgical template. In order to stabilise the surgical template during surgery, a surgical index that recorded the relation between the surgical template and the opposing jaw was made on the patient's stone model in an articulator. On the plaster model, a resin replica of an implant bridge frame was made by a dental technician. The resin pattern was to be replaced by CAD/CAM based Procera® implant bridge. The bridge was finalised by a dental technician prior to implant surgery.

6. Implant insertion and delivery of implant-supported prosthesis

The patient was medicated with Diazepam 5-10 mg prior to surgery. All surgeries were performed under local anaesthesia. No prophylactic antibiotic was used. The surgical template was positioned over the alveolar ridge using the surgical index while occluding. When the surgical template was in the correct position, a Ø1.5 mm twist drill was used to drill a hole into the soft tissue and the bone, through the horizontal guided sleeves in the surgical template. The surgical template was then stabilised by means of 3 to 4 anchor pins (Guided Anchor Pin 1.5 mm) inserted in the horizontal guided sleeves. To obtain further vertical stability, preparation was first started for two implants in the middle of each half of the arch. A start drill (Guided Start Drill / Counterbore), which functions as a combined tissue punch and a countersinking drill, was used at the start of the preparation. The drilling protocol for the implant placement included twist drills with diameters of 2.0, 2.8, and 3.0 mm (Guided Twist Drill). These drills were directed with the aid of drill guides (Guided Drill Guide), whose diameter correspond to the diameter of each drill. If the bone was dense, a Ø3.2 mm twist drill and a screw tap were complementarily used to avoid over-compression. The first two implants were then inserted through the guide sleeve using an implant mount (Guided Implant Mount). Once these two implants were

placed in position, a template-abutment, which applies vertical compression onto the surgical template, was attached to each implant platform. All remaining implants were inserted in sequence using the same procedure. After all implants had been inserted, the surgical template was removed. If necessary, excess gingival tissue was trimmed. A prefabricated implant-supported prosthesis, including specially designed expandable abutments, was connected onto the implants immediately after implant insertion. A post-operative panoramic radiograph and intraoral radiographs (in some cases) were taken to ascertain proper seating of abutments onto the implant platforms. Once it was confirmed, abutment screws were tightened to 35 Ncm and occlusal adjustments were made. Screw holes were filled with temporary restorative material (Fermit; Ivoclar Vivadent AG, Schaan, Liechtenstein).

7. Post-operative care

Patients were instructed to use chlorhexidine rinse (Corsodyl®, SmithKline Beecham plc, Middlesex, UK) twice a day for 1-2 weeks after surgery. Patients were also asked to consume a soft diet during the first post-operative week. All patients had follow-up examinations at 1 day, 1 week, 3, 6, and 12 months after surgery. After 12 months, patients were routinely recalled for annual check-up. At the 1-week follow-up, patients were individually instructed to start brushing with a soft toothbrush (TePe Gentle Care™, TePe Munhygienprodukter AB, Malmö, Sweden). Patients received oral hygiene instruction and self-performed plaque control by a dental hygienist within two weeks of surgery. The oral hygiene instruction included individual guidelines and training in the use of a soft toothbrush, interdental brushes and dental floss. At the 1-month follow-up, the temporary fillings of the screw holes were replaced to composite resin unless the patient had unfavourable occlusion.

Protocol of ≥ 1 -year follow-up

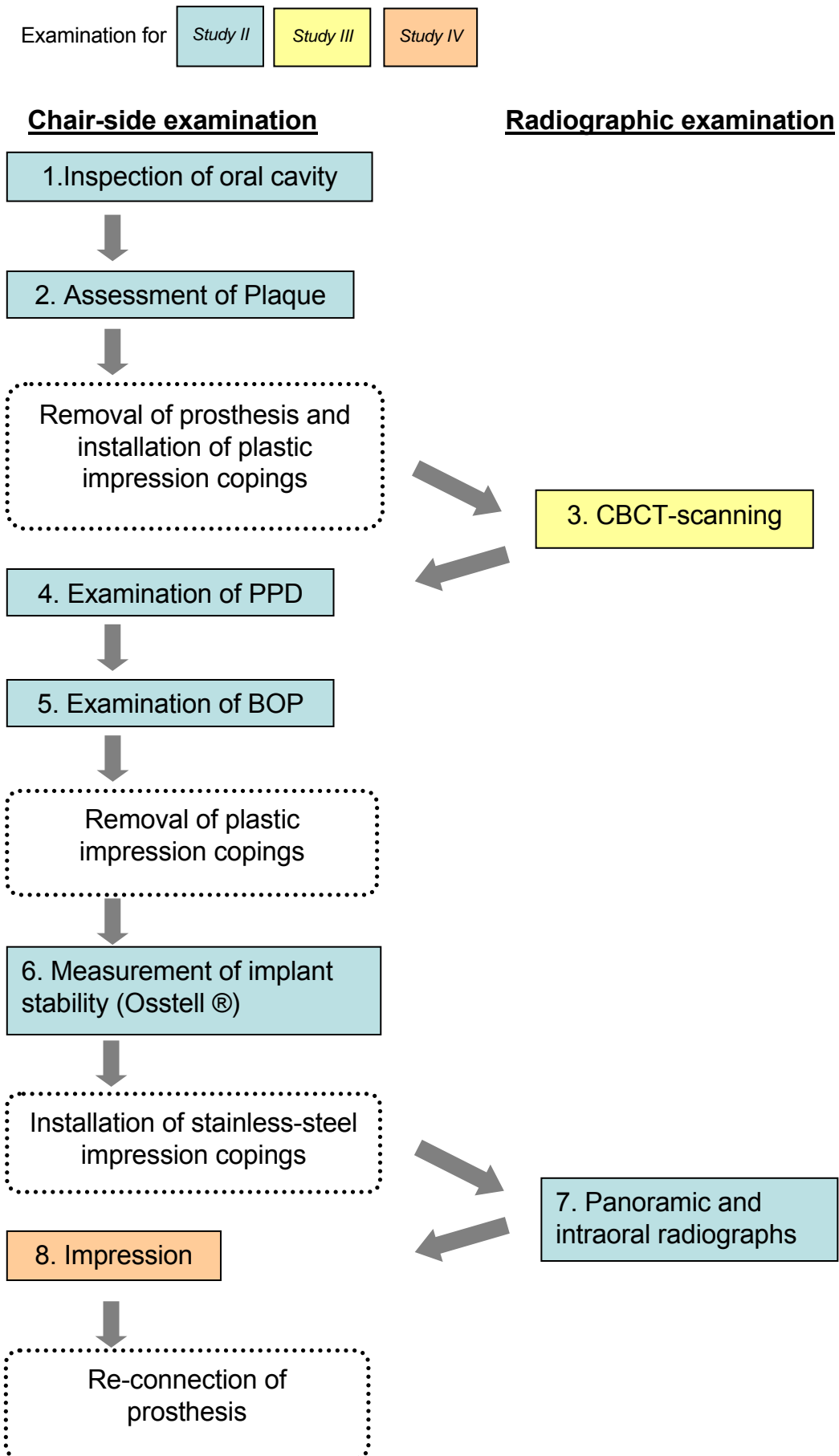


Figure 4. Protocol of ≥ 1 -year follow-up

Clinical examination

Study I

Treatment outcome; Survival rate and complications

In *Study I*, survival rate was calculated both at implant level and at prosthesis level. Any complications occurring during implant insertion and prosthesis connection, as well as adverse events observed during the follow-up period were also recorded.

Study II

Plaque

Before removal of the suprastructure, including abutments, visible plaque around implants/abutments was assessed at four sites, buccal, lingual, mesial and distal, by scoring in a binominal fashion (0 = no plaque, 1 = plaque). The percentage of implant/abutment surfaces with plaque was calculated.

Probing depth

The suprastructure was removed after plaque assessment. Upon removal, specially designed plastic impression copings were temporarily attached to individual implants to prevent collapse of the peri-implant soft tissue (Figure 5). To easily probe the soft tissue, the cylinder of the plastic impression coping was slightly modified by the manufacturer to be straight and narrow, in line with the exterior wall of the implant collar. The distance from the peri-implant mucosal margin to the bottom of the peri-implant sulcus was measured at six sites (distobuccal, midbuccal, mesiobuccal, mesiolingual, midlingual, and distolingual) around each implant using a force-controlled calibrated periodontal probe (Florida Probe®, Florida Probe Corporation, Gainesville, FL, USA). The probing pressure was 15 g and a diameter of the titanium probe-tip was 0.45 mm.

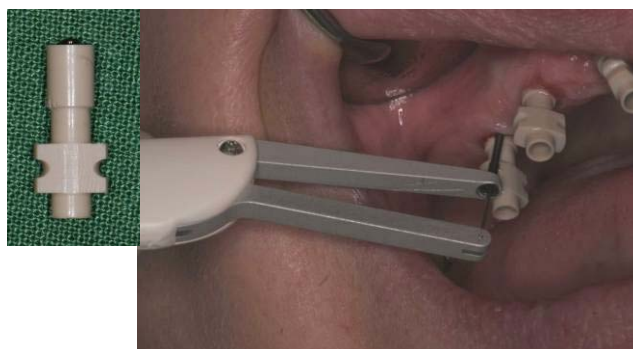

Figure 5. Plastic impression copings attached to implants

Clinical inflammation

Clinical inflammation was assessed according to Gingival Bleeding Index (Ainamo and Bay, 1975), which scored a presence of bleeding after gentle probing (BoP: Bleeding on Probing). The score was registered either 0 (no bleeding) or 1 (bleeding) and the percentage of bleeding sites were calculated.

Implant stability

After the assessments of PD and PPD, the plastic impression copings were removed. The stability of each implant was measured by RFA (Resonance Frequency Analysis) using an Ostell™ device (Integration Diagnosis AB, Sävedalen, Sweden). ISQ (Implant Stability Quotient) of individual implants was recorded. In 12 of the 29 cases, ISQ had been measured immediately after implant insertion as well, and in these cases the ISQ were compared to the ISQ obtained at the ≥ 1 -year follow-up.

Radiographic examination

Study II

A panoramic radiograph (Scanora® dental program, magnification 1.7; Soredex, Orion Corporation, Helsinki, Finland) was taken the day of surgery and prosthesis connection to confirm if abutments were seated properly onto the implant platform in all cases. In addition to the panoramic radiograph, complementary intraoral radiographs (Focus™, Instrumentarium, Tuusula, Finland) were taken using a long-cone paralleling technique in 13 cases. At the ≥ 1 -year follow-up, a panoramic radiograph, as well as intraoral radiographs was taken in all cases using the same devices with the same settings.

Evaluation of marginal bone changes

Panoramic Radiograph

All panoramic radiograph measurements were performed at the radiographs taken immediately after prosthesis connection and at the ≥ 1 -year follow-up by two calibrated readers (AK and DB). The measurements were made at the mesial and distal implant surfaces, and repeated twice. In these measurements, the peak of the most coronal thread of the implant was used as a reference point for the assessment of marginal bone level (Figure 6). The marginal bone level was assessed by counting the number of fixture threads from the reference point to the first clear bone to implant contact. If the marginal bone appeared at a more coronal level to the first thread, the

marginal bone level was recorded as “0”, regardless of the distance between the reference point and the marginal bone crest. The number of threads was rounded to 0.5. Marginal bone changes were evaluated by comparing the number of threads from the time of the prosthetic connection to the number of threads taken at ≥ 1 -year follow-up.

Intraoral Radiograph

In the assessment of intraoral radiographs, marginal bone height was presented as the distance between the reference point (Thread 1) and the marginal bone crest (Figure 6). When more than one bone margin was observed, the most apical margin was used for calculation. Only the radiographs perpendicular to the implant were included in the evaluation. The measurements were made at the mesial and distal surfaces by two calibrated readers (AK and DB). A magnifying lens with 0.1 mm scales (PEAK Scale Lupe x7, Tokai Sangyo, Tokyo, Japan) was used for the measurements. Each observer repeated the readings twice, allowing an interval of at least 2 weeks between the readings.

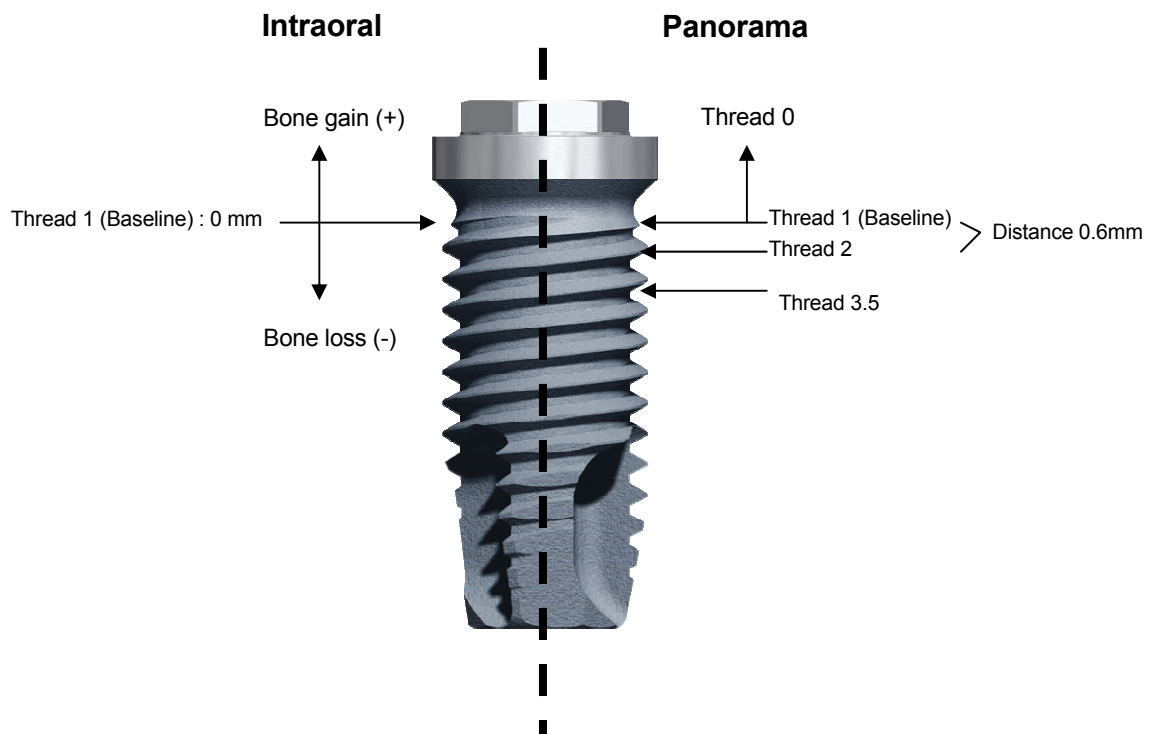


Figure 6. Reference points used in panoramic and intraoral radiograph measurement

Evaluation of accuracy

Study III

CT matching

Patients were re-CT scanned at the ≥ 1 -year follow-up. Suprastructures including abutments were removed prior to the scanning to prevent artifacts from metal. Plastic impression copings were temporarily attached to the individual implant to avoid collapse of the peri-implant soft tissue, as described in the protocol of ≥ 1 -year follow-up. The preoperative CT data was matched to the post-operative CT data using a 3D voxel-based registration (Maes et al., 1997). The post-operative data were registered to the pre-operative data by calculating mutual information between the corresponding voxels in the two datasets and into one coordinate system. A voxel-based matching software (NobelGuide Validation 2.0.0.4, Nobel Biocare AB) searched for corresponding grey values in the two datasets and aligned them together. After the implants from the post-operative scan were segmented from the dataset, the position and orientation of clinically placed implants were compared with those of virtually planned implants using a coordinate system that was obtained from the voxel-based matching. Three-dimensional linear and angular deviations between the actually placed implant positions and virtually planned implant positions were analysed. The Euclidean distance between the clinically placed and virtually planned implant was measured at the centre of the apex and the hex of the implant. In addition, angular discrepancies between the main axes of the clinically placed and virtually planned implants were calculated. The results were expressed as distance deviations at the apex, hex, the depth difference, and the angular deviations (Figure 7).

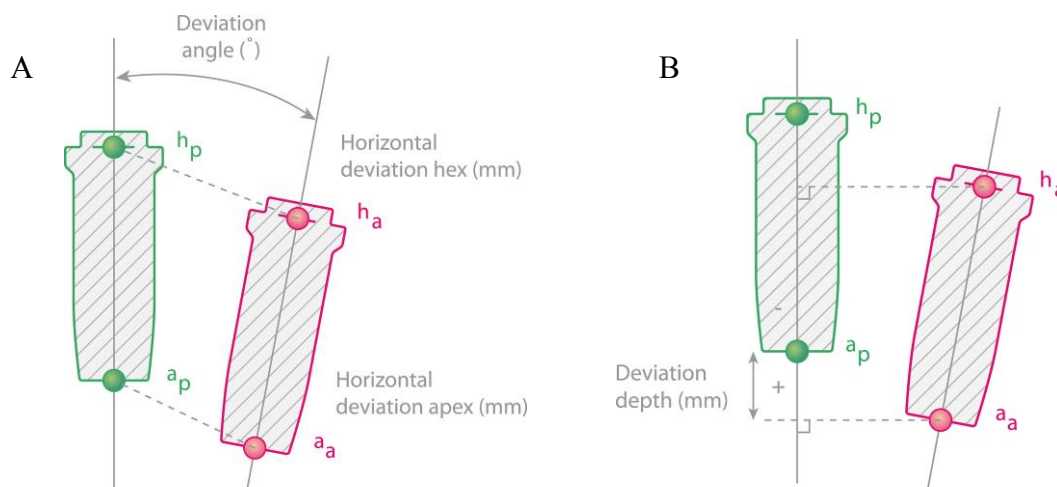


Figure 7. A, Illustrating the measurement deviation calculation at the level of the hex, apex, and angular deviation. B, Represents the measurement deviation calculation of the depth between the virtually planned implant and implant placed after surgery. (aa = apex actual; ap = apex planned, ha = hex actual; hp = hex planned)

Study IV

Impression model matching

The plaster models containing the implant replicas, one created from the surgical template pre-operatively and the other created from the patients impression at the ≥ 1 -year follow-up, were scanned with a measuring device (Zeiss Prismo 5 Vast, Carl Zeiss, Oberkochen, Germany). The coordinates obtained from the scanning represented the centre of each implant platform. The coordinates were then saved in a text file and imported to CAD software (Procera System Build: 264 Version: 2.2 Procera CADDDesign version 2.2.20 (Build 313). Nobel Biocare AB). Based on the coordinates, cylinders were created with corresponding length and diameters for each implant. STL (Stereolithography) triangle based surface objects were then constructed and linked to each corresponding coordinate point in the pre- and the post-operative data set. After the STL files were linked, they were merged together into one object and exported as one STL file for the pre- and the post-operative dataset. The pre- and post-operative STL files containing the corresponding implants in position were matched using the best fit alignment in CopyCAD (CopyCAD 8.080 SP2, Delcam Plc, UK). The matched STL files were then exported. The linear measurements of the two matched objects were performed at the centre of the hex and the apex using virtual variation simulation software (RD&T; RD&T Technology AB, Mölndal, Sweden). The results obtained in the present study were also compared to the results of *Study III*.

Statistical analyses

All statistical analyses were conducted using Statistica 7 (Statsoft, Inc.Tulsa, US).

In *Study II*, data from all measured sites were transformed to individual jaw means when analysed at case level. The Mann-Whitney *U* test was used to calculate differences at case level, but also employed at implant level, when data were compared between individual jaws. A probability of less than 0.05 was regarded as statistically significant. To investigate the variation in marginal bone changes during functional loading, as evaluated on intraoral radiographs, the cut-off levels of 1.0 mm, 1.5 mm, and 2.0 mm marginal bone loss were chosen. A ROC curve (Receiver operating characteristic curve) was made in order to evaluate the validity of chosen cut-off values. In cases with pressure-like-ulcers, the sensitivity and specificity were higher when the cut-off levels were set to 1.5 mm or 2.0 mm. The Pearson chi-square test was used to detect differences in the proportion of sites, showing bone loss above the cut-off levels

of 1.5 mm as evaluated on the intraoral radiographs between maxilla and mandible and between the cases with and without the pressure-like-ulcer.

In *Study III*, the data variation was not normally distributed, therefore in order to attain approximately normally distributed data the outcome variables; apex, hex and angle, except depth, were e-log transformed. In these three variables (apex, hex and angle), mean deviation at implant level was presented as the geometric mean, while mean of depth deviation was presented as arithmetic mean. Subsequently, parametric tests were used. Statistical analyses were performed using the paired t-test for the positional difference between virtually planned implants and inserted implants in the following outcome variables: apex, hex, angle and depth. The ANOVA (Analysis of Variance) was used when fixed factors, such as mandible and maxilla, pre-launch and launched components, and movement of the jaw in the pre-operative and post-operative CT scans, were included. All tests were two sided and $p < 0.05$ was considered as statistically significant. All data were presented using descriptive statistics.

In *Study IV*, the data variation was not approximately normally distributed, therefore the outcome variables, apex and hex, were e-log transformed. In these two variables, mean deviation at implant level was presented as the geometric mean. Subsequently, parametric tests were used. Statistical analyses were performed using the paired t-test for the positional differences between the implant replica position obtained from the pre- and postoperative master models in the apex and hex. All tests were two sided and $p < 0.05$ was considered as statistically significant. All data were presented using descriptive statistics.

RESULTS

Clinical examination

Study I

Survival and losses

One hundred and fifty seven out of 176 implants (89%) survived during the follow-up period of up to 44 months. All the patients have been followed up for at least 6 months and mean follow-up period was 19.6 months. Implant survival rate by position was 92 % in the maxilla and 84 % in the mandible. Nineteen implants (11 %), 10 of 124 implants in the maxilla (8%) and 9 of 52 implants (17%) in the mandible were removed within 18 months after surgery. The number of implant losses was higher among smokers (12/39, 31 %) compared with non-smokers (7/137, 5 %), although this difference was not significant. Implant-supported suprastructures remained clinically stable and functional in 26 out of 31 cases, 19 of 21 cases in the maxilla and 7 of 10 cases in the mandible. Five suprastructures were removed within 6 months after surgery. The following tables (Table 2-5) presented the CSR (Cumulative Survival Rate) of implants and prostheses.

Table 2. Life-table analysis of implants in the **Maxilla** included in *Study I*

Follow-up period	Fixtures at the beginning of the period	Fixtures lost to follow-up	Failures	Interval survival rate	Cumulative survival rate
Loading – 6 mon	124	0	3	97.6%	97.6%
6 mon – 1 yr	121	30	6	95.0%	92.7%
1 – 2 yr	85	31	1	98.8%	91.6%
2 – 3 yr	53	23	0	100%	91.6%
3 yr -	30				

Table 3. Life-table analysis of implants in the **Mandible** included in *Study I*

Follow-up period	Fixtures at the beginning of the period	Fixtures lost to follow-up	Failures	Interval survival rate	Cumulative survival rate
Loading – 6 mon	52	0	5	90.4%	90.4%
6 mon – 1 yr	47	15	1	97.9%	88.5%
1 – 2 yr	31	18	3	90.3%	79.9%
2 yr -	10				

Table 4. Life-table analysis of implants in the **Maxilla + Mandible** included in *Study I*

Follow-up period	Fixtures at the beginning of the period	Fixtures lost to follow-up	Failures	Interval survival rate	Cumulative survival rate
Loading – 6 mon	176	0	8	95.5%	95.5%
6 mon – 1 yr	168	45	7	95.8%	91.5%
1 – 2 yr	116	49	4	96.6%	88.4%
2 – 3 yr	63	33	0	100%	88.4%
3 yr -	30				

Table 5. Life-table analysis of prostheses included in *Study I* from loading up to 6 months

Follow-up period	Prostheses at the beginning of the period	Prostheses lost to follow-up	Failures	Interval survival rate	Cumulative survival rate
Loading – 1 mon	31	0	2	93.5%	93.5%
1 – 3 mon	29	0	1	96.6%	90.3%
3 – 6 mon	28	0	2	92.9%	83.9%

Complications

Surgical and technical complications occurred in 13 of 31 cases.

- Fracture of surgical template: 3 cases
- Misfit of suprastructure: 5 cases
- Extensive adjustment of occlusion: 3 cases
- Radiographic bone defects after drilling: 3 cases
 - around anchor pins: 2 cases
 - around implants: 1 cases

Three surgical templates fractured either before surgery (1 case) or at the removal of the surgical template after implant insertion (2 cases) (Figure 8). Misfit of the suprastructure appeared in 5 cases, resulting in the disconnection of the suprastructure in 2 cases where implants were left for unloaded healing (Figure 9). Extensive adjustment of occlusion was made in 3 cases of immediately connected bridges (Figure 10). In 2 cases, adjustment was made by re-alignment of teeth of the removal denture in the opposing jaw. In 1 case, the heavy grinding of the occlusal surfaces resulted in remaking of the implant-supported bridge after 6 months of healing. Radiographic bone defects after drilling developed in 3 cases. This appeared in 2 cases after anchor-pin

drilling in the maxilla, and another case in a severely resorbed mandible. An outline of the complications in these patients is shown in Table 6.

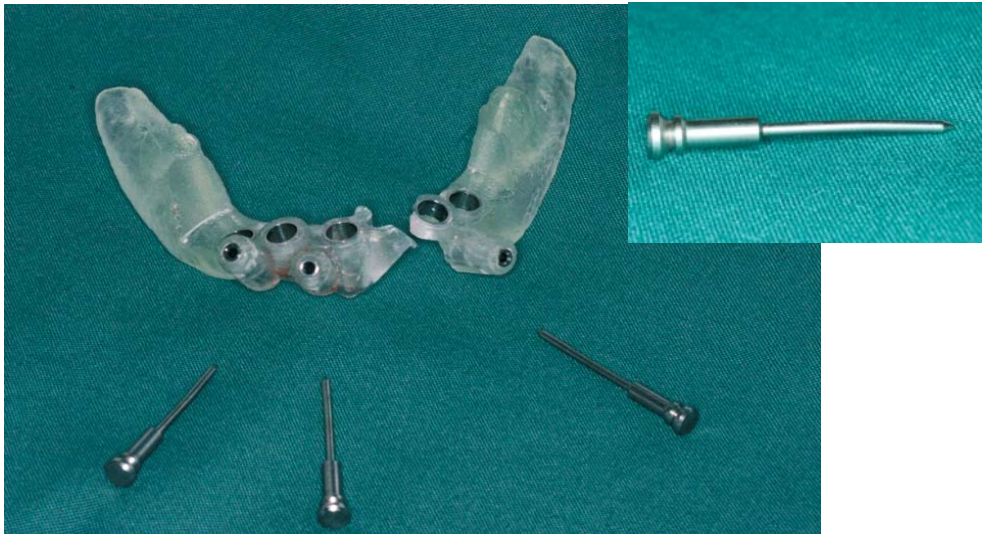


Figure 8. Fracture of surgical template and bent anchor pin

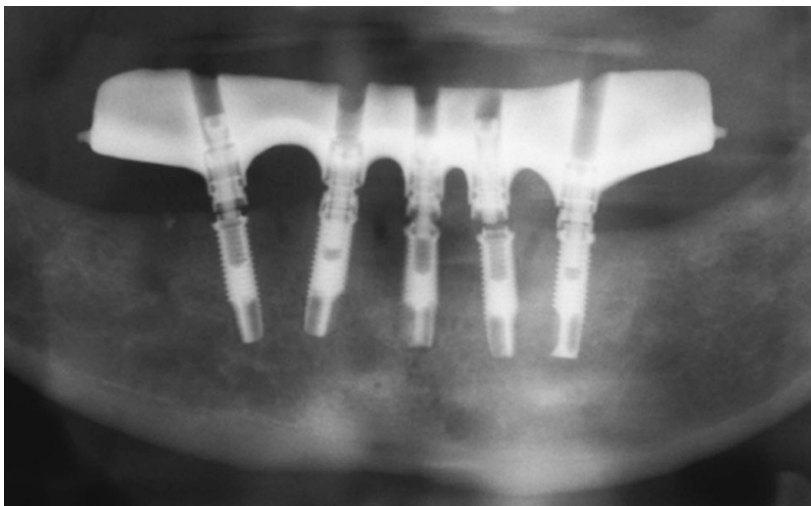


Figure 9. Misfit of prosthesis

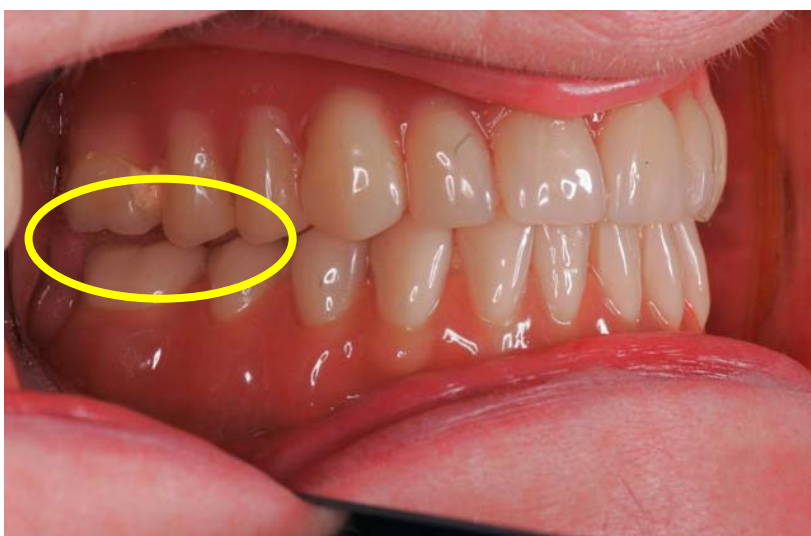

Figure 10. Occlusal misfit

Table 6. Complications in 13 cases included in *Study I*

Patient	Prosthesis position	Drill guide fracture	Misfit between abutments and implants *	Removal of prosthesis due to misfit unloaded healing	Extensive adjustment of occlusion	Radiographic bone defect	Number of implants lost	Removal of bridge due to implant loss	Prefabricated prosthesis not in function
BT	MAX					X			
IE	MAX					X			
GZ	MAX		(6/6)		X				
AMU	MAX				X				
LR	MAND						2		
KA	MAX						3	X	X
MC	MAND	X	(2/5)	X		X	5	X	X
AB	MAX						6	X	X
EB	MAND	X	(1/5)				2	X	X
TK	MAX		(1/6)						
GY	MAND		(2/5)	X					X
AML	MAND	X			X				
FJ	MAX						1		
Total	Max 8/21(38%) Mand 5/10(50%)	3/31 (10%)	Br: 5/31(16%) P: 5/29(17%)	2/31(6%)	3/31 (10%)	3/31 (10%)	I:19/176(11%) Br: 6/31 (19%) P: 6/29(21%)	3/31(10%)	5/31(16%)

*Misfit between abutments and implants = (No. of abutment-implant misfit / No. of implants installed)

MAX: Maxilla, MAND: Mandible, I: Implant level, Br: Bridge (prosthesis) level, P: Patient level

Study II

Soft-tissue condition

Clinical assessments of peri-implant soft tissue (PD, BoP), as well as the presence of plaque, were made around 148 implants (maxilla: 101, mandible:47) in 26 out of 29 cases. In 3 cases (2 patients), a compromised physical condition only allowed clinical examinations but without the removal of the suprastructure. The clinical assessments made in these patients were excluded from the database and statistical analysis. The results of the clinical assessments including PD, BoP, and presence of plaque at case level in the 26 cases are presented in Table 7. PD was significantly deeper in the maxilla compared to the mandible, both at case ($p = .02$) and at implant level ($p < .0001$). PD more than 4 mm was noted in 19.6 % of all measured sites in the maxilla and 6.4 % in the mandible. No difference in BoP or visible plaque around implants was observed between the maxilla and mandible, and the mean of both plaque index and BoP showed a wide individual range (PI: 0-100 %, BOP: 16-100 %).

In 9 cases, a pressure-like-ulcer was observed when the fixed prosthesis was removed (Figure 11). In the cases with the pressure-like-ulcer and tight contact between the soft tissue and the basal surface of the fixed dental prosthesis, accumulation of plaque and debris was frequently observed under the prosthesis. However, no statistically significant difference was detected between the case with and without a pressure-like-ulcer in PD and BoP.

Table 7. Soft tissue conditions at ≥ 1 -year follow-up (at case level)

Position (no.of cases)	PI (%)			PD (mm)			BoP (%)		
	Mean (SD)	Min	Max	Mean (SD)	Min	Max	Mean (SD)	Min	Max
Max+Mand (26)	45.2 (37.0)	0.0	100	2.6 (0.6)	1.4	4	81.9 (23.9)	15.8	100
Maxilla (17)	39.4 (35.4)	0.0	100	2.8 (0.6)	1.5	3.7	79.8 (26.1)	15.8	100
Mandible (9)	56.1 (39.6)	0.0	100	2.1 (0.5)	1.4	2.8	85.9 (16.5)	50.0	100
<i>p</i> value *	<i>n.s</i>			<i>p</i> =.02			<i>n.s.</i>		

**p* values calculated with Mann-Whitney *U* test

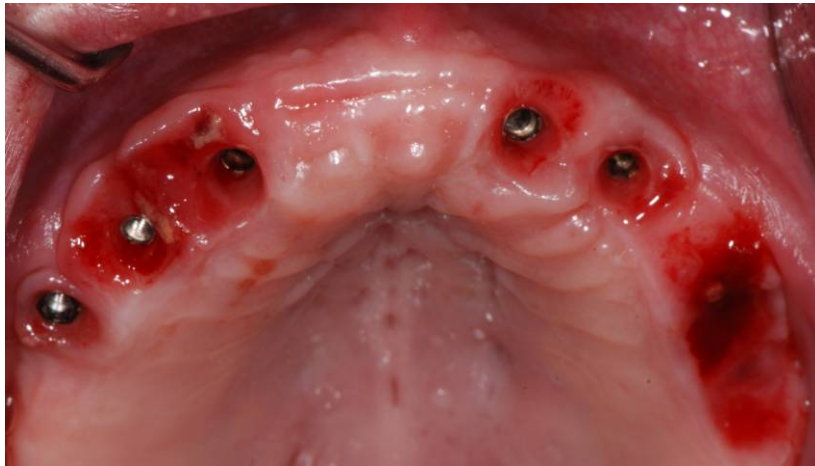


Figure 11. Pressure-like-ulcer caused by tight contact with the basal surface of the prosthesis

Implant stability

ISQ readings were obtained for 66 out of 67 implants inserted in the 12 jaws (maxilla: 7, mandible: 5). All the implants measured were clinically stable at the follow-up. ISQ registered during the initial surgery and at the ≥ 1 -year follow-up was compared for each jaw. When comparing the obtained ISQ, it was found that the mean ISQ measured during surgery was 62.0 (SD =7.8, range: 43-76) in the maxilla, while it was 70.6 (SD=5.6, range: 58-82) in the mandible. Assessments during the first year after surgery showed the mean values of both maxilla and mandible to slightly increase to 62.3 (SD =7.0, range: 46-75) and 71.8 (SD=4.6, range: 57-79), respectively. The ISQ was significantly higher in the mandible than in the maxilla both at the initial surgery ($p<.0001$) and at the ≥ 1 -year follow-up ($p<.0001$).

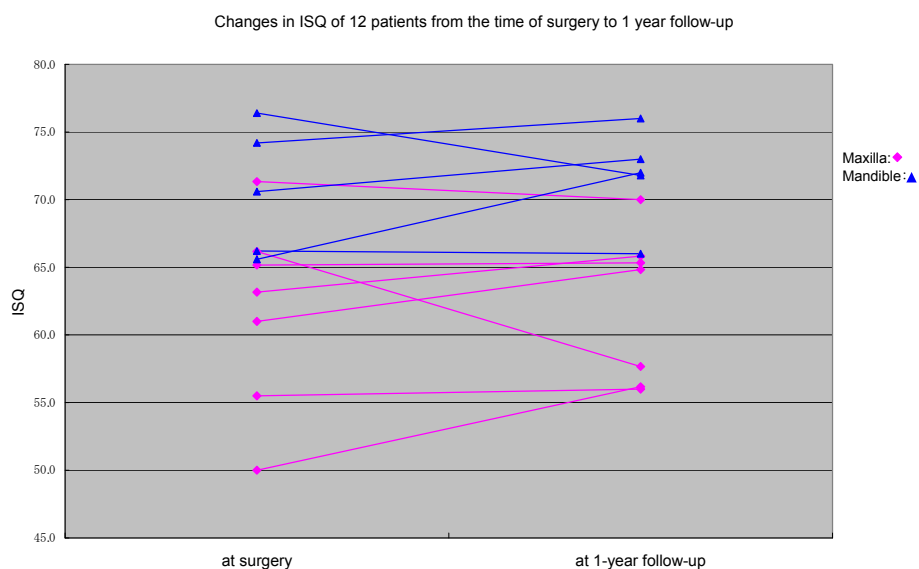


Figure 12.Changes in ISQ of 12 patients from the time of surgery to 1-year follow-up

Radiographic examination

Study II

Marginal bone changes

Due to the low resolution of the panoramic radiographs in the region around the midline, only 193 of 324 sites (162 implants) were judged as readable and were included for the marginal bone changes after function (60%). The frequency of the radiographic marginal bone changes evaluated on the panoramic radiographs is presented in Table 8. The mean marginal bone changes of the readable sites was -1.3 fixture threads in the maxilla and -1.4 fixture threads in the mandible, which can be estimated to -0.8 mm and -0.85 mm, respectively (using a distance of 0.6 mm between fixture threads).

Additional evaluation of radiographic marginal bone loss was carried out using intraoral radiographs at 136 sites (68 implants) in 13 cases (Table 9). Across all the intraoral radiographs, 11 sites (8%) were not perpendicular to the fixture threads (one case), and image was missing in four sites, and thus, they were excluded. The mean follow-up period of these 12 cases was 13 months. The mean marginal bone changes of measured sites was -1.17 mm (SD =1.23) in the maxilla and -1.37 mm (SD=1.76) in the mandible. Despite, there being a large deviation in marginal bone changes following the panoramic and intraoral readings, there was no difference in marginal bone changes during function between the maxilla and mandible evaluated at implant or case level.

A significantly greater number of sites showed a marginal bone loss more than 2 mm in the mandible compared to the maxilla (Table 10a). Of the 12 cases evaluated with intraoral radiographs, a pressure-like-ulcer was found in 5 cases. The proportion of measured sites with marginal bone loss of both > 1.5 mm ($p =.01$) and > 2.0 mm ($p =.003$) was significantly higher in the case with a pressure-like-ulcer compared to cases where no ulcer was found ($p =.01$) (Table 10b).

Table 8. Radiographic changes of mean marginal bone levels from the time of surgery to ≥ 1 -year follow-up (Panoramic radiograph)

Mean marginal bone changes	Maxilla			Mandible			Max+Mand
	No. of sites	No. of sites	No. of sites	Frequency			
				(%)	(%)	(%)	
(Threads)							
2	2	2	0	0	2	2	1.0
1.5	0	0	0	0	0	0	0.0
1	1	1	2	2	3	3	1.6
Bone gain (+)	0	0	0	0	0	0	0.0
0	32	32	29	27.1	61	61	31.6
Bone loss (-)	0	0	0	0	0	0	0.0
0.5	33	33	21	28.0	54	54	28.0
1	3	3	0	2.5	3	3	1.6
1.5	26	26	4	22.0	30	30	15.5
2	1	1	0	0.8	1	1	0.5
2.5	13	13	8	11.0	21	21	10.9
3	0	0	2	0.0	2	2	1.0
3.5	5	5	7	4.2	12	12	6.2
4	0	0	0	0.0	0	0	0.0
4.5	2	2	2	1.7	4	4	2.1
≥ 5	118	118	75	100	193	193	100.0
Total							
Mean marginal bone changes(SD)	-1.34 (1.36)	-1.34 (1.36)	-1.41 (2.0)	n.s.*	-1.37 (1.64)	-1.37 (1.64)	
Range (Threads)	2 -(-7)	2 -(-7)	1 -(-11)		2 -(-11)	2 -(-11)	
At case level							
Mean marginal bone changes(SD)	-1.44 (0.78)	-1.44 (0.78)	-1.27 (1.33)	n.s.*	-1.39 (0.98)	-1.39 (0.98)	
Range	0 -(-3.25)	0 -(-3.25)	0 -(-4.35)		0 -(-4.35)	0 -(-4.35)	

p values calculated with Mann-Whitney U test

Table 9. Radiographic changes of mean marginal bone levels from the time of surgery to ≥ 1 -year follow-up (Intraoral radiograph)

Mean marginal bone changes (mm)	Maxilla			Mandible			Max+Mand
	No. of sites	(%)	Frequency	No. of sites	(%)	No. of sites	
Bone gain (+)							
1.1-2.0	1	1.2	1	1	2.6	2	1.7
0.1-1.0	14	16.9	13	13	34.2	27	22.3
0	2	2.4	0	0	0.0	2	1.7
Bone loss (-)							
0.1-1.0	21	25.3	3	3	7.9	24	19.8
1.1-2.0	28	33.7	5	5	13.2	33	27.3
2.1-3.0	10	12.0	9	9	23.7	19	15.7
3.1-4.0	5	6.0	6	6	15.8	11	9.1
4.1-5.0	2	2.4	1	1	2.6	3	2.5
Total	83	100	38	38	100	121	100
Mean marginal bone changes (SD)	-1.17 (1.23)	n.s.*	-1.37 (1.76)	-1.23 (1.42)			
Range (mm)	1.8 - (-4.4)		1.1 - (-5.0)	1.8 - (-5.0)			
At case level							
Mean marginal bone changes(SD)	-1.26 (0.6)	n.s.*	-1.36 (1.72)	-1.29 (1.02)			
Range (mm)	-0.5 - (-2.2)		0.3 - (-3.0)	0.3 - (-3.0)			

*p-values calculated with Mann-Whitney U test

Table 10.

a. The proportion of the number of sites with bone loss more than 1.5 mm or 2.0 mm in the maxilla and mandible

	Cut-off level 1.5 mm			Cut-off level 2.0 mm		
	Bone loss < 1.5mm	Bone loss > 1.5 mm	Total	Bone loss < 2.0mm	Bone loss >2.0 mm	Total
Maxilla	51 (61%)	32 (39%)	83	66 (80%)	17 (20%)*	83
Mandible	20 (53%)	18 (47%)	38	22 (58%)	16 (42%)*	38
<i>p</i> -value*	<i>n.s.</i>					
Total	71 (59%)	50 (41%)	121	88 (73%)	33 (27%)	121

b. The proportion of the number of sites with bone loss more than 1.5 mm or 2.0 mm in cases with and without a pressure-like-ulcer

	Cut-off level 1.5 mm			Cut-off level 2.0 mm		
	Bone loss < 1.5mm	Bone loss > 1.5 mm	Total	Bone loss < 2.0mm	Bone loss >2.0 mm	Total
No Ulcer (%)	46 (69%)	21 (31%)*	67	56 (84%)	11(16%)*	67
Ulcer (%)	25 (46%)	29 (54%)*	54	32 (59%)	22 (41%)*	54
<i>p</i> -value*	<i>p</i> =0.01					
Total	71 (59%)	50 (41%)	121	88 (73%)	33 (27%)	121

n = measured sites

* *p*-values calculated with Pearson chi-square test.

Evaluation of accuracy

Study III and Study IV

In *Study III*, virtually planned implant positions and clinically placed implant positions were compared using voxel-based matching. Mean deviation between planned and inserted implants at each variable is presented in Table 11 below. Differences in position were observed between the virtually planned and the inserted implants both in the maxilla and mandible. However, when all four variables were taken into consideration, no statistically significant difference was observed between the deviations in the maxilla and in the mandible.

During the matching procedure, it was apparent that in some cases the segmented implants from the ≥ 1 -year follow-up CT scan was not cylindrical in shape as the original implant shape. This could be attributed to movement by the patients during their CT scans. One radiologist reviewed all the CT images obtained from the patients' pre-operative and post-operative scan. Double contours, implying that the patient had moved during the scans, were found from both the pre-operative and post-operative CT data. Although the movement factor was not originally considered as a variable for inclusion, additional calculations were conducted to include this factor for exploratory analysis. The numbers of the implants classified as "movement" are presented in Table 12. The mean e-log apex and mean e-log hex results showed statistically significant differences between the presence and absence of movement during the pre-and post-operative CT scans (Figure 13). No significant differences were observed between the maxilla and mandible except angle deviation (maxilla: 3.1°, mandible: 2.4°), even when the movement factor was included in the analysis. Deviation of implants without any movement and implants with movement both during the pre- and post-operative scan is presented in Table 13.

Table 11. Mean deviation between planned and inserted implant positions (*Study III*)

	Mean (range)			
	Hex: <i>mm</i>	Apex: <i>mm</i>	Angle: <i>degree</i>	Depth : <i>mm</i>
Max+Mand	0.8 (0.1-2.68)	1.09 (0.24-3.62)	2.26 (0.24-11.74)	-0.15 (-2.33-2.05)
Maxilla	0.8 (0.1-2.68)	1.05 (0.25-2.63)	2.31 (0.24-6.96)	-0.06 (-1.65-2.05)
Mandible	0.8 (0.16-2.45)	1.15 (0.24-3.62)	2.16 (0.27-11.74)	-0.29 (-2.33-0.94)

Table 12. Movement during the pre-operative and post-operative scanning
(n=number of implants included)

	Post-op scan Movement	Post-op scan Non-movement
Pre-op scan Movement	15	6
Pre-op scan Non-movement	28	90

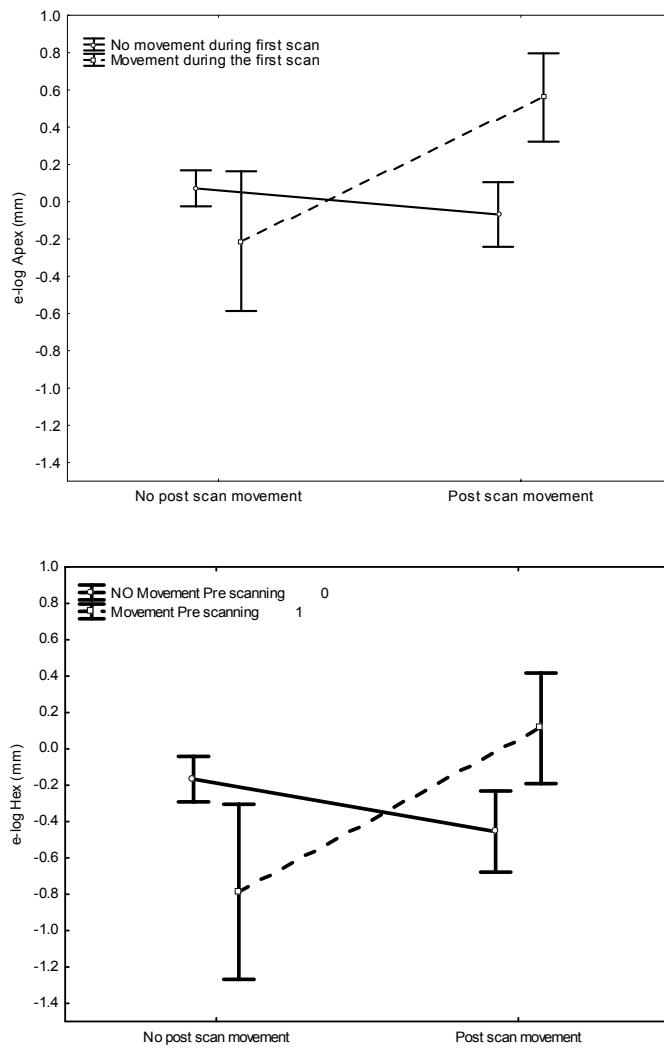


Figure 13. Mean e-log apex (upper) and mean e-log hex (lower) differences between presence and absence of movement during pre-operative and post-operative scans

Table 13

a. Deviation of implants without any movement during CT scan

Deviation	No. of implants	Mean	Min	Max
Hex	90	0.85	0.20	2.68
Apex	90	1.07	0.24	2.63
Angle	90	2.00	0.24	6.96
Depth	90	-0.09	0.01*	2.05*

b. Deviation of implants with movement both during pre- and post-operative CT scan

Deviation	No. of implants	Mean	Min	Max
Hex	15	1.12	0.16	2.45
Apex	15	1.75	0.69	3.62
Angle	15	4.27	1.97	11.74
Depth	15	-0.57	0.03*	2.33*

*Minimum and maximum in depth are presented using distance from base line (planning = 0)

In *Study IV*, the accuracy of implant placement was assessed using plaster models containing implant replicas, one created from the surgical template and the other created from the patient's impression at the ≥ 1 year follow-up. There were significant differences in position between the planned implants and clinically inserted implants (Table 14). Significant differences in deviation between the maxilla and mandible were also detected ($p < 0.001$). When comparing the results from *Study III* and *Study IV*, significant differences were observed both at the apex and hex ($p < 0.001$). In addition, no statistically significant difference in deviation was found between hex and apex in *Study IV*, while there was a significant difference in deviation between hex and apex in *Study III*.

Table 14. Mean deviation between planned and inserted implant positions (*Study IV*)

	Mean (range)	
	Hex: mm	Apex: mm
Max+Mand	0.51 (0.06 - 1.16)	0.51 (0.13 - 1.25)
Maxilla	0.59 (0.09 - 1.16)	0.59 (0.14 - 1.25)
Mandible	0.39 (0.06 - 0.97)	0.40 (0.13 - 1.24)

DISCUSSION

Today, computer-assisted implant treatment is becoming a trend in implant dentistry. However, whether the new methods can offer patients as successful and reliable treatment as the conventional methods has not yet been shown scientifically. In this thesis, the NobelGuide™ in combination with Teeth-in-an-Hour™ was evaluated mainly from three perspectives, discussed in the following sections.

CLINICAL PERFORMANCE

Study I and II focused on the clinical performance of the NobelGuide™ and Teeth-in-an-Hour™, including survival rates, complications and peri-implant soft tissue conditions. Until now, several studies have shown long-term survival rates of implants of over 90 % in both the maxilla and the mandible following the traditional methods (Lindquist et al., 1996, Ekelund et al., 2003, Jemt and Johansson, 2006). Compared to the survival rates following conventional surgical protocols and unloaded healing, lower survival rates of implants and prostheses were found in *Study I* (89 % at implant level, 84 % at prosthesis level). Furthermore, complications occurred in as many as 13 of the 31 cases (42 %). Although the survival rate of 92 % in the maxilla was acceptably good, a lower survival rate of 80 % was observed in the mandibular cases. This fact contradicts the results of conventional surgical protocols or one-stage surgery with immediate/early loading, where the implant survival rate is usually slightly higher in the mandibular cases compared to the maxillary cases. While uncontrolled occlusal force application through function and parafunction were suspected to be a main cause of the implant losses in the maxilla, implant losses in the mandible rather seemed to be caused by complications related to this specific technique. Complications were registered in as many as 50 % of the mandibular cases in *Study I*.

Most complications observed in *Study I* were related to this specific technique or hardware, which is different from complications observed from conventional methods. The main complications during the surgery and the follow-up were; fracture of the surgical template, misfit of the prosthesis, extensive occlusal adjustment, radiographic bone defects and pressure-like-ulcer in the mucosa under the suprastructure.

Dense mandibular jaw bone in the region between the mental foramina, creating tension in a more fragile surgical template in the mandible, might be a possible

explanation for the surgical template fractures seen in 3 of the 10 mandibular treatments. In 2 of the patients with surgical template fracture, a misfit between the abutments and implants was observed at the post-operative radiographic examinations. Radiographic bone defects after surgery occurred in 3 cases; around anchor pins in 2 cases and around implants in one mandibular case. A likely reason for the infection/radiographic bone defects might have been overheating during the anchor pin/implant preparation. Thermonecrosis has been reported to occur as a result of excessive force or insufficient cooling of drills (Eriksson et al., 1982, Eriksson et al., 1984, Brisman, 1996). Increased heat production may result in failure to achieve osseointegration (Eriksson and Albrektsson, 1983) or the development of apical bone loss around implants. In the flapless procedure, direct saline irrigation on the bone surface was unmanageable, because the acrylic surgical template covers the mucosa and alveolar bone. Even though profound saline irrigation was made at the drill access site/position of implants, this might not be enough in areas of dense bone. In the one mandible with suspected thermonecrosis, the patient lost all five inserted implants. Thus, additional attention should be paid to the drill speeds, drill intermittence and irrigation, especially in the dense bone to minimise the risk of overheating.

One explanation for the occurrence of misfit of the prosthesis and unfavourable occlusion may be that the implants were not positioned clinically, as it was virtually planned in the computer. The positional deviations were analysed in *Study III and IV*.

A pressure-like-ulcer is one of the most frequently observed complications during the follow-up period (9/29 cases). This was most likely caused by the tight contact between the mucosa and the basal surface of the prosthesis. The overt feature of this technique is that the implant-supported prosthesis is prefabricated and finalised based on the computer planning data before implant insertion, whereas in conventional implant treatment, the prosthesis is created according to an impression taken after implant insertion. Therefore, in this technique the accuracy of each step in the procedure will affect not only the implant positions, but also the final outline of the suprastructure. The lack of use of a provisional implant bridge in the present study also made it difficult to get a picture of the relation between the suprastructure and the soft tissue. In the cases with the pressure-like-ulcer and tight contact between the soft tissue and the basal surface of the fixed prosthesis, accumulation of plaque and debris was frequently observed under the prosthesis. However, no statistically significant difference was detected in plaque assessments between the cases with and without a

pressure-like-ulcer in *Study II*. This may be due to the fact that plaque was assessed without removing the suprastructure. Limited visibility and accessibility only allowed for the detection of plaque presence on the surface of the prosthesis. The wide range, 0-100 %, of the mean plaque score may also be attributed to the way the plaque was assessed.

During *Study I* and *II*, abutment design was changed. In the first 9 cases, the patients received a bridge including initial hollow type abutments, whereas the rest of the patients received modified abutments equipped with a silicone o-ring around their exterior to avoid accumulation of plaque or debris between the abutments and the cylinders of the prosthesis. Although no data is presented in *Study II*, we found that large amounts of plaque accumulated inside the initial hollow type abutments when the suprastructures were removed. Thus, the design of the abutment and the suprastructure may influence the soft-tissue conditions around implants.

Parameters such as a presence of clinical inflammation and PD also reflect the clinical performance and supporting tissue reactions during follow-up (Qurynen et al., 1991, Lang et al., 1994, Pontoriero et al., 1994, Schou et al., 2002, Karoussis et al., 2004, Fransson et al., 2008). *Study II* showed the mean BoP to be approximately 80 % at case level. This high frequency of clinical inflammation around implants was consistent with several previous studies (Lekholm et al., 1986, Fransson et al., 2008). Fransson et al. reported that BoP was found around more than 90 % of implants even though no progressive bone loss occurred. This implies that the measurement of BoP alone cannot be used for the assessment of peri-implant tissue. The mean PD was 2.8 mm in the maxilla and 2.1 mm in the mandible at case level, which is comparable to previous studies. Although several reports have indicated that PD of approximately 3 mm can be detected around successful implants, the diagnostic value of probing around implants is still not clear (Buser et al., 1991). Further long-term prospective assessments of the soft tissues around implants are required to evaluate the association between PD, BoP and disease progression.

Regarding implant stability, a greater ISQ was observed in the mandibular implants than the maxillary implants, which is in accordance with previous studies. In the maxilla, 3 implants showed an ISQ value below 50 at the 1-year follow-up. Nevertheless, none of these implants showed clinical or radiographic signs of disintegration. To establish if the monitoring of ISQ over time can detect failing implants requires further careful clinical observation.

In the current studies, the surgery including prosthesis connection was completed within 30-45 minutes, with minimal surgical trauma in the majority of individuals. In addition, the patient's post-operative discomfort such as pain and swelling was almost negligible in successfully treated cases. However, the survival rates of implants and prostheses were lower compared with results of conventional treatment protocols and complications occurred at high rates. Therefore, further long-term investigations are required for comprehensive evaluation and refinement of this system.

RADIOGRAPHIC MARGINAL BONE CHANGES

The amount of bone loss found in *Study II* corroborates with others presenting bone loss of immediately loaded Brånemark system implants installed in edentulous jaws (Chow et al., 2001, Aalam et al., 2005, Östman et al., 2005, Glauser et al., 2005). In these studies, the mean bone loss at 1-year from prosthetic connections was found to range between 0.6 mm to 1.3 mm, which is comparable to the bone loss during functional loading observed in the 12 cases evaluated with intraoral radiographs in *Study II*. The results of the current study are also comparable to the data from studies using template-guided surgery and immediate loading of a CAD/CAM based prefabricated prosthesis (Malo et al., 2007, Sanna et al., 2007, Johansson et al., 2008), although only panoramic radiographs were used for the assessment of bone levels in one study (Sanna et al., 2007).

In our study, the marginal bone changes were assessed both on panoramic and intraoral radiographs. Greater bone loss was found around implants using intraoral radiographs, than when the marginal bone level was evaluated on panoramic radiographs, highlighting deviations between the two radiographic methods used. The mean marginal bone change of the readable sites was -0.82 mm (-1.4 fixture threads) with panoramic radiographs while it was -1.23 mm with intraoral radiographs. Only 12 cases were evaluated both using intraoral and panoramic radiographs, but the mean marginal bone change of the panoramic radiographs was identical, -0.82 mm (-1.4 fixture threads) when only looking at these 12 patients. In this study, as much as 40 % of all sites in the panoramic evaluations were excluded due to poor image quality (e.g. blurred bone margin, blunt peaks of the fixture threads or deformation of implants). The exclusion rate due to the low image quality was considerably higher than that of intraoral radiographs (8 %), indicating the limited utility of panoramic radiographs for the evaluation of marginal bone levels at implants. This limited applicability has also

been stated in other studies (Friedland, 1987, Truhlar et al., 1993). Moreover, marginal bone changes were assessed by counting the number of fixture threads on the panoramic radiographs, while measured in distance (mm) on intraoral radiographs. On the panoramic radiographs, the bone level was always recorded as “0” if the bone margin appeared more coronal to the first thread, as the peak of the most coronal threads was selected as a reference point. Utilising this method restricted the detection of bone level transition, mostly bone loss, in the region that was more coronal to the first thread. Therefore, data assessed on the intraoral radiographs were used to evaluate the association between marginal bone changes and some clinical findings.

The most commonly used reference point in assessing marginal bone level around implants is the implant-abutment junction (the upper surface of the implant collar). This point was, however, not clearly visible in all the radiographs used in our study, as the follow-up radiographs of the implants were taken with stainless-steel impression copings, used for *Study IV*, firmly connected to the implant.

Although no significant difference between the maxilla and the mandible was detected in mean marginal bone changes, the proportion of the number of the measured sites with marginal bone loss greater than 2.0 mm was statistically greater in the mandible than in the maxilla. This result may be an effect of the present computer assisted technique, and as a consequence, complications have also been reported to occur more frequently in the mandible than in the maxilla in *Study I*. Another factor that may have influenced the results is the starting point for monitoring marginal bone changes used in our study. The time of prosthesis connection is the most frequently used starting point in the observation of bone loss when treating with a conventional surgical protocol. However, Cochran et al. recently reported that the estimated mean marginal bone loss from the time of implant surgery until prosthesis connection at 4 to 6 months after surgery was significantly larger around implants in the mandible than in the maxilla, while the bone loss after the prosthesis connection up to 5 years was greater in the maxilla (Cochran et al., 2009). As a result, there was no significant difference in the mean marginal bone loss from the time of implant placement until 5-year post prosthesis placement between the maxilla and mandible. Most of the studies that evaluated marginal bone loss following conventional treatment protocol have not included this early period between surgery and prosthesis connection. In our study, the mean marginal bone loss occurring between the time of surgery, including prosthesis connection, and the 1-year follow-up was assessed. Considering the starting point and observation period in our study, our results were similar to the study by Cochran and

coworkers, in that the mean marginal bone loss in the mandible was greater than that in the maxilla in the early stage of the follow-up observation, though the loading protocol was different.

The relation between the marginal bone loss examined with intraoral radiographs and the presence of a pressure-like-ulcer and was also analysed. The statistical analysis demonstrated that the percentage of the sites with a marginal bone loss of > 1.5 mm or > 2.0 mm was greater in the cases with a pressure-like-ulcer than in cases where no ulcer was found. In these cases, a reduced accessibility of oral hygiene instrumentation may have increased bone loss during the initial healing period.

Although marginal bone loss around implant has been radiographically evaluated in many studies, the “acceptable amount of bone loss” remains to be defined. In the present study, marginal bone loss of more than 1.5 mm and 2 mm after 1 year from the prosthesis connection was observed in 41 % and 27 % of the measured sites, respectively. When bone loss from each site was simply evaluated according to Albrektsson’s success criteria, as many as 41 % of the measured sites were unsuccessful, as more than 1.5 mm of bone was lost during the first year after prosthesis connection. Our results also showed a wide range of bone loss. This high frequency of bone loss in this technique has also been reported by Malo et al. and Johansson et al. (Malo et al., 2007, Johansson et al., 2008). It may be reasonable to speculate that positional and angular deviations between planned and clinically placed implants might lead to biological adaptation during functional loading, resulting in marginal bone loss. Another reason could be that the starting point for monitoring the marginal bone level varies from study to study and the time between implant insertion and loading is not always as long as it is in conventional treatment, as already mentioned above. Marginal bone loss during initial healing and early functional loading, using more recently developed surgical protocols, needs to be further elucidated. According to recent studies, the bone loss between implant placement and the time of loading is significantly greater than the bone loss that occurs between the time of loading and the 5-year follow-up, under the conventional healing period of 3 to 6 months (Åstrand et al., 2004, Cochran et al., 2009). This implies the necessity of a careful evaluation when marginal bone loss, following the one-stage surgical protocol with immediate loading, is compared to that of the two-stage procedure.

ACCURACY OF TEMPLATE-GUIDED IMPLANT PLACEMENT

The template-guided surgery concept involves many processes that result in deviations between the planned and the clinically placed implant positions. The overall accuracy of the implant placement is the sum of all errors that arise during the whole treatment procedure. Although it is difficult to detect deviations that possibly occur in each step, it is essential for clinicians to learn to what extent the deviations occur between the virtually planned implant positions and positions of clinically placed implants, in order to avoid anatomical risks as well as for the final prosthetic reconstruction. The accuracy is also a great matter of concern, especially in the case of immediate delivery of a prefabricated prosthesis.

In *Study III*, the deviations between virtually planned implant positions and clinically inserted implant positions were assessed by matching the planning data based on the pre-operative CT scan and the post-operative CT scan from the ≥ 1 -year follow-up. The mean deviation was 1.05 mm at apex, 0.80 mm at hex, 2.31 degrees for angle and -0.06 mm for depth. Statistically significant differences were detected between the planned and placed implant positions in all four outcomes. The results of this study are well in line with the limits of previous studies (Schneider et al., 2009).

On the 3D virtual planning images, an area around the implant with a width of 1.5 mm, a safety zone, is indicated. This zone allows clinicians to avoid placing implants too close to each other or to anatomically important structures. It should be kept in mind that in several cases in our study the deviation was greater than 1.5 mm, indicating that the implant was inserted outside the safety zone. Despite that there were such extensive deviations in some cases, we did not find any damage to the anatomically important structures or interference of implants.

In *Study III*, no statistically significant difference in deviation was observed between the maxilla and mandible. The radiographic guide covered the palate in the maxilla, whereas in the mandible it covered only the alveolar crest. In addition, more complications were found in the mandible compared to the maxilla in *Study I*. Therefore, it was surprising to find no significant difference between the deviations in the mandible and in the maxilla. One possible reason is that 2 out of 5 cases, where a misfit of prosthesis was observed in *Study I*, were not included in *Study III* and *IV* due to implant loss resulting in a disconnection of the suprastructure during the follow-up. These 2 cases were mandibular cases. This could imply that the deviation in the mandible would be greater if these cases were included in the accuracy analysis.

As already mentioned in the results section, patient movements

during the CT scan were observed on 21 implants at the pre-operative CT images and on 43 implants during the post-operative scan of the patients. Fifteen implants in 3 patients included movements both from the pre-operative and post-operative CT scans. It should be emphasised that the patient movements, were in most cases not visible on the 3D images at the stage of virtual planning. Furthermore, the automatic superimposing procedure of gutta-percha markers on the CT data and prosthesis CT data sometimes proceeded without any notification of errors, even in the cases with patient movements. When comparing the results, statistical significances were found when combining the movement of the pre-operative and post-operative-scan with the results of the deviation at the level of the hex and apex of the implants.

The scanning time, using the equipment in our clinic, was 70 seconds, which is a long time to lie absolutely still especially for elderly patients. Imaging techniques represent a very rapidly evolving field and newer generations of CBCT equipment have a much reduced scanning time and include holders to keep the patient in position during scanning. This will likely reduce the movement error during the scanning procedure.

Although the matching of the pre-operative planning data and the post-operative CT data is the most commonly used technique for the assessment of accuracy in experimental studies, the excessive exposure of radiation on the patients from the post-operative scan and the patient movements during the CT scan are concerns. Patient movements occurred during the post-operative CT scan, something that did not influence treatment results, but affected only the results of matching for evaluation of the accuracy. To eliminate these factors, a new approach was carried out in *Study IV* by comparing two plaster-models, one created from the surgical template and the other made from impressions on copings attached to the implants in patients at ≥ 1 -year follow-up.

Significant deviations were detected between the positions of implant replicas in the pre-operative master models and in the post-operative plaster models that were created from patients' impressions, both at the hex and the apex. However, the deviations in *Study IV* were smaller than the deviations observed in *Study III*. This is understandable, as the results were not influenced by the patient movements in *Study IV*. Another factor contributing to the different deviations presented in *Study IV* could possibly be errors in the matching procedure, which aligns the 2 STL files. In *Study III*, patient jaws were used as reference objects when virtually planned implant positions and clinically placed implant positions were compared. In *Study IV*, however, no reference markers were used, which could have lead to errors during the matching

process. The matching procedure utilised in *Study IV*, the best-fit alignment, minimises the sum of the squared distances between corresponding points, selected from vertexes of the triangles of the virtually created cylinders from respective model. In *Study IV*, no significant difference was observed in the deviation between the apex and the hex, although the deviation at the apex is generally greater compared to that at the hex in the studies conducted using CT matching methods. Therefore, the lack of difference between the deviations at the apex and hex in this study may also partially be a result of the matching method. This fact became clear when the mean deviation at the level of hex and apex were compared on a case-by-case basis. The deviations at the hex and apex were fairly similar in each individual case.

One important benefit of using the impression based evaluation is that patients are not exposed to any excessive radiation as they are in the CT matching method. The radiation doses emitted by CBCT are lower than that of conventional CT, but are still greater than the doses utilised for panoramic and intraoral radiographs (Ludlow et al., 2003, Ludlow et al., 2006, Suomalainen et al., 2009). Although *Study IV* was a pioneer work for developing a new method, further refinements of the method are required to minimise the errors that arise during the matching procedure due to the absence of reference points.

The final results of accuracy shown in our studies are the sum of the deviations that occurred during each step of the whole treatment procedure including the production process and some additional errors that occurred in the process of matching. There are a lot of factors that cause errors, but it is difficult to pinpoint a certain factor that is particularly significant to the final outcome when reviewing the results of the present studies. However, it is possible to minimise some of the errors if the clinicians consider these sources of variation and carefully follow the instructions of the protocol. For instance, fitting and positioning of the radiographic guide, patient movements during CT scan, and the placement of the surgical template are considered to be major clinical factors that influence the final implant positions. The clinician should remember, that even the patient selection, the first step in the treatment, will affect the accuracy of implant placement. A severely resorbed mandible could lead to possible positioning errors when aligning the radiographic guide during the CT scan and when placing the surgical template during the surgery.

The results from *Study III and IV* gave us a better understanding of the deviations that could occur during the treatment of computer-assisted template-guided implant surgery. Furthermore, the findings could be used to implement more structured

directions on how to use computerised planning software. Further studies are required to clarify the deviations that may occur in each stage in a clinical setting as well as the accuracy of the products.

MAIN FINDINGS

- Survival rates of implants and prostheses were lower compared to conventional implant treatment protocols. In addition, complications occurred at a high rate when the patients were treated using the computer-assisted template-guided surgery in combination with immediate loading of a prefabricated prosthesis (*Study I*).
- Although mean marginal bone loss was within the range of other reports presenting mean marginal bone loss after immediate loading, patients treated using the computer-assisted template-guided surgery in combination with immediate loading of a prefabricated prosthesis showed a wide range of bone loss. High frequency of bone loss > 1.5 mm after 1 year of prosthesis connection was observed. However, marginal bone loss during initial healing and early functional loading, using more recently developed surgical protocols, needs to be further elucidated (*Study II*).
- Significant differences were observed between the virtually planned implant positions and the clinically placed implant positions both when using the CT matching method and the model matching method (*Study III & IV*).
- Although it might be possible to use our newly developed model matching method as a substitute for CT matching method in order to assess the accuracy of guided surgery, further refinements of the matching method are required to minimise the errors that arise during the matching procedure (*Study IV*).

CONCLUDING REMARKS

In recent years, dental implant treatment has more and more focused on the reduction of treatment time and simplification of the surgical and prosthetic procedures, and new systems are introduced on the market one after the other. Currently, it is believed that there are more than 200 implant brands available on the market to be used clinically. In these trends, a number of new implants and treatment systems are often launched without long term clinical evaluation. However, for the development of such systems, it is essential to report clinical findings, including complications, objectively.

Computer-guided implant surgery is one of the new technologies and is becoming widely used in clinical practice. It is assumed that computer-guided surgery has great potential to provide patients with an optimal treatment regarding shortening of the time needed for surgery, providing masticatory immediate function, and resulting in less post-operative discomfort. The technique also allows clinicians to plan implant positions with respect to both anatomical and prosthetic considerations. Many studies have reported excellent results from cadaver or model surgery. Several clinical follow-up studies and case reports have shown favourable results of computer-guided surgery. However, it should be emphasised that long-term clinical data is still limited and most of the published studies were conducted by skilled and experienced implant-teams. Thus, although promising for the future, the method of computer-assisted treatment planning and template-guided surgery must still be regarded as being in an exploratory phase. Further investigations regarding the clinical performance as well as the products may lead to more optimal results and an improvement of the system. In addition, assessments of the treatment from the patient's viewpoint will be of great importance in future studies.

ACKNOWLEDGEMENTS

I would like to express my sincere gratitude to everyone who has helped and supported me during the work on this thesis and my stay in Sweden.

I also wish to thank all the patients who participated in the studies for your understanding and cooperation.

In particular, I would like to thank:

My main supervisor, Dr. Margareta Hultin, for guiding me on the path of scientific research, for sharing your scientific knowledge with me and for your encouragement. You were always generous and very helpful, and have supported me not only with my research but also with my daily life in Sweden. I will miss the time I spent with you in the clinic.

Professor Björn Klinge, my co-supervisor, for accepting me as a Ph.D. student, for sharing your invaluable knowledge, and for fruitful discussions. Your great support and sense of humor have made my research a pleasure and have brightened many days.

Dr. Karin Näsström for a rewarding collaboration and for your expertise as a radiologist. Dr. Daniel Benchimol for your assistance with radiographic examinations as my co-author. Dr. Babak Falahat for your specialist advice. I would like to also thank the staff at the Division of Oral radiology for your warm friendship.

Andreas Pettersson, my co-author, for giving me tremendous advice, for valuable discussions and for your friendship.

Britta Bäckström in the specialist clinic, for your excellent assistance and for your kindness. Without your help it would not have been possible to conduct this project.

Dr. Inger Wårdh for interviewing patients and for giving me valuable advice on qualitative research.

All the staff members of the Division of Periodontology, Prof. Anders Gustafsson, Prof. Birgitta Söder, Dr. Per-Erik Engström, Dr. Jörgen Jönsson, Dr. Patricia De Palma, Dr. Kåre Buhlin, Dr. Annsofi Johannsen, Dr. Mattias Michelin and Mia Halling and others for your support, valuable discussions and friendship.

Secretaries Kerstin Smedberg and Heli Vänskä, for your kindness and the great assistance in administrative matters.

Prof. Matts Andersson, Jenny Fäldt, Timo Kero, Josefin Caous and Anna Persson for many fruitful discussions at the Ph.D. student meetings.

My colleagues and friends in the research division, Abier, Anna, Anna-Kari, Farzeen, Fawad, Fernanda, Gregory, Haleh, Hero, Jari, Joannis, Lena, Maha, Maryam, Melissa, Murad, Nikolaos, Nilminie, Peggy, Sara, Talat, Taraneh, Tove, Tülay, Ying and other colleagues for your kindness and warm friendship. I have many pleasant memories with you and will never forget them!

Japanese researchers Dr. Tomomi Kawakami, Dr. Yuko Oikawa, Dr. Toshinari Mikami, Dr. Yuko Miyashita and others working at KI, for your great help, the useful advice and your kindness. I was really fortunate to meet such wonderful Japanese researchers here in Sweden.

Dr. Rachael Sugars and Cecilia Hallström for the professional revision of my English text.

Jan Kowalski for helping me with statistical analyses.

Prof. P-I Brånemark for being a great source of encouragement and inspiration.

Niklas for your thoughtful support. You make my everyday life joyful and pleasant. Vilken tur att jag träffade dig! I also wish to thank Fam. Bergström for their warm-heartedness.

My father Yataro, my mother Yoko and my sister Akane for allowing me to do my research in Sweden, for giving me a lot of expert advice and for your tremendous support. It was my great pleasure to do my research in Sweden from where all of us have many nice memories.

REFERENCES

- Aalam, A. A., Nowzari, H. & Krivitsky, A. (2005) Functional restoration of implants on the day of surgical placement in the fully edentulous mandible: a case series. *Clin Implant Dent Relat Res*, 7, 10-6.
- Abrahamsson, I. & Soldini, C. (2006) Probe penetration in periodontal and peri-implant tissues. An experimental study in the beagle dog. *Clin Oral Implants Res*, 17, 601-5.
- Adell, R., Eriksson, B., Lekholm, U., Branemark, P. I. & Jemt, T. (1990) Long-term follow-up study of osseointegrated implants in the treatment of totally edentulous jaws. *Int J Oral Maxillofac Implants*, 5, 347-59.
- Adell, R., Lekholm, U., Rockler, B., Branemark, P. I., Lindhe, J., Eriksson, B. & Sbordone, L. (1986) Marginal tissue reactions at osseointegrated titanium fixtures (I). A 3-year longitudinal prospective study. *Int J Oral Maxillofac Surg*, 15, 39-52.
- Ainamo, J. & Bay, I. (1975) Problems and proposals for recording gingivitis and plaque. *Int Dent J*, 25, 229-35.
- Akagawa, Y., Hashimoto, M., Kondo, N., Satomi, K., Takata, T. & Tsuru, H. (1986) Initial bone-implant interfaces of submergible and supramergible endosseous single-crystal sapphire implants. *J Prosthet Dent*, 55, 96-100.
- Albrektsson, T., Blomberg, S., Branemark, A. & Carlsson, G. E. (1987) Edentulousness--an oral handicap. Patient reactions to treatment with jawbone-anchored prostheses. *J Oral Rehabil*, 14, 503-11.
- Andersson, M., Carlsson, L., Persson, M. & Bergman, B. (1996) Accuracy of machine milling and spark erosion with a CAD/CAM system. *J Prosthet Dent*, 76, 187-93.
- Aparicio, C., Rangert, B. & Sennerby, L. (2003) Immediate/early loading of dental implants: a report from the Sociedad Espanola de Implantes World Congress consensus meeting in Barcelona, Spain, 2002. *Clin Implant Dent Relat Res*, 5, 57-60.
- Arai, Y., Tammisalo, E., Iwai, K., Hashimoto, K. & Shinoda, K. (1999) Development of a compact computed tomographic apparatus for dental use. *Dentomaxillofac Radiol*, 28, 245-8.
- Astrand, P., Ahlqvist, J., Gunne, J. & Nilson, H. (2008) Implant treatment of patients with edentulous jaws: a 20-year follow-up. *Clin Implant Dent Relat Res*, 10, 207-17.
- Astrand, P., Engquist, B., Dahlgren, S., Grondahl, K., Engquist, E. & Feldmann, H. (2004) Astra Tech and Branemark system implants: a 5-year prospective study of marginal bone reactions. *Clin Oral Implants Res*, 15, 413-20.
- Balshi, S. F., Wolfinger, G. J. & Balshi, T. J. (2005) A prospective study of immediate functional loading, following the Teeth in a Day protocol: a case series of 55 consecutive edentulous maxillas. *Clin Implant Dent Relat Res*, 7, 24-31.
- Becker, W., Goldstein, M., Becker, B. E., Sennerby, L., Kois, D. & Hujoel, P. (2009) Minimally invasive flapless implant placement: follow-up results from a multicenter study. *J Periodontol*, 80, 347-52.
- Becker, W., Sennerby, L., Becker, B. E. & Henry, P. (2002) Clinical and histologic findings for microimplants placed in one stage and loaded for three months: a case report. *Clin Implant Dent Relat Res*, 4, 47-52.

- Berglundh, T., Abrahamsson, I., Lang, N. P. & Lindhe, J. (2003) De novo alveolar bone formation adjacent to endosseous implants. *Clin Oral Implants Res*, 14, 251-62.
- Berglundh, T., Lindhe, J., Marinello, C., Ericsson, I. & Liljenberg, B. (1992) Soft tissue reaction to de novo plaque formation on implants and teeth. An experimental study in the dog. *Clin Oral Implants Res*, 3, 1-8.
- Berglundh, T., Persson, L. & Klinge, B. (2002) A systematic review of the incidence of biological and technical complications in implant dentistry reported in prospective longitudinal studies of at least 5 years. *J Clin Periodontol*, 29 Suppl 3, 197-212; discussion 232-3.
- Bragger, U., Hugel-Pisoni, C., Burgin, W., Buser, D. & Lang, N. P. (1996) Correlations between radiographic, clinical and mobility parameters after loading of oral implants with fixed partial dentures. A 2-year longitudinal study. *Clin Oral Implants Res*, 7, 230-9.
- Brånemark, P. I., Adell, R., Breine, U., Hansson, B. O., Lindstrom, J. & Ohlsson, A. (1969) Intra-osseous anchorage of dental prostheses. I. Experimental studies. *Scand J Plast Reconstr Surg*, 3, 81-100.
- Brånemark, P. I., Engstrand, P., Ohnrell, L. O., Grondahl, K., Nilsson, P., Hagberg, K., Darle, C. & Lekholm, U. (1999) Branemark Novum: a new treatment concept for rehabilitation of the edentulous mandible. Preliminary results from a prospective clinical follow-up study. *Clin Implant Dent Relat Res*, 1, 2-16.
- Brånemark, P. I., Hansson, B. O., Adell, R., Breine, U., Lindstrom, J., Hallen, O. & Ohman, A. (1977) Osseointegrated implants in the treatment of the edentulous jaw. Experience from a 10-year period. *Scand J Plast Reconstr Surg Suppl*, 16, 1-132.
- Brisman, D. L. (1996) The effect of speed, pressure, and time on bone temperature during the drilling of implant sites. *Int J Oral Maxillofac Implants*, 11, 35-7.
- Brunski, J. B. (1999) In vivo bone response to biomechanical loading at the bone/dental-implant interface. *Adv Dent Res*, 13, 99-119.
- Brunski, J. B., Moccia, A. F., Jr., Pollack, S. R., Korostoff, E. & Trachtenberg, D. I. (1979) The influence of functional use of endosseous dental implants on the tissue-implant interface. II. Clinical aspects. *J Dent Res*, 58, 1970-80.
- Buser, D., Weber, H. P., Bragger, U. & Balsiger, C. (1991) Tissue integration of one-stage ITI implants: 3-year results of a longitudinal study with Hollow-Cylinder and Hollow-Screw implants. *Int J Oral Maxillofac Implants*, 6, 405-12.
- Cameron, H. U., Pilliar, R. M. & Macnab, I. (1973) The effect of movement on the bonding of porous metal to bone. *J Biomed Mater Res*, 7, 301-11.
- Campelo, L. D. & Camara, J. R. (2002) Flapless implant surgery: a 10-year clinical retrospective analysis. *Int J Oral Maxillofac Implants*, 17, 271-6.
- Cannizzaro, G., Leone, M., Consolo, U., Ferri, V. & Esposito, M. (2008) Immediate functional loading of implants placed with flapless surgery versus conventional implants in partially edentulous patients: a 3-year randomized controlled clinical trial. *Int J Oral Maxillofac Implants*, 23, 867-75.
- Chow, J., Hui, E., Liu, J., Li, D., Wat, P., Li, W., Yau, Y. K. & Law, H. (2001) The Hong Kong Bridge Protocol. Immediate loading of mandibular Branemark fixtures using a fixed provisional prosthesis: preliminary results. *Clin Implant Dent Relat Res*, 3, 166-74.

- Cochran, D. L., Morton, D. & Weber, H. P. (2004) Consensus statements and recommended clinical procedures regarding loading protocols for endosseous dental implants. *Int J Oral Maxillofac Implants*, 19 Suppl, 109-13.
- Cochran, D. L., Nummikoski, P. V., Schoolfield, J. D., Jones, A. A. & Oates, T. W. (2009) A prospective multicenter 5-year radiographic evaluation of crestal bone levels over time in 596 dental implants placed in 192 patients. *J Periodontol*, 80, 725-33.
- De Bruyn, H., Collaert, B., Linden, U. & Bjorn, A. L. (1997) Patient's opinion and treatment outcome of fixed rehabilitation on Branemark implants. A 3-year follow-up study in private dental practices. *Clin Oral Implants Res*, 8, 265-71.
- Degidi, M., Piattelli, A., Felice, P. & Carinci, F. (2005) Immediate functional loading of edentulous maxilla: a 5-year retrospective study of 388 titanium implants. *J Periodontol*, 76, 1016-24.
- Del Fabbro, M., Testori, T., Francetti, L., Taschieri, S. & Weinstein, R. (2006) Systematic review of survival rates for immediately loaded dental implants. *Int J Periodontics Restorative Dent*, 26, 249-63.
- D'haese, J., Van de velde, T., Komiyama, A., Hultin, M. & De Bruyn, H. Accuracy and complications using computer-designed stereolithographic surgical guides for oral rehabilitation by means of dental implants: A review of the literature. *Clin Implant Dent Relat Res*, in-press
- Dierens, M., Collaert, B., Deschepper, E., Browaeys, H., Klinge, B. & De Bruyn, H. (2009) Patient-centered outcome of immediately loaded implants in the rehabilitation of fully edentulous jaws. *Clin Oral Implants Res*, 20, 1070-7.
- Duret, F. & Preston, J. D. (1991) CAD/CAM imaging in dentistry. *Curr Opin Dent*, 1, 150-4.
- Ekelund, J. A., Lindquist, L. W., Carlsson, G. E. & Jemt, T. (2003) Implant treatment in the edentulous mandible: a prospective study on Branemark system implants over more than 20 years. *Int J Prosthodont*, 16, 602-8.
- Ericsson, I., Berglundh, T., Marinello, C., Liljenberg, B. & Lindhe, J. (1992) Long-standing plaque and gingivitis at implants and teeth in the dog. *Clin Oral Implants Res*, 3, 99-103.
- Eriksson, A., Albrektsson, T., Grane, B. & Mcqueen, D. (1982) Thermal injury to bone. A vital-microscopic description of heat effects. *Int J Oral Surg*, 11, 115-21.
- Eriksson, A. R. & Albrektsson, T. (1983) Temperature threshold levels for heat-induced bone tissue injury: a vital-microscopic study in the rabbit. *J Prosthet Dent*, 50, 101-7.
- Eriksson, R. A., Albrektsson, T. & Magnusson, B. (1984) Assessment of bone viability after heat trauma. A histological, histochemical and vital microscopic study in the rabbit. *Scand J Plast Reconstr Surg*, 18, 261-8.
- Esposito, M., Grusovin, M. G., Achille, H., Coulthard, P. & Worthington, H. V. (2009) Interventions for replacing missing teeth: different times for loading dental implants. *Cochrane Database Syst Rev*, CD003878.
- Etter, T. H., Hakanson, I., Lang, N. P., Trejo, P. M. & Caffesse, R. G. (2002) Healing after standardized clinical probing of the perimplant soft tissue seal: a histomorphometric study in dogs. *Clin Oral Implants Res*, 13, 571-80.
- Ewers, R., Schicho, K., Truppe, M., Seemann, R., Reichwein, A., Figl, M. & Wagner, A. (2004) Computer-aided navigation in dental implantology: 7 years of clinical experience. *J Oral Maxillofac Surg*, 62, 329-34.

- Feldkamp, L.A., Davis, L. C. & Kress, J. W. (1984) Practical cone-beam algorithm *J. Opt. Soc. Am.* 1, 612–9
- Ferreira, S. D., Silva, G. L., Cortelli, J. R., Costa, J. E. & Costa, F. O. (2006) Prevalence and risk variables for peri-implant disease in Brazilian subjects. *J Clin Periodontol*, 33, 929-35.
- Fortin, T., Bosson, J. L., Isidori, M. & Blanchet, E. (2006) Effect of flapless surgery on pain experienced in implant placement using an image-guided system. *Int J Oral Maxillofac Implants*, 21, 298-304.
- Fransson, C., Wennstrom, J. & Berglundh, T. (2008) Clinical characteristics at implants with a history of progressive bone loss. *Clin Oral Implants Res*, 19, 142-7.
- Friberg, B., Jemt, T. & Lekholm, U. (1991) Early failures in 4,641 consecutively placed Branemark dental implants: a study from stage 1 surgery to the connection of completed prostheses. *Int J Oral Maxillofac Implants*, 6, 142-6.
- Friberg, B., Sennerby, L., Meredith, N. & Lekholm, U. (1999) A comparison between cutting torque and resonance frequency measurements of maxillary implants. A 20-month clinical study. *Int J Oral Maxillofac Surg*, 28, 297-303.
- Friedland, B. (1987) The clinical evaluation of dental implants--a review of the literature, with emphasis on the radiographic aspects. *J Oral Implantol*, 13, 101-11.
- Gerber, J. A., Tan, W. C., Balmer, T. E., Salvi, G. E. & Lang, N. P. (2009) Bleeding on probing and pocket probing depth in relation to probing pressure and mucosal health around oral implants. *Clin Oral Implants Res*, 20, 75-8.
- Glauser, R., Ree, A., Lundgren, A., Gottlow, J., Hammerle, C. H. & Scharer, P. (2001) Immediate occlusal loading of Branemark implants applied in various jawbone regions: a prospective, 1-year clinical study. *Clin Implant Dent Relat Res*, 3, 204-13.
- Glauser, R., Ruhstaller, P., Windisch, S., Zembic, A., Lundgren, A., Gottlow, J. & Hammerle, C. H. (2005) Immediate occlusal loading of Branemark System TiUnite implants placed predominantly in soft bone: 4-year results of a prospective clinical study. *Clin Implant Dent Relat Res*, 7 Suppl 1, S52-9.
- Hämmerle, C. H., Stone, P., Jung, R. E., Kapos, T. & Brodala, N. (2009) Consensus statements and recommended clinical procedures regarding computer-assisted implant dentistry. *Int J Oral Maxillofac Implants*, 24 Suppl, 126-31.
- Hultin, M., Gustafsson, A., Hallstrom, H., Johansson, L. A., Ekfeldt, A. & Klinge, B. (2002) Microbiological findings and host response in patients with peri-implantitis. *Clin Oral Implants Res*, 13, 349-58.
- Hultin, M., Gustafsson, A. & Klinge, B. (2000) Long-term evaluation of osseointegrated dental implants in the treatment of partly edentulous patients. *J Clin Periodontol*, 27, 128-33.
- Jaffin, R. A. & Berman, C. L. (1991) The excessive loss of Branemark fixtures in type IV bone: a 5-year analysis. *J Periodontol*, 62, 2-4.
- Jemt, T. & Johansson, J. (2006) Implant treatment in the edentulous maxillae: a 15-year follow-up study on 76 consecutive patients provided with fixed prostheses. *Clin Implant Dent Relat Res*, 8, 61-9.
- Jepsen, S., Ruhling, A., Jepsen, K., Ohlenbusch, B. & Albers, H. K. (1996) Progressive peri-implantitis. Incidence and prediction of peri-implant attachment loss. *Clin Oral Implants Res*, 7, 133-42.

- Johansson, B., Friberg, B. & Nilson, H. (2008) Digitally Planned, Immediately Loaded Dental Implants with Prefabricated Prostheses in the Reconstruction of Edentulous Maxillae: A 1-Year Prospective, Multicenter Study. *Clin Implant Dent Relat Res*.
- Jung, R. E., Schneider, D., Ganeles, J., Wismeijer, D., Zwahlen, M., Hammerle, C. H. & Tahmaseb, A. (2009) Computer technology applications in surgical implant dentistry: a systematic review. *Int J Oral Maxillofac Implants*, 24 Suppl, 92-109.
- Kapos, T., Ashy, L. M., Gallucci, G. O., Weber, H. P. & Wismeijer, D. (2009) Computer-aided design and computer-assisted manufacturing in prosthetic implant dentistry. *Int J Oral Maxillofac Implants*, 24 Suppl, 110-7.
- Karoussis, I. K., Muller, S., Salvi, G. E., Heitz-Mayfield, L. J., Bragger, U. & Lang, N. P. (2004) Association between periodontal and peri-implant conditions: a 10-year prospective study. *Clin Oral Implants Res*, 15, 1-7.
- Kero, T., Söderberg, R., Andersson, M., & Lindkvist, L. (2007) Process optimization regarding geometrical variation and sensitivity involving dental drill- and implant-guided surgeries. *Int J Biomed Sci* 2007;4:237-43.
- Kero, T. (2008) Managing the effect of manufacturing variation in medical treatments. Göteborg : Chalmers University of Technology. ISBN/ISSN: 1652-9243
- Lang, N. P., Wetzel, A. C., Stich, H. & Caffesse, R. G. (1994) Histologic probe penetration in healthy and inflamed peri-implant tissues. *Clin Oral Implants Res*, 5, 191-201.
- Lang, N. P., Wilson, T. G. & Corbet, E. F. (2000) Biological complications with dental implants: their prevention, diagnosis and treatment. *Clin Oral Implants Res*, 11 Suppl 1, 146-55.
- Lekholm, U. & Zarb, G.A. (1985) Patient selection and preparation. In: Brånemark, P.-I., Zarb, G.A., Albrektsson, T., eds. *Tissue Integrated Prostheses: Osseointegration in Clinical Dentistry*, 199–209. Chicago: Quintessence Publ Co.
- Lekholm, U., Adell, R., Lindhe, J., Branemark, P. I., Eriksson, B., Rockler, B., Lindvall, A. M. & Yoneyama, T. (1986) Marginal tissue reactions at osseointegrated titanium fixtures. (II) A cross-sectional retrospective study. *Int J Oral Maxillofac Surg*, 15, 53-61.
- Lekholm, U., Grondahl, K. & Jemt, T. (2006) Outcome of oral implant treatment in partially edentulous jaws followed 20 years in clinical function. *Clin Implant Dent Relat Res*, 8, 178-86.
- Leonhardt, A., Berglundh, T., Ericsson, I. & Dahlen, G. (1992) Putative periodontal pathogens on titanium implants and teeth in experimental gingivitis and periodontitis in beagle dogs. *Clin Oral Implants Res*, 3, 112-9.
- Lindquist, L. W., Carlsson, G. E. & Jemt, T. (1996) A prospective 15-year follow-up study of mandibular fixed prostheses supported by osseointegrated implants. Clinical results and marginal bone loss. *Clin Oral Implants Res*, 7, 329-36.
- Lindquist, L. W., Carlsson, G. E. & Jemt, T. (1997) Association between marginal bone loss around osseointegrated mandibular implants and smoking habits: a 10-year follow-up study. *J Dent Res*, 76, 1667-74.
- Loubele, M., Bogaerts, R., Van Dijk, E., Pauwels, R., Vanheusden, S., Suetens, P., Marchal, G., Sanderink, G. & Jacobs, R. (2009) Comparison between effective radiation dose of CBCT and MSCT scanners for dentomaxillofacial applications. *Eur J Radiol*, 71, 461-8.

- Ludlow, J. B., Davies-Ludlow, L. E. & Brooks, S. L. (2003) Dosimetry of two extraoral direct digital imaging devices: NewTom cone beam CT and Orthophos Plus DS panoramic unit. *Dentomaxillofac Radiol*, 32, 229-34.
- Ludlow, J. B., Davies-Ludlow, L. E., Brooks, S. L. & Howerton, W. B. (2006) Dosimetry of 3 CBCT devices for oral and maxillofacial radiology: CB Mercuray, NewTom 3G and i-CAT. *Dentomaxillofac Radiol*, 35, 219-26.
- Ludlow, J. B. & Ivanovic, M. (2008) Comparative dosimetry of dental CBCT devices and 64-slice CT for oral and maxillofacial radiology. *Oral Surg Oral Med Oral Pathol Oral Radiol Endod*, 106, 106-14.
- Luterbacher, S., Mayfield, L., Bragger, U. & Lang, N. P. (2000) Diagnostic characteristics of clinical and microbiological tests for monitoring periodontal and peri-implant mucosal tissue conditions during supportive periodontal therapy (SPT). *Clin Oral Implants Res*, 11, 521-9.
- Maes, F., Collignon, A., Vandermeulen, D., Marchal, G. & Suetens, P. (1997) Multimodality image registration by maximization of mutual information. *IEEE Trans Med Imaging*, 16, 187-98.
- Malo, P., De Araujo Nobre, M. & Lopes, A. (2007) The use of computer-guided flapless implant surgery and four implants placed in immediate function to support a fixed denture: preliminary results after a mean follow-up period of thirteen months. *J Prosthet Dent*, 97, S26-34.
- Marchack, C. B. (2005) An immediately loaded CAD/CAM-guided definitive prosthesis: a clinical report. *J Prosthet Dent*, 93, 8-12.
- Meredith, N., Alleyne, D. & Cawley, P. (1996) Quantitative determination of the stability of the implant-tissue interface using resonance frequency analysis. *Clin Oral Implants Res*, 7, 261-7.
- Meredith, N., Book, K., Friberg, B., Jemt, T. & Sennerby, L. (1997) Resonance frequency measurements of implant stability in vivo. A cross-sectional and longitudinal study of resonance frequency measurements on implants in the edentulous and partially dentate maxilla. *Clin Oral Implants Res*, 8, 226-33.
- Miyazaki, T., Hotta, Y., Kunii, J., Kuriyama, S. & Tamaki, Y. (2009) A review of dental CAD/CAM: current status and future perspectives from 20 years of experience. *Dent Mater J*, 28, 44-56.
- Mombelli, A., Muhle, T., Bragger, U., Lang, N. P. & Burgin, W. B. (1997) Comparison of periodontal and peri-implant probing by depth-force pattern analysis. *Clin Oral Implants Res*, 8, 448-54.
- Mormann, W. H., Brandestini, M., Lutz, F. & Barbakow, F. (1989) Chairside computer-aided direct ceramic inlays. *Quintessence Int*, 20, 329-39.
- Mouhyi, J., Dohan Ehrenfest, D. M. & Albrektsson, T. (2009) The Peri-Implantitis: Implant Surfaces, Microstructure, and Physicochemical Aspects. *Clin Implant Dent Relat Res*.
- Mozzo, P., Procacci, C., Tacconi, A., Martini, P. T. & Andreis, I. A. (1998) A new volumetric CT machine for dental imaging based on the cone-beam technique: preliminary results. *Eur Radiol*, 8, 1558-64.
- Neugebauer, J., Ritter, L., Kistler, F., Kistler, S., Bayer, G., Möller, F., Mischkowski, R. & Zöller J. (2010) Navigated implant placement: What next? *European Journal for Dental Implantologists*, Issue 1, vol.6, 64-67

- Nkenke, E., Eitner, S., Radespiel-Troger, M., Vairaktaris, E., Neukam, F. W. & Fenner, M. (2007) Patient-centred outcomes comparing transmucosal implant placement with an open approach in the maxilla: a prospective, non-randomized pilot study. *Clin Oral Implants Res*, 18, 197-203.
- Östman, P. O. (2008) Immediate/early loading of dental implants. Clinical documentation and presentation of a treatment concept. *Periodontol 2000*, 47, 90-112.
- Östman, P. O., Hellman, M. & Sennerby, L. (2005) Direct implant loading in the edentulous maxilla using a bone density-adapted surgical protocol and primary implant stability criteria for inclusion. *Clin Implant Dent Relat Res*, 7 Suppl 1, S60-9.
- Ozan, O., Turkyilmaz, I., Ersoy, A. E., Mcglumphy, E. A. & Rosenstiel, S. F. (2009) Clinical accuracy of 3 different types of computed tomography-derived stereolithographic surgical guides in implant placement. *J Oral Maxillofac Surg*, 67, 394-401.
- Persson A (2008), Ph.D. thesis, Virtual three-dimensional analysis of digitized dental impressions and stone replicas. Stockholm, Karolinska Institutet
ISBN: 978-91-7409-084-0
- Piattelli, A., Corigliano, M., Scarano, A., Costigliola, G. & Paolantonio, M. (1998) Immediate loading of titanium plasma-sprayed implants: an histologic analysis in monkeys. *J Periodontol*, 69, 321-7.
- Pikner, S. S., Grondahl, K., Jemt, T. & Friberg, B. (2009) Marginal bone loss at implants: a retrospective, long-term follow-up of turned Branemark System implants. *Clin Implant Dent Relat Res*, 11, 11-23.
- Pjetursson, B. E., Karoussis, I., Burgin, W., Bragger, U. & Lang, N. P. (2005) Patients' satisfaction following implant therapy. A 10-year prospective cohort study. *Clin Oral Implants Res*, 16, 185-93.
- Pontoriero, R., Tonelli, M. P., Carnevale, G., Mombelli, A., Nyman, S. R. & Lang, N. P. (1994) Experimentally induced peri-implant mucositis. A clinical study in humans. *Clin Oral Implants Res*, 5, 254-9.
- Priest, G. (2005) Virtual-designed and computer-milled implant abutments. *J Oral Maxillofac Surg*, 63, 22-32.
- Quirynen, M., Van Steenberghe, D., Jacobs, R., Schotte, A. & Darius, P. (1991) The reliability of pocket probing around screw-type implants. *Clin Oral Implants Res*, 2, 186-92.
- Rocci, A., Martignoni, M., Burgos, P. M., Gottlow, J. & Sennerby, L. (2003) Histology of retrieved immediately and early loaded oxidized implants: light microscopic observations after 5 to 9 months of loading in the posterior mandible. *Clin Implant Dent Relat Res*, 5 Suppl 1, 88-98.
- Sandberg, G., Stenberg, T. & Wikblad, K. (2000) Ten years of patients' experiences with fixed implant-supported prostheses. *J Dent Hyg*, 74, 210-8.
- Sanna, A. M., Molly, L. & Van Steenberghe, D. (2007) Immediately loaded CAD-CAM manufactured fixed complete dentures using flapless implant placement procedures: a cohort study of consecutive patients. *J Prosthet Dent*, 97, 331-9.
- Schneider, D., Marquardt, P., Zwahlen, M. & Jung, R. E. (2009) A systematic review on the accuracy and the clinical outcome of computer-guided template-based implant dentistry. *Clin Oral Implants Res*, 20 Suppl 4, 73-86.

- Schnitman, P. A., Wohrle, P. S. & Rubenstein, J. E. (1990) Immediate fixed interim prostheses supported by two-stage threaded implants: methodology and results. *J Oral Implantol*, 16, 96-105.
- Schnitman, P. A., Wohrle, P. S., Rubenstein, J. E., Dasilva, J. D. & Wang, N. H. (1997) Ten-year results for Branemark implants immediately loaded with fixed prostheses at implant placement. *Int J Oral Maxillofac Implants*, 12, 495-503.
- Schou, S., Holmstrup, P., Stoltze, K., Hjorting-Hansen, E., Fiehn, N. E. & Skovgaard, L. T. (2002) Probing around implants and teeth with healthy or inflamed peri-implant mucosa/gingiva. A histologic comparison in cynomolgus monkeys (*Macaca fascicularis*). *Clin Oral Implants Res*, 13, 113-26.
- Schulze, D., Heiland, M., Thurmman, H. & Adam, G. (2004) Radiation exposure during midfacial imaging using 4- and 16-slice computed tomography, cone beam computed tomography systems and conventional radiography. *Dentomaxillofac Radiol*, 33, 83-6.
- Sennerby, L., Persson, L. G., Berglundh, T., Wennerberg, A. & Lindhe, J. (2005) Implant stability during initiation and resolution of experimental periimplantitis: an experimental study in the dog. *Clin Implant Dent Relat Res*, 7, 136-40.
- Serino, G. & Strom, C. (2009) Peri-implantitis in partially edentulous patients: association with inadequate plaque control. *Clin Oral Implants Res*, 20, 169-74.
- Siessegger, M., Schneider, B. T., Mischkowski, R. A., Lazar, F., Krug, B., Klesper, B. & Zoller, J. E. (2001) Use of an image-guided navigation system in dental implant surgery in anatomically complex operation sites. *J Craniomaxillofac Surg*, 29, 276-81.
- Soballe, K., Hansen, E. S., Brockstedt-Rasmussen, H. & Bunger, C. (1993) Hydroxyapatite coating converts fibrous tissue to bone around loaded implants. *J Bone Joint Surg Br*, 75, 270-8.
- Suomalainen, A., Kiljunen, T., Kaser, Y., Peltola, J. & Kortensniemi, M. (2009) Dosimetry and image quality of four dental cone beam computed tomography scanners compared with multislice computed tomography scanners. *Dentomaxillofac Radiol*, 38, 367-78.
- Szmukler-Moncler, S., Salama, H., Reingewirtz, Y. & Dubruille, J. H. (1998) Timing of loading and effect of micromotion on bone-dental implant interface: review of experimental literature. *J Biomed Mater Res*, 43, 192-203.
- Testori, T., Szmukler-Moncler, S., Francetti, L., Del Fabbro, M., Trisi, P. & Weinstein, R. L. (2002) Healing of Osseotite implants under submerged and immediate loading conditions in a single patient: a case report and interface analysis after 2 months. *Int J Periodontics Restorative Dent*, 22, 345-53.
- Truhlar, R. S., Morris, H. F. & Ochi, S. (1993) A review of panoramic radiography and its potential use in implant dentistry. *Implant Dent*, 2, 122-30.
- Van De Velde, T., Glor, F. & De Bruyn, H. (2008) A model study on flapless implant placement by clinicians with a different experience level in implant surgery. *Clin Oral Implants Res*, 19, 66-72.
- Van Steenberghe, D., Glauser, R., Blomback, U., Andersson, M., Schutyser, F., Pettersson, A. & Wendelhag, I. (2005) A computed tomographic scan-derived customized surgical template and fixed prosthesis for flapless surgery and immediate loading of implants in fully edentulous maxillae: a prospective multicenter study. *Clin Implant Dent Relat Res*, 7 Suppl 1, S111-20.

- Van Steenberghe, D., Klinge, B., Linden, U., Quirynen, M., Herrmann, I. & Garpland, C. (1993) Periodontal indices around natural and titanium abutments: a longitudinal multicenter study. *J Periodontol*, 64, 538-41.
- Van Steenberghe, D., Molly, L., Jacobs, R., Vandekerckhove, B., Quirynen, M. & Naert, I. (2004) The immediate rehabilitation by means of a ready-made final fixed prosthesis in the edentulous mandible: a 1-year follow-up study on 50 consecutive patients. *Clin Oral Implants Res*, 15, 360-5.
- Yong, L.T. & Moy, P.K. (2008) Complications of computer-aided-design / computer-aided-machining-guided (NobelGuide) surgical implant placement: an evaluation of early clinical results. *Clin Implant Dent Relat Res*, 10, 123-7.
- Zarb GA, Albrektsson T. Osseointegration — a requiem for the periodontal ligament? *Int J Periodontics Restorative Dent* 1991; 11(1):88–91.
- Zitzmann, N. U., Berglundh, T., Marinello, C. P. & Lindhe, J. (2001) Experimental peri-implant mucositis in man. *J Clin Periodontol*, 28, 517-23.