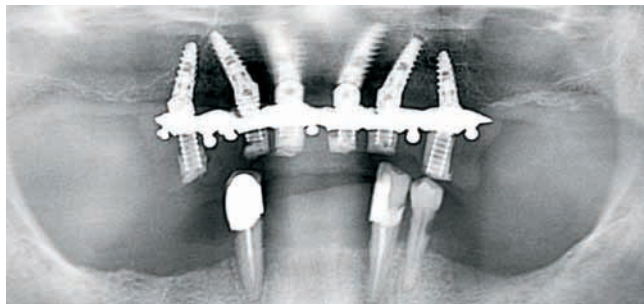


# 23

News No. 23 May 2010

## Immediate Loading in the Complete Edentulous Maxilla- A Clinical Case

- Using MIS Multi-Unit Abutments



**MIS**<sup>®</sup>  
Make it Simple



# Immediate Loading in the Complete Edentulous Maxilla

## - A Clinical Case

<sup>1</sup>Dr Jean Koskievic | Saint Antoine Hospital (Paris)

The development of oral implantology has allowed for the creation of a new discipline pertaining to odonto-stomatology, with treatment procedures that are now well codified, predictable and reproducible with great success rates. These protocols involve implant loading in a two-stage surgical procedure.<sup>1-3</sup>

### 1. Delayed Versus Immediate Loading

Schnitman et al.<sup>4</sup> proved that immediate loading is a viable technique when applied to the mandible. Surgical and prosthetic success rates have been found close to that of delayed loading.

A protocol of immediate bi-maxillary loading has been described by Tarnow et al.<sup>5</sup> Brånemark et al.<sup>6</sup> published the first results of a new concept, the Brånemark Novum®. This concept enables accurate pre-positioning, with the help of surgical templates. In the symphyseal region, 3 implants are placed pre-operatively in a three-space plane and connected between each other by a prefabricated rigid connection rod. A second rod, supporting a fixed prosthesis made of acrylic resin, is received in a second stage occurring not later than 24 to 48 hours. This study corroborated by another 18-month clinical research by Randow et al.<sup>7</sup> concludes that this treatment is only reliable if the implants are positioned between both chin foramina. In a 5-year study on 16 patients and 88 interforaminal implants placed in the edentulous mandible, Ericsson et al.<sup>8</sup> have shown that by using a rigid prosthetic device, the bone resorption rate around the implemented implants within 20 days is identical to that of implants implemented at 4 months. The first results at the end of the Novum protocol presented interesting success rates. Van Steenberghe et al.<sup>9</sup> conducted a study over a longer period and found an approximate survival rate of 90% after 5 years vs. a 99%

success rate 15 years later for the fixed prostheses implemented on Brånemark System® implants after osseointegration during 3 months<sup>10</sup> in the symphyseal region.

The Hong Kong bridge<sup>11</sup> reduces the number of implants placed in the symphysis to 4 and allows immediate insertion of the prosthesis. The implant success rate is 98.3%. Other studies<sup>12-14</sup> confirm that immediate loading of 4 implants placed in the symphysis and made jointly liable to the mandible of complete edentulous patients, is a reliable, reproducible and predictable method when using a rigid overdenture.

A retrospective clinical study<sup>15</sup> has been conducted on 44 patients and 176 implants using a new protocol of immediate loading (All-on-Four). This consists of inserting 4 long implants (2 distally angled) in the symphysis by using several 40 N/cm in patients with an edentulous mandible. By distally angling these implants, the authors hoped to decrease the forces acting on the cantilevers of the acrylic complete mandibular prosthesis mounted on the rigid intrados and screwed to these implants by angled multi-unit pillars and specific fixtures within less than 2 hours. A cumulative survival rate of 96.7% was recorded for implants and a success rate of 100% for prostheses. In a later study<sup>16</sup> by the same authors, a cumulative survival rate of 97.6% was found for the maxilla. It has been confirmed that the distal angulation of implants made jointly liable by a fixed prosthetic element supporting a cantilever does not increase the bone strains with regard to vertically inserted implants.<sup>17</sup>

### 2. Computer-Aided Planning and Implant Modeling

Computer-aided, scan-derived planning and implant modeling established by stereolithography have resulted in the development

of new treatment protocols. Under certain conditions, these protocols reduce the number of implants needed for stabilizing prostheses, either provisory or definitive, and enable immediate implant loading with accuracy while decreasing treatment time and costs. These protocols require a surgical template made from a predefined prosthetic device.

In 1994, the Matérialise® Company developed a software program that could carry out scan-derived implant simulations, as well as a quantitative and qualitative study of the implant sites. A surgical drill template (guide), which uses stereo-lithographical modeling (SurgiGuide®), was then created. This resulted in a complete system of data analysis and execution of surgical templates compatible with all implant trademarks (Simplant®). This surgical template allows accurate repositioning of the implants in the bone.

In 2002, following the research of Verstreken et al.<sup>18,19</sup> and Jacobs et al.,<sup>20</sup> Van Steenberghe et al.<sup>21,22</sup> conducted a study on two cadavers and later on eight patients that proved that the transfer of CT results to the patient using computer-aided surfing, allows for extremely accurate development of a surgical drill template. This procedure also enables positioning of a fixed prosthesis while limiting the freedom of movement between the metallic pillars and cylinders incorporated in the prosthesis.

In a prospective multi-center study conducted on 24 patients with edentulous maxilla under one-year follow-up, Van Steenberghe et al.<sup>23</sup> proposed a new concept called "Teeth-in-One-Hour". Its protocol, based on computer-aided 3D planning, allows insertion of implants using a surgical template with mucous support (flapless technique) and implements a complete trans-screwed rigid prosthesis immediately after surgery. A 100% survival rate was shown for the implants and identical success rate for the prostheses.

### Today, three types of surgical templates are used:

-Surgical template with bone support: the template is positioned on the patient's bone during surgery. It is intended for partially or completely edentulous patients and allows for observing the surgical procedure by relying on the residual bone. This ensures better accuracy for template positioning. This surgery involves flaps.

-Surgical template with mucous support: the template is positioned on the patient's soft tissues during surgery. It is intended for patients with completely edentulous mandibles or maxillas for a non-invasive ("flapless") surgery.

-Surgical template with dental-mucous support: the template is positioned directly on the teeth present on the arch during surgery. It is intended for partial edentulous patients, either unitary or plural, when flapless or other surgery, is not desired.

### 3. Indications and Contra-indications

Only ASA1 or ASA2 patients should be selected. Moreover, first selection relies on motivation and understanding of treatment planning, as well as the strict respect of hygiene rules. The patient should be informed of the proposed treatment plan and of the required healing periods and controls.

-Clinical extra- and intra-oral examinations are carried out to develop a treatment plan preceding any surgery. Contra-indications for an immediate loading protocol of this type are the same as for loading in two surgical stages. Residual bone volume in the edentulous region, occlusion type, intermaxillary connections, and periodontium condition should be assessed by the clinician.

The mouth opening should be examined to ensure that the surgical template can be anchored, that there is space for the use of instruments, and for implant insertion. In the flapless technique, a floating ridge may be contra-indicated since it does not provide the guide with good stability. Patients with significant dysfunctions and parafunctions should be excluded from this type of treatment.

-In the selected implant sites, the clinician should assess if residual bone volume and keratinized tissue are present in sufficient quantity and quality. D4 type bone is contra-indicated to this type of treatment.<sup>24</sup>

-Additional radiologic examinations (dental panoramic examination, scanner) and computer-aided 3D simulation validate the feasibility of the proposed treatment plan.

### Should the patient still be without dentures:

Before implant surgery, extraction and curettage of the focus of infection and transplants should

be carried out. The crests should be leveled to obtain a prosthetic groove in the anteroposterior direction, wide enough to insert the implants. Adherences are eliminated. Healing times must be respected. The provisory PAC that comes before the definitive prosthesis should be fabricated. This will validate the occluso-prosthetic space needed for this type of treatment, which requires implementation of different components.

### Should the patient already be fitted with dentures:

The prosthesis should be re-evaluated or replaced since the immediate loading protocol in a complete edentulous maxilla-mandible depends on its validation.

## 4. Presentation Of The Clinical Case

A 67-year-old man consulted for complete rehabilitation of the maxilla and mandible. He presented with a complete edentulous maxilla for which no PAC compensation had been made, and a partial edentulous mandible with three residual teeth (33, 34, 43) and an inadequate PAP. In the maxilla, the clinical examination revealed a keratinized, non-inflammatory gum over the entire edentulous ridge and the absence of residual roots and focuses of infection (Fig. 1).

Residual, irrecoverable teeth (33, 34, 43) were observed in the mandible. Panoramic radiographs in the maxilla revealed the presence of prolapsing sinuses extending up to teeth 13 and 23, thus preventing any axial implant protocol in the posterior region. Pre-implant surgery was required. In the mandible, strong bilateral posterior alveolar resorption with emerging foramens of the chin was observed in front of teeth 34-35 and 44-45 (Fig. 2).

After the patient was informed of the various treatment options, a functional aesthetic bi-maxillary implant-borne rehabilitation was chosen with immediate implant loading, and simultaneous implementation of the trans-screwed provisory prostheses. The decision was made to rehabilitate the maxilla first. In the second-stage, after extraction of the mandibular residual teeth and healing temporization, the mandible was rehabilitated.

Today, implant simulation allows the use of planning software programs to fit patients with dentures on the condition that there is a sufficient bone quantity. This rehabilitation is subjected to protocol.

### Aesthetic assembly of the toothless maxilla (wax up)

The wax prostheses should be mounted before the final functional aesthetic result. Before scanning, the practitioner should examine the vertical dimension of occlusion, the inter-maxillary connection and the occluso-prosthetic space to determine whether the mouth opening is sufficient for a drill template to be used.

Once the assembly is validated, it is sent to the laboratory. A duplicate is made to use as a radio-opaque template (Fig. 3).

### Scanning

During scanning the patient holds the radio-opaque template and bites in centered relation (Fig. 4).

### Examination and interpretation of scans, and computer-aided implant simulation (CAIS)

The scan reveals the accuracy of the anatomic obstacles, and the quality and quantity of the residual alveolar bone (Figs. 5a,b). In the presented case, the Dicom files were sent to the modeling center (Posidental®) for computer-aided simulation (CAIS) (Figs. 6a,b). The CAIS plans the implant installation in 3D and determines the number of implants and their position in the three-space plane. The feasibility of the prosthetic device and selected implants was viewed. The length, diameter, emergence zone and angulation of each implant was recalculated (Figs. 7a,b). Upon request, the modeling center simulated the drill template and metal intrados supporting the provisory resin prosthesis that was made jointly liable to the provisory implant inlay cores (Fig. 8).

In the maxilla, 6 implants (MIS - Medical Implant System) with internal hexagon, angled at 30°, was distributed between both sinuses. Implementation of 6 implants allows support of the rigid resin prosthesis of the "cantilever" type, made jointly liable to the implants in a maxilla bone. This is often of mediocre quality, but brings a better distribution of forces, which remain within admissible physiological limits. The implants were angled at 30° while placed along the sinuses so that their emergence appeared in front of teeth 14 and 24. Four additional implants (12, 11, 21, 22) were also placed at 30° while relying on the hard palate (Fig. 9).

Resistance to the vertical tensile strength was increased when these implants were crossed with the distal ones. The 6 implants received "multi-unit" pillars (MIS - Medical Implant System) angled at 30°, designed to straighten the emergence of the implant axes and recover the parallelism of the titanium trans-screwed provisory inlay cores. This allows insertion of a transitory rigid prosthesis from teeth 15 to 25, made jointly liable to these provisory inlay cores.

The transitory trans-screwed rigid prosthesis is equivalent to an external fixative. It reduces the applied forces transmitted to the implants, which are at the origin of harmful micro-movements to the osseointegration, lessens the "cantilever" effect, and allows for an increased number of teeth on the prosthesis while improving the aesthetic aspect. The CAIS was returned for validation.

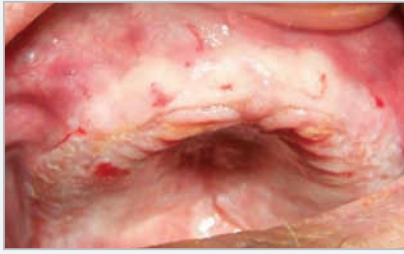

Fig. 1

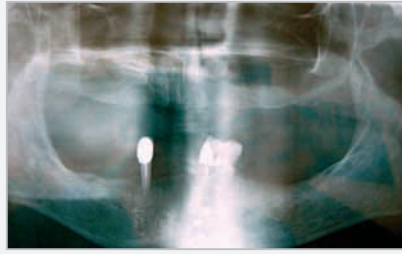

Fig. 2

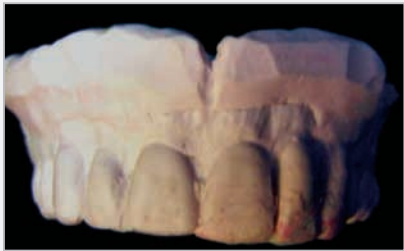


Fig. 3

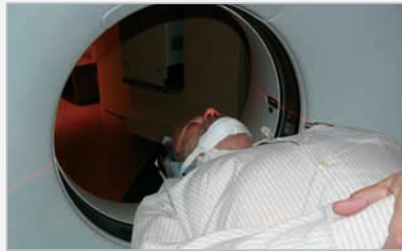

Fig. 4

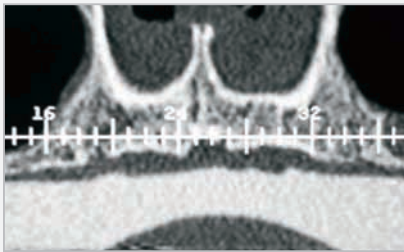


Fig. 5A

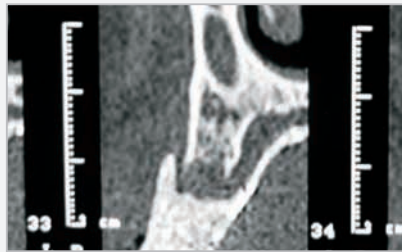


Fig. 5b

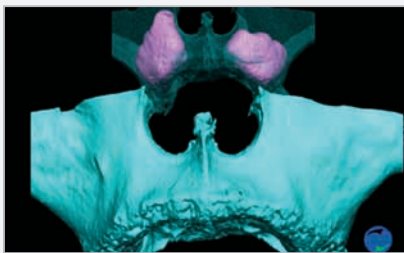


Fig. 6a

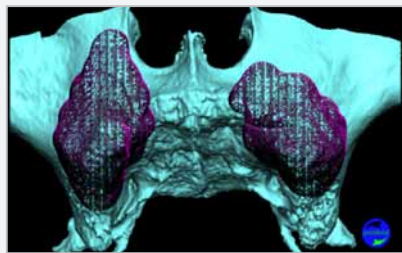


Fig. 6b

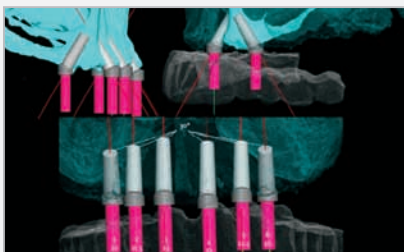


Fig. 7a

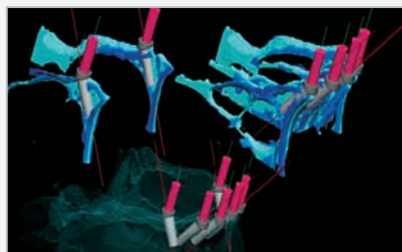


Fig. 7b

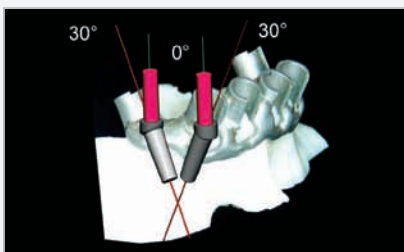


Fig. 8

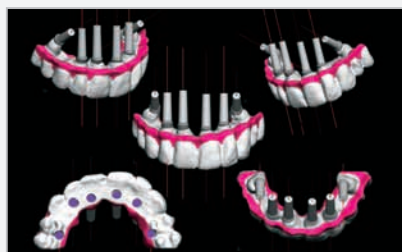


Fig. 9

### Physical validation

The drill template and the provisory resin prosthesis mounted on the metal intrados were produced by the modeling center and sent to the surgeon who physically validated the computer-aided 3D simulation from the stereo-lithographic model (Fig. 10). The surgical steel templates and fittings were sterilized by autoclaving before surgery.

### Implementation of the implants on the maxilla

A main ridge incision that was moved forward to the palatal and two vestibular incisions for unloading, in front of teeth 15 and 25, allowed for mucoperiosteal detachment of the areas to be implanted (Fig. 11). The drill template is usually stabilized on the residual alveolar bone using lateral osseosynthesis screws. However, in this clinical case, the strong undercut presented by the vestibular alveolar bone naturally stabilized the drill template (Fig. 12). At implant sites 12 and 22, pre-drilling was achieved using a pointer, the non-working part of which was fitted with a centering washer with stop (Postitroll®) inserted in the bushing of the drill template.

The drill template was supported on the ridge using self-drilling screws with external irrigation, mounted on a counter-angle and guided by the centering washer inserted in the bushing at implant sites 12 and 22. This locked the drill template (Fig. 13). The drilling sequence was resumed using the pointer in front of sites 11 and 21, continuing with 3 mm (diameter) and 8 mm (length) drills, always fitted with the centering washer with stop that guided the drilling and ended according to the length and diameter selected for each implant. Implants for sites 11 and 21 were placed and locked in the template (Fig. 14).

The implant holders were dismantled and a tightening key, with 6 marks matching the 6 sides of the internal hexagon, was inserted in the implant neck. This key is guided by a calibrated cylinder matching the bushing diameter, thus avoiding any deviation during final tightening of the implant (Fig. 15). When one of these marks match the open window of the bushing, the desired implant positioning is recovered in the required axis and the latter is placed. Another set of calibrated cylinders lock the drill template at implant sites 11 and 21 (Fig. 16) while the operation is renewed for implants 14 and 24, which are installed in turn (Figs. 17a,b). The last drilling sequence allowed positioning of the implants in spaces 12 and 22 (Fig. 18). After all implants were placed, the system was dismantled (Figs. 19a,b).

### Implementation of parallelization of the multi-units and provisory inlay-cores

The parallelization of the 6 provisory inlay-cores needed to insert the prosthesis successfully presents some difficulty. To solve this problem, 6 multi-units (MIS - Medical Implant System)

were interposed between the implants angled at 30° and the provisory inlay-cores. The multi-units are composed of an anti-rotational apical part that is screwed in the implant and a trans-mucous coronary part angled at 30° that allows implant emergence axis to be adjusted. The angled multi-units are provided with a prehension rod that enables insertion into the angled implants while controlling the parallelism. After placement (Fig. 20), titanium inlay cores were trans-screwed in the multi-units (Fig. 21). Parallelism was completely controlled and the flaps were sutured.

### Implementation of the trans-screwed prosthesis

The provisory resin prosthesis (Fig. 22), mounted on the rigid intrados, was made jointly liable to the provisory titanium inlay-cores using a cold self-polymerizable composite. The whole was unscrewed, the intrados of the provisory prosthesis trimmed and repolished, and then re-screwed on the implants using the multi-units (Fig. 23). The occlusion was examined (Fig. 24) and adjustment made using the radiograph (Fig. 25).

### Suture removal and radiographic examination

Sutures were removed at 21 days. Cicatrisation was controlled. The prosthesis was rebased if needed and the occlusion was re-examined. A panoramic radiograph revealed the proper position of all pillars.

### Implementation of the definitive implant-borne prostheses

At 3 months, after control of the osseointegration of the implants, the definitive maxillary prosthesis was implemented (Fig. 26).

## 5. Discussion

It is possible to insert implants while applying a flapless technique with extreme accuracy and using a CAIS-prepared drill template.<sup>21,22</sup> The research is corroborated by a comparative 4-year retrospective multi-center clinical study,<sup>25</sup> which shows that the use of CAIS allows for the insertion of implants using a flapless technique, with success rates identical to those of any conventional technique. Another study<sup>26</sup> has shown that the flapless technique encourages vascularization of the peri-implant mucous membrane around the implant. In an *in vitro* study, Van de Velde et al.<sup>27</sup> indicate that without a drill template, there is drilling deviation when implants are implemented across the mucous membrane. Deviations were found in 59.7% of the patients (43/72), which could lead to a loss of implant stability with phonetic and aesthetic consequences. It was concluded that despite the advantages of the flapless technique, from the viewpoints of pain, morbidity and diminution of surgical operation time, it is necessary to have a more accurate measure of the soft tissues. The use

of guidance systems is recommended.

However, according to Komiyama et al.<sup>28</sup> there are surgical and technical complications in the "flapless" technique. In <sup>29</sup> patients, 176 implants were inserted using the "Nobelguide"™ protocol and immediately applied with a prosthesis prepared in advance (21 in the maxilla; 10 in the mandible). Within 2 to 18 months, 19 implants were lost, with a success rate of 92% in the maxilla and 83% in the mandible. Surgical or technical complications were found in 42% of the treated patients. It was concluded that the surgical flapless protocol was still not scientifically validated.

In the flapless technique, the reliability of the protocol depends on several factors, which are not always under the surgeon's control. Parameters which could be sources of errors are accuracy of the baryta duplicate, scanning quality, and reliability of the CAIS. A study<sup>29</sup> confirms that computer-aided navigation may be a source of errors (average deviation less than 1 mm from the drilling and average deviation less than 4° from the implant axis), but that these errors have no impact in the flapless technique.

The lack of visibility with this technique requires great caution, as well as a technique guided with bone support that allows for the control of the procedure. This seems to be a more reliable approach until consensus is reached. Implementation of angulated implants, with the angle multi-units being introduced into the market, allows for the development of accurate indications, trans-screwed prostheses which can accept cantilevers according to the type of bone found, the length and the number of inserted implants, and the type of implemented prosthesis.

Forces applied on angled implants do not lead to higher bone loss at the marginal bone level than vertically inserted implants. It is now recognized that 4 implants are sufficient in corticalized bone, such as the mandible. In the maxilla, a greater number of implants may be desired for this type of rehabilitation. Then the quality of the residual alveolar bone is important.

## 6. Conclusion

With the development of the computer-aided simulation and 3D modeling, treatment protocols for patients suffering from a complete edentulous maxilla and/or mandible have advanced. It is now possible to carry out immediate implant loading under certain aesthetic functional rehabilitations with reduced time and cost.

The guides with bone support offer greater safety for both patient and surgeon. With implant development and adapted fixtures, this immediate loading technique is open to all types of implants and implant-connecting technology. It allows for a quicker prosthesis implementation with immediate recovered comfort and aesthetics for the patient.

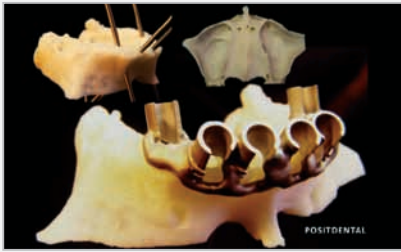

Fig. 10

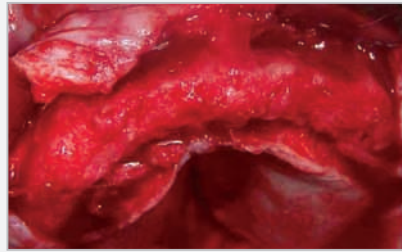


Fig. 11

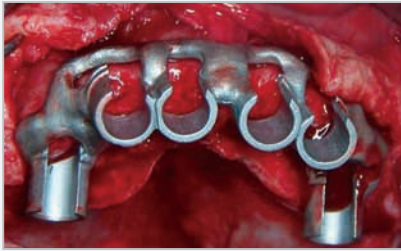


Fig. 12

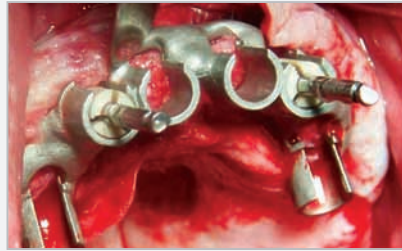


Fig. 13

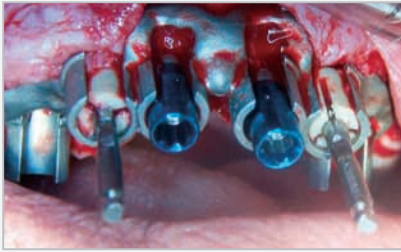

Fig. 14

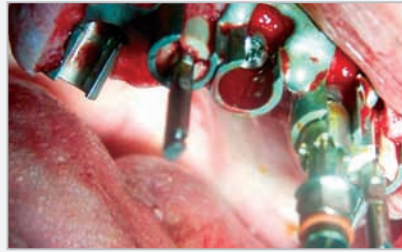

Fig. 15

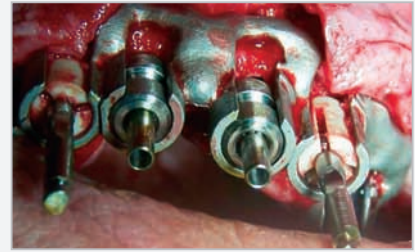

Fig. 16

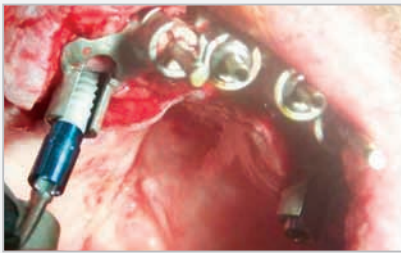

Fig. 17a

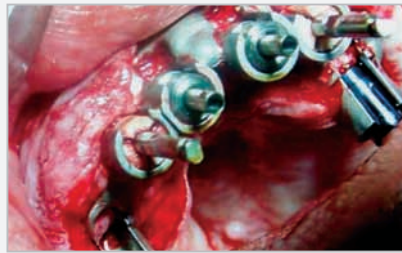


Fig. 17b

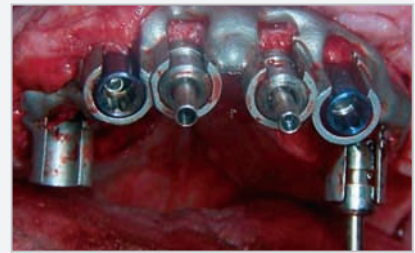


Fig. 18

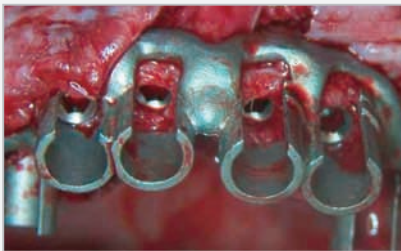

Fig. 19a

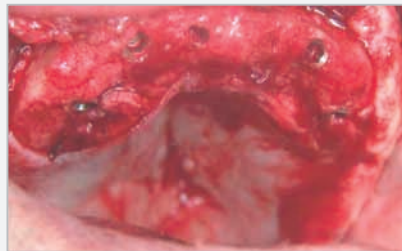


Fig. 19b

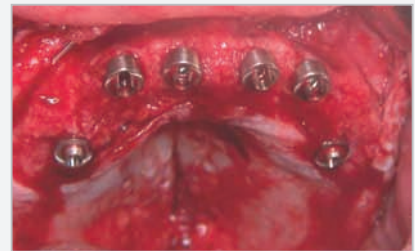


Fig. 20

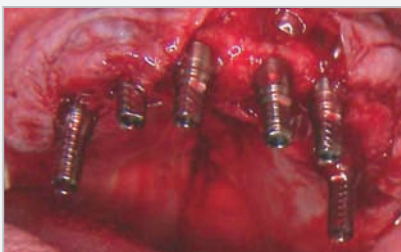


Fig. 21

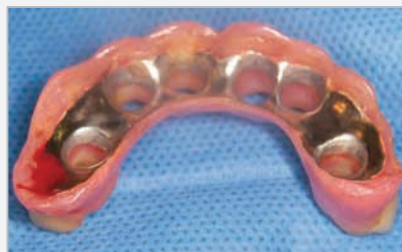

Fig. 22

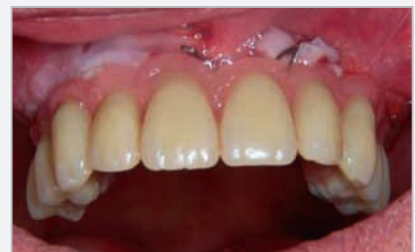

Fig. 23

However, it is still necessary to improve the procedures of computer-aided implant simulation (CAIS), of template manufacturing, and supra-implant connecting technology to validate immediate loading in a complete edentulous maxilla with terminal atrophy of the alveolar bones in the posterior region.

The guides with mucous support reinforce the therapeutic arsenal that is available for the practitioner. The surgical intervention is certainly improved while evading the post-surgical problems (pains and edema) but, to our mind, there is the disadvantage, of being committed to a particular implant system.

Immediate loading of the edentulous maxilla with a drill template, using either a flapless or flap procedure, requires specially trained qualified surgeons for this kind of technique.

## Bibliography

- Adell R, Lekholm U, Rockler B. A 15-year study of osseointegrated implants in the treatment of the edentulous jaw. *J Oral Surg* 1981;10:387-416.
- Brånemark P-I, Breine U, et al. Intraosseous anchorage of dental prostheses. Part I: Experimental studies. *Scand J Plast Reconstr Surg Hand Surg* 1969;3:81-100.
- Brånemark P-I, Hansson BO, et al. Osseointegrated implants in the treatment of the edentulous jaw. Experience from a 10-year study period. *Scand J Plast Reconstr Surg* 1977;16:1-132.
- Schnitman PA, Wohrle PS, Rubenstein JE. Immediate fixed interim prostheses supported by two-stage threaded implants: methodology and results. *J Oral Implantol* 1990;16(2):96-105.
- Tarnow DP, Emtiaz S, Classi A. Immediate loading of threaded implants at stage 1. Surgery in edentulous arches: ten consecutive case reports with 1 to 5 year data. *Int J Oral Maxillofac Implants* 1997;12:319-324.
- Brånemark PI, Engstrad P, et al. Brånemark Novum, A new treatment concept for rehabilitation of the edentulous mandible. Preliminary results from a prospective clinical follow-up study. *Clin Implant Dent Relat Res* 1999;1(1):2-16.
- Random K, Ericsson I, et al. Immediate function loading of Brånemark dental implants. An 18 month study. *Clin Oral Implant Res* 1999;10:8-15.
- Ericsson I, Random K, Nilner K, Peterson A. Early functional loading of Brånemark dental implants: 5-year clinical follow-up study. *Clin Implant Dent Relat Res* 2000;2(2):70-77.
- Van Steenberghe D, Molly L, Jacobs R, Vandekerckhove B, Quirynen M, Naert I. The immediate rehabilitation by means of a ready-made final prosthesis in the edentulous mandible: a 1-year follow-up study on 50 consecutive patients. *Clin Oral Implants Res* 2004;15: 360-365.
- Lindquist LW, Carlsson GE, Jemt T. A prospective 15-year follow-up study of mandibular fixed prostheses supported by osseointegrated implants. Clinical results and marginal bone loss. *Clin Oral Implants Res* 1996;7(4):329-336.
- Chow J, Hui E, Liu J, et al. The Hong Kong Bridge Protocol. Immediate loading of mandibular Brånemark fixtures using a fixed provisional prosthesis: preliminary results. *Clin Implant Dent Relat Res* 2001;3(3):166-174.
- Balshi SF, Wolfinger GJ, Balshi TJ. A prospective study of immediate functional loading, following the Teeth in a Day protocol: a case series of 55 consecutive edentulous maxillae. *Clin Implant Dent Relat Res* 2005;7(1):24-31.
- Attard NJ, Zarb GA. Immediate and early implant loading protocols: a literature review of clinical studies. *J Prosthet Dent* 2005;94(3):242-258. Review.
- Degidi M, Piattelli A, Iezzi G, Carinci F. Retrospective study of 200 immediately loaded implants retaining 50 mandibular overdentures. *Quintessence Int* 2007; 38(4):281-288.
- Maló P, Rangert B, Nobre M. "All-on-Four" immediate-function concept with Brånemark System implants for completely edentulous mandibles: a retrospective clinical study. *Clin Implant Dent Relat Res* 2003;5(Suppl 1):2-9.
- Maló P, Rangert B, Nobre M. "All-on-Four" immediate-function concept with Brånemark System implants for completely edentulous maxillae: a 1-year retrospective clinical study. *Clin Implant Dent Relat Res* 2005;7(Suppl 1):S88-S94.
- Zamplais A, Rangert B, Heijl L. Tilting of splinted implants for improved prosthodontic support: a two-dimensional finite element analysis. *J Prosthet Dent* 2007;97(Suppl 6):S35-S43.
- Verstreken K, Van Cleynenbreugel J, Marchal G, et al. Computer-assisted planning of oral implant surgery: a three-dimensional approach. *Int J Oral Maxillofac Implants* 1996;11(6):806-810.
- Verstreken K, Van Cleynenbreugel J, Martens K, Marchal G, van Steenberghe D, Suetens P. An image-guided planning system for endosseous oral implants. *IEEE Trans Med Imaging* 1998;17(5):842-852.
- Jacobs R, Adriansens A, Verstreken K, Suetens P, van Steenberghe D. Predictability of a three-dimensional planning system for oral implant surgery. *Dentomaxillofac Radiol* 1999;28(2):105-111.
- Van Steenberghe D, Naert I, Andersson M, Brajnovic I, Van Cleynenbreugel J, Suetens P. A custom template and definitive prosthesis allowing immediate implant loading in the maxilla: a clinical report. *Int J Oral Maxillofac Implants* 2002;17(5):663-670.
- Van Steenberghe D, Malevez C, Van Cleynenbreugel J, et al. Accuracy of drilling guides for transfer from three-dimensional CT-based planning to placement of zygoma implants in human cadavers. *Clin Oral Implants Res* 2003;14(1):131-136.
- Van Steenberghe D, Glauser R, Blombäck U, et al. A computed tomographic scan-derived customized surgical template and fixed prosthesis for flapless surgery and immediate loading of implants in fully edentulous maxillae: a prospective multicenter study. *Clin Implant Dent Relat Res* 2005;7(Suppl 1): S111-S120.
- Misch CE. Bone classification, training keys to implant success. *Dent Today* 1989;8(4):39-44.
- Berdougo M, Fortin T, Blanchet E, Isidori M, Bosson JL. Flapless implant surgery using an image-guided system. A 1- to 4-year retrospective multicenter comparative clinical study. *Clin Implant Dent Relat Res* 2009; Feb 13 (Epub).
- Kim JI, Choi BH, Li J, Xuan F, Jeong SM. Blood vessels of the peri-implant mucosa: a comparison between flap and flapless procedures. *Oral Surg, Oral Med, Oral Pathol, Oral Radiol, Endod* 2009;107(4):508-512. Epub 2008 Oct 16.
- Van de Velde T, Glor F, De Bruyn H. A model study on flapless implant placement by clinicians with a different experience level in implant surgery. *Clin Oral Implants Res* 2008;19(1):66-72.
- Komiyama A, Klinge B, Hutin M. Treatment outcome of immediately loaded implants installed in edentulous jaws following computer-assisted virtual treatment planning and flapless surgery. *Clin Oral Implants Res* 2008;19(7):677-685.
- Elian N, Jalbout ZN, Classi AJ, Wexler A, Sarment D, Tarnow DP. Precision of flapless implant placement using real-time surgical navigation: a case series. *Int J Oral Maxillofac Implants* 2008;23(6):1123-1127.

### Acknowledgements:

-POSITIDENTAL France  
-MIS Israel

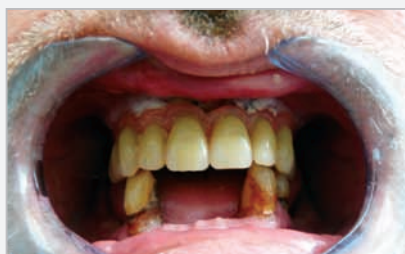

Fig. 24

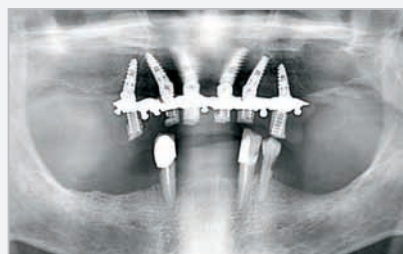

Fig. 25

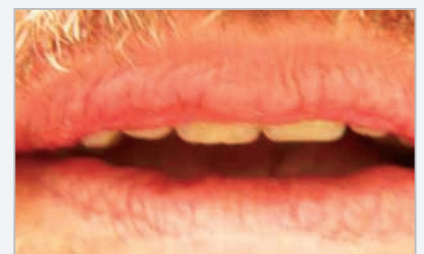


Fig. 26

MIS's Quality System complies with international quality standards: ISO 13485:2003 - Quality Management System for Medical Devices, ISO 9001: 2008 – Quality Management System and CE Directive for Medical Devices 93/42/EEC. MIS's products are cleared for marketing in the USA and CE approved.

© MIS Corporation. All rights Reserved.



MIS Implants Technologies Ltd.  
[www.mis-implants.com](http://www.mis-implants.com)