

**THE PERI-IMPLANT TISSUES
FROM AN ESTHETIC PERSPECTIVE**

Moontaek Chang

Department of Periodontology
Institute of Odontology
The Sahlgrenska Academy



UNIVERSITY OF GOTHENBURG

2009

In memory of my mother and father

Contents

| | |
|----------------------------|----|
| ABSTRACT | 6 |
| PREFACE | 7 |
| INTRODUCTION | 8 |
| AIMS | 29 |
| MATERIAL AND METHODS | 30 |
| Subject samples | 30 |
| Ethical approval | 31 |
| Implant treatment | 31 |
| Assessments | 33 |
| Error of methods | 40 |
| Data analyses | 41 |
| RESULTS & DISCUSSION | 43 |
| <i>Study I</i> | 43 |
| <i>Study II</i> | 46 |
| <i>Study III</i> | 49 |
| <i>Study IV</i> | 51 |
| <i>Study V</i> | 53 |
| MAIN CONCLUSIONS | 56 |
| CONCLUDING REMARKS | 57 |
| REFERENCES | 58 |
| APPENDIX | 68 |
| I. Questionnaires | |
| II. Study I-V | |

ABSTRACT

The peri-implant tissues from an esthetic perspective

Moontaek Chang

Department of Periodontology, Institute of Odontology, The Sahlgrenska Academy at
University of Gothenburg, Box 450, SE 405 30 Göteborg, Sweden

The overall objective of the thesis was to evaluate the dimensions and position of peri-implant soft tissues in relation to the topography and alterations of the bone support, and the tissues' significance for an esthetic appreciation of implant therapy.

A comparative evaluation of crown and soft tissue dimensions between implant-supported single-tooth replacements and the contra-lateral natural tooth was made in *Study I*. In *Study II*, patients' and dentists' judgment of the esthetic outcome of implant-supported single-tooth replacements was assessed and compared by means of a questionnaire in which various esthetic-related variables were addressed. Longitudinal changes in tooth/implant relationship and bone topography adjacent to single implants with a micro-threaded, conical marginal part were evaluated in *Study III*. In *Study IV*, bone alterations around implants with a conical implant-abutment interface were evaluated longitudinally in relation to implant-tooth and inter-implant distances. Furthermore, peri-implant soft and hard tissue alterations from the time of implant placement were longitudinally evaluated in a 3-year prospective study involving patients receiving implant-supported fixed partial dentures (*Study V*).

Despite differences in clinical crown height and soft tissue topography between the implant-supported single-tooth replacement and the contra-lateral natural tooth (*Study I*), patients' satisfaction with the appearance of their single implant-supported crown restoration was high, whereas prosthodontists rated the esthetic outcome significantly lower (*Study II*). Soft tissues topography and crown form influenced the dentists' overall satisfaction with the esthetic appearance, while no specific factors could be identified with regard to the patients' satisfaction. Hence, factors considered by professionals to be of significance for the esthetic result of restorative treatment may not be of decisive importance for the patient. The marginal bone level at the teeth adjacent to single implants with a micro-threaded conical marginal part was not influenced by the horizontal or vertical tooth-implant distance (*Study III*). Observed continuous eruption of the adjacent teeth with infra-occlusal positioning of the implant restoration might cause esthetic dissatisfaction. Loss in the bone crest height in the inter-implant areas was influenced by bone loss at bordering implants and horizontal inter-unit distance, but no such relationship was proven for the proximal area between the implant and the tooth (*Study IV*). Soft and hard tissue changes around implant-supported fixed partial dentures took place primarily during the first 6 months after the one-stage implant installation surgery (*Study V*). Significant explanatory factors for the loss in proximal bone crest height at 3 years were horizontal inter-unit distance and peri-implant bone level change. The presence of a tooth next to the implant had a positive influence on the topography of the inter-unit soft tissues and the maintenance of the proximal bone crest level.

Keywords: clinical, dental implants, esthetics, single-tooth replacements, soft tissues, infra-occlusion, bone alterations

ISBN: 978-91-628-7837-5

Preface

The present thesis is based on the following studies, which will be referred to in the text by their Roman numerals:

- I. Moontaek Chang, Jan L. Wennström, Per A. Ödman & Bernt Andersson (1999) Implant supported single-tooth replacements compared to contralateral natural teeth: Crown and soft tissue dimensions. *Clinical Oral Implants Research* 10: 185-194.
- II. Moontaek Chang, Per A. Ödman, Jan L. Wennström & Bernt Andersson (1999) Esthetic outcome of implant-supported single-tooth replacements assessed by the patient and prosthodontists. *International Journal of Prosthodontics* 12: 335-341.
- III. Moontaek Chang & Jan L. Wennström (2009) Longitudinal changes in tooth/single-implant relationship and bone topography. An 8-year study. *Manuscript*.
- IV. Moontaek Chang & Jan L. Wennström (2009) Peri-implant bone alterations in relation to inter-unit distances. A 5-year longitudinal study of implant-supported FPDs. *Clinical Oral Implants Research (Submitted)*.
- V. Moontaek Chang & Jan L. Wennström (2009) Peri-implant soft tissue and bone crest alterations at fixed partial dentures: A 3-year prospective study. *Clinical Oral Implants Research (Submitted)*.

Permission for reprinting the papers published in the journals *Clinical Oral Implants Research* and *International Journal of Prosthodontics* was given by Blackwell Munksgaard and Quintessence Publishing (copyright holders).

INTRODUCTION

The position of the facial soft tissue margin and the degree of soft tissue fill in the embrasure spaces lateral to implant-supported crowns are factors of concern in relation to the esthetic appreciation of implant-supported prostheses. Independent of implant geometry and insertion technique (1- or 2-stage procedure), experimental as well as clinical studies showed that a soft tissue seal of about 3-4 mm in height was established around the transmucosal part of the implant unit (Abrahamsson et al. 1996, Berglundh & Lindhe 1996, Cochran et al. 1997, Hermann et al. 2000, 2001, Kan et al. 2003b, Tarnow et al. 2003, Lee et al. 2006). Hence, the soft tissue topography at implant-supported restorations is likely to be a reflection of the peri-implant bone topography, and preservation of an optimal peri-implant bone height would be crucial for successful esthetic outcome. However, in this respect differences may exist between single-tooth replacements and multiple-implant restorations.

The current thesis evaluated dimensions and position of the peri-implant soft tissues in relation to topography and alterations of the bone support, and the tissues' significance for the esthetic appreciation of implant therapy.

Esthetic considerations on implant therapy

The restoration of missing teeth should be designed not only to withstand the forces of occlusion and mastication, but also to produce an acceptable esthetic result (Qualtrough & Burke 1994). In a visible anterior region, priority is often given to esthetics, whereas function may be emphasized as the most important factor in a posterior region or a fully edentulous jaw. However, the demands for esthetics and function must be balanced with regard to predictable longevity, minimal biologic consequence, and cost-benefit aspects (Priest 1996).

Patient's esthetic satisfaction with the implant-supported prosthesis is regarded as one of several success criteria in implant therapy (Zarb & Albrektsson 1998). Interestingly, among totally edentulous patients treated with implant-supported prostheses, appearance was the most common cause of dissatisfaction (Blomberg 1985), and esthetic related variables were shown to be strongly associated with the patients' overall satisfaction of implant-supported restorations in the maxillary front region (Levi et al. 2003).

Esthetic factors

In dental literature and textbooks on implant dentistry, color and surface texture of the crown, emergence profile, soft tissue contour, papilla fill and metal visibility are emphasized as significant factors from an esthetic point of view. Furthermore, the implant-supported crown should be harmonious with the neighboring teeth and the contralateral tooth (Belser et al. 1998, Phillips & Kois 1998, Furhauser et al. 2005, Meijer et al. 2005, Cooper 2008). Other related factors include the position of the lip and smile lines and their relation to tooth visibility (Tjan et al. 1984, Qualtrough & Burke 1994). The lip and smile lines play an important role in deciding upon the location of crown margins, pontic contour, the necessity for ridge augmentation, and the type of implant abutment (Wise 1995).

Despite several advantages with implant-borne restorations over other prosthetic alternatives for replacing missing teeth, particularly single-tooth replacements have been regarded as a difficult technique from an esthetic point of view. Neighboring natural teeth give an immediate comparison to an artificially restored single crown, and hence it demands a higher esthetic quality than in situations with multiple artificial crowns (Meijering et al. 1997b). In cases of a high smile line, the esthetic challenge is even greater since not only the crown but also the surrounding soft tissues are exposed (Watson & Crispin 1981, Tjan et al. 1984). In the literature a number of factors have been associated with esthetic complications in implant-supported single-tooth replacements: poor shade of crown restorations (Jemt et al. 1991), over-contouring of crowns and ridge-lap form of facings (Engquist et al. 1995, Moberg et al. 1999), facial mucosal retraction resulting in disharmony in anatomical crown form compared to the contralateral tooth (Jemt et al. 1990, McMillan et al. 1998, Moberg et al. 1999), visible titanium components (Jemt et al. 1991, Ekfeldt et al. 1994, Dueled et al. 2009), mucosal discoloration (Dueled et al. 2009) and deficient papillae (Choquet et al. 2001, Ryser et al. 2005).

Assessments of esthetics

In research related to the esthetic outcome of prosthetic treatment, usually patients and/or dentists involved in the treatment are performing the evaluations. However, to avoid bias due to interpersonal reactions, it was suggested that laypersons and/or dentists who are not involved in the treatment should evaluate the esthetic outcome (Streiner & Norman 1995).

Patients and dentists differed in their assessments of the esthetic outcome of prosthetic treatments (Kalk et al. 1991, Wood et al. 1996, Ekfeldt et al. 1997, Albashaireh et al. 2009). Different perceptions of dental attractiveness between the two groups may be a reason for the difference (Brisman 1980, McCord et al. 1994, Carlsson et al. 1998). In fact, dentists as professionals appeared to be more critical to the esthetic outcome than patients (Wood et al. 1996) and laypersons (Meijering et al. 1997b, Kokich et al. 1999). Esthetic satisfaction is so multidimensional and complex that any single indicator or standardized measure cannot capture it. Consequently, a low discriminatory power of most measures is a common problem in the measurement of satisfaction with the esthetic outcome (Hakestam et al. 1997).

Various scaling methods have been used to measure the esthetic outcome of prosthetic treatment. Some studies adopted a categorical judgment because of its simplicity; either a “yes-no” response or a simple check (Goldstein & Lancaster 1984, Hawkins et al. 1991, Meijering et al. 1997a). The California Dental Association (CDA) system, frequently used for quality evaluation of dental restorations and dental care, is based on categorical responses, i.e., satisfactory or not acceptable, to three characteristics of restoration: surface/color, anatomic form, and marginal integrity (Glantz et al. 1993, Hakestam et al. 1997, Ödman et al. 1998). However, loss of efficiency was one of the major problems in the categorical judgment. Its calculated outcome is at best 67% as efficient as a continuous one, but depending on how the measure is dichotomized, it may drop to under 10 % (Suissa 1991). For this reason, continuous judgments have been commonly applied for the measurement of esthetic satisfaction: adjectival scales (Marunick et al. 1983, Neumann et al. 1989, Wood et al. 1996) and specific scaling methods like a Likert scale (Conny et al. 1985, Vallittu et al. 1996) or a semantic differential scale (Watson et al. 1997).

Another continuous judgment is the Visual Analogue Scale (VAS). It is the essence of simplicity: a line of fixed length, usually 10 cm, with anchors like “not at all satisfied” and “completely satisfied” at the extreme ends, and no words describing intermediate positions. It has been used extensively in medicine to assess e.g. pain, mood, and functional capacity (Huskisson 1974). However, the inconsistency of the scale was pointed out as a problem, and to increase the reliability multiple VAS scorings assessing related aspects of the attribute of interest were recommended instead of the use of a single VAS (Streiner & Norman 1995).

In dental research fields, the VAS has been used most commonly to measure pain during/following dental treatment (Matthews & McCulloch 1993, Chung et al. 2003), but it has also been used to measure, e.g. dentin hypersensitivity (Tammaro et al. 1997), denture security (Lamb & Ellis 1996), patient evaluation of complete dentures (Lamoureux et al. 1999), patient responses to dental implant therapy (Cibirka et al. 1997), and patient satisfaction with implant-supported overdentures (Smedberg et al. 1993, de Grandmont et al. 1994). Furthermore, the VAS was applied to the assessment of dental/facial attractiveness (Howells & Shaw 1985), defects in dental appearance (Lamb et al. 1998), and perception of patient's smile (Jornung & Fardal 2007). A good reliability of the VAS was shown when the first ratings of photographs were compared with those following an interval of 5 weeks (Howells & Shaw 1985). In a consensus statement the VAS was recommended as a subjective measure of the esthetic outcome of implant-supported restorations (Belser et al. 2004b).

Other means to assess the esthetic outcome of single implant-supported restorations are various indices such as implant aesthetic crown index (ICA), pink esthetic score (PES), subjective esthetic score (SES), and comprehensive index comprising pink and white esthetic score (PES/WES) were developed (Meijer et al. 2005, Furhauser et al. 2005, Evans & Chen 2007, Belser et al. 2009). However, the reproducibility of the indices varied markedly among examiner groups (Gehrke et al. 2008 a & b).

Esthetic outcome of implant-supported restorations

Single implant-supported restorations

Esthetic outcome of single implant-supported crown restorations, using a dichotomy judgment (good or bad), revealed that dentists (Haas et al. 1995, Henry et al. 1996, Andersson et al. 1998, Ericsson et al. 2000, Gibbard & Zarb 2002, Zarone et al. 2006) as well as patients (Andersson et al. 1998, Moberg et al. 1999) judged most of the crown restorations as esthetically good. Also, in response to an adjectival scale, patients rated their satisfaction with the appearance of implant-supported single-tooth replacements as very high (Ekfeldt et al. 1994, Avivi-Arber & Zarb 1996, Gibbard & Zarb 2002, Vermeylen et al. 2003). With the use of indices such as PES, ICA and SES, the esthetic outcome of single implant-supported restorations was judged as having a high standard of esthetic quality (Chen et al. 2007, Meijndert et al. 2007, Noelken et al. 2007, Lai et al. 2008, Belser et al. 2009, Buser et al. 2009).

Studies reporting on the esthetic appearance of single implant-supported restorations evaluated with the use of VAS, either by dental professionals or by the patient himself/herself, are summarized in Table 1. The dentists as well as the patients generally expressed a high degree of esthetic satisfaction, however, VAS scores of the patients were commonly higher than those of the dentists.

Table 1. Overview of studies reporting esthetic outcome of single implant-supported restorations assessed by Visual Analogue Scale (VAS).

| Authors | Subjects | Examiner & VAS scores |
|--------------------------|--|---|
| Wannfors & Smedberg 1999 | 69 patients; 80 Branemark implants in the maxillary esthetic region | Patients group (mean at baseline/3 years): Gold veneered with acrylic 85%/71% Gold veneered with porcelain 91%/94% Gold ceramic crown 91%/88% <u>All-ceramic crown 93%/92%</u> Total 88%/85% |
| Kan et al. 2003a | 35 patients; 35 Replace implants in the maxillary anterior region. Immediate implant placement and provisionalization. | Patients (mean): 99% |
| Gotfredsen 2004 | 20 patients; 20 Astra Tech [®] implants in the maxillary esthetic region. Implant placement: Early (Group A), Delayed (Group B). | Patients (mean/range) Group A 98%/91-100% Group B 88%/51-100% Dentists (mean/range) Group A 59%/29-95% Group B 84%/61-97% |
| Pjetursson et al. 2004 | 104 patients; 214 ITI Hollow screw implants. Prostheses types: FPDs 52.5%, Single crowns 47.5%. | Patients (mean ± SD): 97% ± 13 Patients (median/range): 98%/3-100% |
| Cordaro et al. 2006 | 31 patients; 44 narrow neck ITI implants in the mandibular incisors. Prostheses types: Single tooth (ST), 2 adjacent implants (AI), 3 or 4-unit FPD (MU) | Patients (mean ± SD) ST 96% ± 4 AI 82% ± 10 MU 92% ± 6 Dentists (mean ± SD) ST 85% ± 11 AI 44% ± 8 MU 82% ± 8 |

| Authors | Subjects | Examiner & VAS scores |
|-----------------------|---|---|
| Meijndert et al. 2007 | 93 patients; 30 ITI-Esthetic ^{plus} implants in the maxillary anterior zone. Bone augmentation & Porcelain crown (Procera) | Patients (mean/range): 85%/60-100% |
| De Rouck et al. 2008 | 30 patients; 30 Nobel replace tapered TiUnite [®] implants in the maxillary esthetic region. Immediate implant placement & provisionalization | Patients (mean/range): 93%/82-100% |
| Schropp & Isidor 2008 | 34 patients; 34 3i innovation implants in the maxillary esthetic region. Implant placement: Immediate (I), Delayed (D). | Patients (Median, 25 th /75 th) General satisfaction I : 96%, 84/100 D : 93%, 79/99 Shape I : 96%, 79/100 D: 93%, 85/100 Color I ; 95%, 80/100 D: 94%, 87/100 |
| Belser et al. 2009 | 45 patients; 45 single ITI implants in the maxillary anterior region. Early implant placement. | Patients (range): 75-100% |

In a recent systematic review (Jung et al. 2008) the cumulative rate of implant-supported single crowns having an unacceptable or semi-optimal esthetic appearance was reported to be 8.7%.

Implant-supported FPDs

A great majority of patients were very satisfied with the appearance of their FPDs supported by implants evaluated with a 6-grade scale (de Bruyn et al. 1997). However, during the 3-year follow-up period, the esthetic quality of resin-bonded crowns of implant-supported FPDs worsened, while ceramo-metal reconstructions did not change (de Bruyn et al. 2000). In comparison to a control group with periodontally intact dentitions, patients with a history of periodontal disease expressed

a similar level of satisfaction regarding the esthetics of their implant-supported FPDs (Yi et al. 2001). Patients who had had implant-supported FPDs for 20 years were commonly satisfied with the appearance of the FPDs (Lekholm et al. 2006), although 40% of the patients considered the esthetics of their FPDs as only acceptable in response to 3 alternatives: good, acceptable, or non-acceptable. In contrast, the vast majority of patients with implant-supported single crowns were highly satisfied with the esthetic outcome of the prostheses 5-15 years after the treatment, either in response to the categorical questions or VAS (Pjetursson et al. 2004). Taken together these observations indicate that satisfying esthetic appearance may be more difficult to maintain at multi-implant than at single-implant restorations. However, factors that are of significance for the esthetic outcome of multi-implant prostheses have been poorly addressed in the literature.

The peri-implant soft tissues and esthetics

Surgical techniques and prosthetic components in implant dentistry are continuously under development. Ceramics used for the crown have evolved to a level simulating natural teeth in all their physical and optical properties (Anusavice 1996, Conrad et al. 2007), and therefore crown form and soft-tissue profiles have become issues in focus with regard to the esthetic outcome of implant therapy (Spitzer et al. 1992, Boudrias 1993, Reikie 1993 & 1995, Garber 1995, Phillips & Kois 1998, Buser et al. 2004, Furhauser et al. 2005).

There are two components of peri-implant soft tissues to consider in relation to esthetics; (i) the position of the soft tissue margin at the facial aspect of the crown since it will dictate clinical crown length and cervical form of the implant-supported crown, and (ii) the degree of papilla fill in the embrasure spaces lateral to the implant-supported crown (Phillips & Kois 1998, Belser et al. 2004a).

Soft tissue dimensions at implant-supported restorations

The level of connective tissue attachment to the root and the height of the alveolar bone support define the position of the soft tissue margin around a natural tooth (Gargiulo et al. 1961, Wennström 1996). Based on data from a 2-year prospective study of implant-supported reconstructions in totally and partially edentulous patients, it was suggested that similar relationships may exist for the peri-implant soft tissues, i.e., that the soft tissue thickness and the level of bone support determine the height of the supracrestal soft tissue portion (Bengazi et al. 1996). Table 2 gives an overview of clinical studies that have assessed the soft tissue height at implant-supported restorations. The height of the soft tissues established around the transmucosal part of the implant unit ranged between 2.9 - 4.5 mm in the referred studies. Furthermore, patients with a thick periodontal biotype (phenotype) showed greater peri-implant mucosal dimensions than patients with a thin biotype (Kan et al. 2003b, Romeo et al. 2008).

The width of keratinized mucosa at the facial site of implants was claimed to positively influence the papilla height in the inter-implant region (Lee et al. 2005). In addition, mucosal recession at the implant was reported to be greater when the width of the keratinized mucosa was narrow (Bouri et al. 2008, Zigdon & Machtei 2008, Kim et al. 2009).

The interproximal soft tissue completely fills the embrasure space created by two approximating teeth, or by the tooth and the implant, or by two contiguous implants in the ideal esthetic situation (Takei et al. 1989, Phillips & Kois 1998, Buser et al. 2004b, Furhauser et al. 2005). A loss of the interproximal papilla causes an esthetic problem, so-called “black hole disease”, particularly for the restoration of a missing anterior tooth in the maxillary jaw.

The distance between the apical border of the contact area between the crowns and the proximal bone crest influences the papilla fill (Table 3a). Complete papilla fill was always found when the distance between the contact point and the bone crest was ≤ 5 mm (Tarnow et al. 1992). Further, with increased horizontal distance between the two teeth the prevalence of complete papilla fill decreased. Hence, for predictable soft tissue esthetics, square-shaped crown with broad and flat proximal surfaces and

Table 2. Overview of clinical studies on the soft tissue height at implant-supported restorations.

| Authors | Subjects | Implant position | Methods | Soft tissue height ^a (mean ± SD mm) |
|----------------------|---|---------------------------|-------------------------|--|
| Grunder et al. 2000 | 10 patients; 10 Branemark single implants ^b | Maxillary anterior region | Bone sounding | Crown insertion: 3.9 ± 0.7 1-year: 4.2 ± 0.7 |
| Choquet et al. 2001 | 26 patients; 27 Branemark single implants | Maxillary region | Radiographic assessment | Conventional ^c : 3.8 ± 1.0 Modified ^d : 4.0 ± 1.1 |
| Kan et al. 2003b | 45 patients; 45 single implants | Maxillary anterior region | Bone sounding | Mesial sites: 4.2 ± 0.8 Distal sites: 4.2 ± 0.6 Facial sites: 3.6 ± 0.9 |
| Glauser et al. 2005 | 5 patients; 12 mini-implants | Posterior region | Histologic assessment | Implant surfaces Machined: 4.1 ± 1.3 Acid-etched: 4.5 ± 0.5 Oxidized: 4.0 ± 0.8 |
| Tarnow et al. 2003 | 33 patients; 136 inter-implant papillae at FPDs supported by Branemark implants | All regions | Bone sounding | 3.4 ± 1.1 |
| Lee et al. 2005 | 52 patients; 72 inter-implant papillae at FPDs supported by various types of implants | Posterior region | Radiographic assessment | 3.3 ± 0.5 |
| Lee et al. 2006 | 50 patients; 85 inter-implant papillae at FPDs supported by Branemark or Astra implants | Posterior region | Radiographic assessment | Inter-implant distance < 3 Astra Tech: 3.2 ± 0.4 Branemark: 2.9 ± 0.6 Inter-implant distance ≥ 3 Astra Tech: 3.0 ± 0.5 Branemark: 3.2 ± 0.3 |
| DeAngelo et al. 2007 | 21 patients; 21 single implants (Astra Tech & Zimmer Dental) | All regions | Bone sounding | Mesial sites: 3.1 ± 0.9 Distal sites: 3.2 ± 0.9 |

a: Measured at proximal sites except Glauser et al. (2005) that assessed the soft tissue height at the buccal & lingual sites of implant.

b: GBR and connective tissue grafting procedure were used.

c: Implants were uncovered with a standard technique.

d: Implants were uncovered with a technique designed to generate papilla-like formation around dental implants.

contact points positioned as gingival as possible were favored by restorative dentists (Phillips & Kois 1998, Mitrani et al. 2005).

The height of the papillae between a single implant restoration and adjacent teeth is claimed to be related to the bone level, or rather the connective attachment level, at the tooth surfaces facing the implant (Kan et al. 2003b, Palmer et al. 2007). Furthermore, the distance from the bone crest to the apical border of contact point between the single implant-supported crown and the adjacent tooth influences the probability of complete papilla fill (Table 3b). Hence, preservation of the support level at the tooth surface adjacent to the single implant is a key factor for the appearance of the papilla at the single implant-supported restoration.

Table 3. Overview of studies investigating the influence of inter-tooth/implant-tooth/inter-implant distance on the presence of papilla

a. Inter-tooth units

| Authors | Subjects | Method | Findings |
|-----------------------|---|---|--|
| Tarnow et al. 1992 | 30 periodontal patients; 288 interdental sites | Sounding at periodontal surgery | Papilla was present almost 100% when CPB was ≤ 5 mm. |
| Cho et al. 2006 | 80 periodontal patients; 206 papilla | Direct measurement after flap elevation | The number of papilla that filled the interproximal space decreased with increasing CPB and HITD. |
| Chang 2007 | 330 subjects with healthy gingiva; 330 papilla between maxillary central incisors | Radiographic assessment | Central papilla recession as a result of aging is most frequently associated with a wide HITD and long proximal CEJ to bone crest distance. |
| Martegani et al. 2007 | 58 patients; 178 interdental embrasures in the maxillary anterior teeth | Radiographic assessment | An increase in CPB corresponded to a marked increase of the interdental black triangle when HITD was < 2.4 mm. |
| Chang 2008 | 310 subjects with healthy gingiva; 310 papilla between maxillary central incisors | Radiographic assessment | When confounding factors were controlled using multifactorial logistic regression, the distance from the bone crest to the proximal CEJ was the strongest determinant of papilla presence. |

CEJ: Cemento-enamel junction

CPB: Distance from the base of the contact point to the proximal bone crest

HITD: Horizontal inter-tooth distance

b. Implant-tooth units

| Authors | Subjects | Implant treatment | Findings |
|------------------------|--|--|--|
| Choquet et al. 2001 | 26 patients; 27 Branemark implants in the maxillary anterior region | Conventional surgical technique or modified surgical technique for generating papilla. | Papilla was present 100% when CPBt was \leq 5 mm. |
| Cooper et al. 2001 | 47 patients; 53 Astra Tech implants in the maxillary anterior region | Loading 3 weeks after 1-stage surgery | No relationship between HITD and degree of papilla fill |
| Gastaldo et al. 2004 | 48 patients; 80 tooth-implant units | Not reported | Papilla was present 100% when the distance between CPB was 3-4 mm. Papilla was absent 100% when HITD was 2–2.5 mm. There is an interaction between HITD and VITD when the lateral spacing is $>$ 3 mm. |
| Henriksson & Jemt 2004 | 18 patients; 18 Branemark implants in the maxillary central incisors | 9 PFM crowns on CeraOne abutments with bone graft & 9 all ceramic crowns on Procera abutments | No relationship was observed between degree of papilla fill and CPBt. |
| Ryser et al. 2005 | 41 patients; 25 Steri-oss and 16 Splines implants in the maxillary anterior region | Group 1: 2-stage surgery Group 2: immediate provisionalization protocol | CPBt was most critical to papilla maintenance. There were no significant relationships between HITD and papilla maintenance. There was no difference between Group 1 or 2 and degree of papilla fill. |
| Palmer et al. 2007 | 46 patients; 46 Astra Tech implants in the maxillary anterior region | Not reported | The presence or deficiency of papilla was significantly related to CPBt and CPBi. No relation between papilla presence and HITD. |
| Degidi et al. 2008a | 45 patients; 52 Xive implants in the anterior region | Immediately restored after implant placement in post-extraction socket (71%) and healed sites (29%). | CPB should be \leq 7 mm for the presence of papilla. No relation between papilla presence and bone loss at crestal bone peak and implant. |

| Authors | Subjects | Treatment protocol | Findings |
|----------------------|---|--|--|
| Kawai & Almeida 2008 | 40 cleft lip and palate patients; 77 papilla adjacent to single implants in the maxillary anterior region | Implant placement after bone grafting in the cleft areas | Correlations between degree of papilla fill and CPB as well as HITD. The CPB and HITD may have independent or combined relationship with the existence of papilla. |
| Romeo et al. 2008 | 48 patients; 48 ITI implants, 24 anterior and 24 premolars position | Immediate implant placement after teeth extraction | Papilla was present at a HITD of 2.5 to 4 mm in anterior and posterior areas and for CPB \leq 7 mm in posterior areas. Thick biotype was significantly associated with the presence of the papilla. |
| Lops et al. 2008 | 46 patients; 46 AstraTech implants | Immediate implant placement after teeth extraction. | Papilla was present at a HITD of 3-4 mm and at CPB of 3-5 mm. |

CPB: Distance from the base of the contact point to the bone crest
CPBt: Distance from the base of the contact point to the tooth bone level
CPBi: Distance from the base of the contact point to the implant bone level
HITD: Horizontal implant-tooth distance
VITD: Vertical implant-tooth distance

c. Inter-implant units

| Authors | Subjects | Implant treatment | Findings |
|----------------------|---|---|--|
| Gastaldo et al. 2004 | 48 patients; 96 inter-implant units | Not reported | Papilla was present 100% when CPB was 3 mm. Papilla was absent 100% when HID was \leq 2.5 mm. There was an interaction between CPB and HID when the lateral spacing was \geq 3 mm. |
| Degidi et al. 2008b | 49 patients; 99 inter-implant units of 152 Xive implants in the anterior region | Immediately restored after implant placement in post extraction socket. | To guarantee a better esthetic result of papilla; CPB should be 3 to 4 mm, and never > 6mm, and HID should be >2 and <4mm. |

CPB: Distance from the base of the contact point to the bone crest
HID: Horizontal inter-implant distance

Whereas at the proximal sites of single implant restorations the level of the connective tissue attachment to the adjacent tooth surface may favor a more coronal position of the soft tissue margin (Kan et al. 2003b, Palmer et al. 2007), at multiple implant-supported restorations (Table 3c) the topography of peri-implant soft tissues is a reflection of the underlying bone crest and the establishment of a defined and required “biological width” of the supracrestal soft tissue barrier (Berglundh & Lindhe 1996, Cochran et al. 1997). Hence, complete papilla fill may only be established when the distance between the contact point and the bone crest is a maximum of 3-4 mm. Further, loss in height of the proximal bone crest may negatively affect the patient’s esthetic appreciation of the implant therapy, because concomitant with the alterations of the bone crest soft tissue recession may take place (Bengazi et al. 1996).

Peri-implant soft tissue conditions

As a compromise between esthetic and biologic principles, the rule “*as shallow as possible, as deep as necessary*” was recommended for the optimal apical-coronal positioning of the implant (Belser et al. 2004a). Position and axial angulation of the implant are also related to the esthetic result (Boudrias 1993), and if the implant is placed too lingually, the crown has to be overcontoured or ridge-lapped for esthetic reasons (Ekfeldt et al. 1994, Engquist et al. 1995), which in turn may complicate oral hygiene measures underneath the crown facing (Avivi-Arber & Zarb 1996).

In comparison to the marginal tissue conditions of contra-lateral teeth, the soft tissue conditions around implant-supporting single crowns and bridges were found to be significantly worse in terms of pocket probing depth and bleeding on probing, while the plaque accumulation did not significantly differ (Brägger et al. 1997). In the Consensus Report of the Sixth European Workshop on Periodontology (Lindhe & Meyle 2008), the prevalence of peri-implant mucositis on the subject level was described to be about 80%, and peri-implantitis to vary between 28% and 56% depending on the criteria used to indicate peri-implant bone loss. In order to minimize the deteriorating effect of the plaque-associated diseases on peri-implant tissues, adequate means for infection control must be integral part of implant therapy.

Soft tissue alterations at implant-supported restorations

Alterations in the position of the soft tissue margin around implants can create esthetic problems such as a long clinical crown length and/or exposure of metallic abutments (Goodacre et al. 2003). Facial soft tissue recession often occurs shortly after abutment connection/crown placement (Bengazi et al. 1996, Small & Tarnow 2000, De Rouck et al. 2008), but subsequently remains relatively stable during various observation periods (Adell et al. 1986, Apse et al. 1991, Jemt et al. 1994, Bengazi et al. 1996, Andersson et al. 1998, Scheller et al. 1998, Grunder 2000, Kan et al. 2003a, Priest 2003, Cardaropoli et al. 2006, Jemt et al. 2006, Rompen et al. 2007, De Rouck et al. 2008). A thick mucosa (≥ 1 mm) at the mid-buccal aspect of implants was associated with less mucosal recession compared with a thin mucosa (< 1 mm) (Zigdon & Machtei 2008). It was also claimed that the periodontal tissues at the adjacent teeth might have a positive influence on the soft tissue position at the single-tooth implant (Avivi-Arber & Zarb 1996), and that papilla fill may improve spontaneously (Jemt 1997, Grunder 2000, Cardaropoli et al. 2006, Cooper et al. 2007).

Peri-implant bone crest alterations

Since the soft tissue topography at implant-supported restorations is likely to be a reflection of the peri-implant bone topography, preservation of the height of the peri-implant bone crest is crucial for the papilla height and fill in the embrasure space. In this respect, factors with a potential influence on the degree of bone crest resorption have to be considered.

Inter-unit distance

Radiographic evaluations of implants placed adjacent to teeth revealed that the inter-unit distance is a risk factor to consider with respect to marginal bone loss at the tooth. With respect to the *vertical* implant-tooth distance, more marginal bone loss at tooth surfaces facing implants was observed during the period between crown cementation and 1-year follow-up if the single implant was positioned farther away from the cemento-enamel junction of the adjacent tooth (Andersson et al. 1995). A review of studies investigating a potential correlation between the *horizontal* implant-tooth distance and bone level alterations (Table 4a) reveals that a majority of the studies shows an increased marginal bone loss with decreased tooth-implant distance.

Table 4a. *Implant-tooth units*. Overview of studies investigating the relationship between implant-tooth distance and bone level alterations.

| Authors | Subjects | Bone loss at the adjacent teeth: mean (SD) mm | Findings | | | | | | | | | | | | |
|-----------------------|--|--|--|-----------------------------|-------|------------|---------|------------|---------|------------|---|-----------|-------|-----------|--|
| Esposito et al. 1993 | 58 patients; 71 Branemark implants | Preoperative to crown installation: 1.0 (1.1) Crown installation to 3 years: 0.3 (0.6) | A strong correlation between bone loss at adjacent teeth and horizontal tooth-implant distance (HITD) | | | | | | | | | | | | |
| Henry et al. 1996 | 92 patients; 107 Branemark implants | <table border="1"> <thead> <tr> <th>HITD (mm)</th> <th>5-year bone loss</th> </tr> </thead> <tbody> <tr> <td>0-1.0</td> <td>1.5 (0.9)</td> </tr> <tr> <td>1.1-2.0</td> <td>0.9 (0.6)</td> </tr> <tr> <td>2.1-3.0</td> <td>0.6 (0.7)</td> </tr> <tr> <td>3.1-4.0</td> <td>0.3 (0.4)</td> </tr> <tr> <td>> 4.0</td> <td>0.3 (0.7)</td> </tr> </tbody> </table> Preoperative to 5 years | HITD (mm) | 5-year bone loss | 0-1.0 | 1.5 (0.9) | 1.1-2.0 | 0.9 (0.6) | 2.1-3.0 | 0.6 (0.7) | 3.1-4.0 | 0.3 (0.4) | > 4.0 | 0.3 (0.7) | More bone loss at tooth surfaces facing implants when HITD was < 2mm |
| HITD (mm) | 5-year bone loss | | | | | | | | | | | | | | |
| 0-1.0 | 1.5 (0.9) | | | | | | | | | | | | | | |
| 1.1-2.0 | 0.9 (0.6) | | | | | | | | | | | | | | |
| 2.1-3.0 | 0.6 (0.7) | | | | | | | | | | | | | | |
| 3.1-4.0 | 0.3 (0.4) | | | | | | | | | | | | | | |
| > 4.0 | 0.3 (0.7) | | | | | | | | | | | | | | |
| Andersson et al. 1998 | 57 patients; 65 Branemark implants | Preoperative to crown cementation: 0.2 (0.4) Crown cementation to 1y: 0.3 (0.5) 1 to 2y: 0.2 (0.3) 2 to 3y: 0.1 (0.2) 3 to 5y: 0.1 (0.2) | More bone loss at tooth surfaces facing implants when HITD was <2mm | | | | | | | | | | | | |
| Cooper et al. 2001 | 47 patients; 53 Astra Tech implants in the maxillary anterior region | <table border="1"> <thead> <tr> <th>HITD (mm)</th> <th>1-year bone loss at implant</th> </tr> </thead> <tbody> <tr> <td>< 1.0</td> <td>-1.1 (1.5)</td> </tr> <tr> <td>1.0-2.0</td> <td>-0.6 (0.7)</td> </tr> <tr> <td>> 2.0</td> <td>-0.8 (0.7)</td> </tr> </tbody> </table> | HITD (mm) | 1-year bone loss at implant | < 1.0 | -1.1 (1.5) | 1.0-2.0 | -0.6 (0.7) | > 2.0 | -0.8 (0.7) | No relationship between HITD and bone loss at the implant | | | | |
| HITD (mm) | 1-year bone loss at implant | | | | | | | | | | | | | | |
| < 1.0 | -1.1 (1.5) | | | | | | | | | | | | | | |
| 1.0-2.0 | -0.6 (0.7) | | | | | | | | | | | | | | |
| > 2.0 | -0.8 (0.7) | | | | | | | | | | | | | | |
| Thilander et al. 2001 | 18 adolescent patients; 47 Branemark implants | At crown placement Central incisors: 2.1(1.6) Canines: 0.8 (1.0) At 10-year follow-up Central incisors: 4.3(2.7) Canines: 2.2 (1.7) | The shorter the HITD, the larger the reduction of marginal bone level at the adjacent tooth. | | | | | | | | | | | | |
| Krennmair et al. 2003 | 64 patients; 78 single implants (69 Frialit-2 & 9 IMZ implants) | Follow-up period >3 years Anterior teeth: 1.6 (1.0) Posterior teeth: 0.4 (0.3) | A significant influence of the HITD on proximal bone loss at the adjacent teeth in the anterior but not in the posterior region. | | | | | | | | | | | | |

| Authors | Subjects | Bone loss at the adjacent teeth: mean (SD) mm | Findings |
|-------------------------|--|--|---|
| Cardaropoli et al. 2003 | 28 patients; 35 tooth-implant units of 35 FPDs supported by Branemark implants | 3-year bone loss: 0.4 (1.0) | Multiple regression analysis failed to identify significant explanatory factors for the bone level change at the tooth. |
| Ryser et al. 2005 | 41 patients; 41 implants (25 Steri-oss & 16 Splines implants) | Distance between contact point and tooth bone level: At baseline: 5.2 (1.4) 1-year follow-up: 5.3 (1.2) 2-year follow-up: 5.4 (1.2) | A significant association between HITD and the tooth bone height No significant relationships between HITD and papilla maintenance |

HITD: horizontal implant-tooth distance

The horizontal distance between two implants may have an influence on the maintenance of the proximal bone crest level. It was shown in experimental and clinical studies that the inter-implant bone crest level shifted apically when the inter-implant distance decreased (Table 4b, c). Based on observations made in a cross-sectional study, Tarnow et al. (2000) accredited the more apically located position of the bone crest between implants with less than 3 mm of inter-implant distance to the lateral component of the vertical bone loss to the first thread that is common at implants with a platform abutment connection. The proposed explanation, however, was not supported by a 3-year longitudinal study of the same type of implants (Cardaropoli et al. 2003), in which multivariate analysis failed to identify lateral bone loss as a significant factor for longitudinal reduction of the inter-implant bone crest level. Furthermore, animal studies revealed no significant difference in mid-proximal bone crest resorption in relation to the horizontal distance between implants designed with a Morse cone connection and a platform switching (Novaes et al. 2006 a & b, de Oliveira et al. 2006). It was even claimed, based on observations of implants placed in the tibia of rabbits, that closely placed implants may favor bone growth between implants (Hatley et al. 2001). However, whether maintenance of the mid-proximal bone crest level may be related to the design of the implant-abutment interface needs to be documented in longitudinal studies. In addition, a bridge construction supported by multiple implants usually presents with two different proximal areas - tooth-

implant and inter-implant units - and the consequence of loss of peri-implant bone support for the bone crest level and the soft tissue topography might differ between the two types of proximal units because of a potentially positive influence on the maintenance of the bone height from the periodontal support at an adjacent tooth.

Table 4b. *Inter-implant units - clinical studies*. Overview of studies investigating the relationship between inter-implant distance and bone crest alterations.

| Authors | Subjects | Bone loss at the proximal bone crest (BL): mean (SD) mm | Findings | | | | | | | | | | |
|-------------------------|--|--|---|------------------|-----|-----------|-----|-----------|--|-----------|----|-----------|---|
| Tarnow et al. 2000 | 36 patients; 36 inter-implant units between Branemark implants | <table border="1"> <thead> <tr> <th>HID (mm)</th> <th>Bone crest level</th> </tr> </thead> <tbody> <tr> <td>≤ 3</td> <td>1.04*</td> </tr> <tr> <td>> 3</td> <td>0.45*</td> </tr> </tbody> </table> <p>*Vertical distance between bone crest and the fixture/abutment junction (mm)</p> | HID (mm) | Bone crest level | ≤ 3 | 1.04* | > 3 | 0.45* | The lateral bone loss was 1.34 mm from the mesial implant shoulder and 1.40 mm from the distal implant shoulder between the adjacent implants. | | | | |
| HID (mm) | Bone crest level | | | | | | | | | | | | |
| ≤ 3 | 1.04* | | | | | | | | | | | | |
| > 3 | 0.45* | | | | | | | | | | | | |
| Cardaropoli et al. 2003 | 28 patients; 70 inter-implant units in 35 FPDs supported by Branemark implants | 0.5 (0.5) for 3 years | The magnitude of BL during the 3 years of follow-up was negatively associated with HID. | | | | | | | | | | |
| Kupersmidt et al. 2007 | 45 patients; 200 implants in the maxillary anterior region (130 inter-implant gaps) | Bone loss for 8-146 months: 0.83 in immediate implant placement 0.4 in delayed implant placement | Negative correlation between HID and BL in the anterior maxillary region. | | | | | | | | | | |
| Degidi et al. 2008b | 49 patients; 99 inter-implant sites of 152 Xive implants in the anterior region Immediate post-extraction implant placement & restoration | <table border="1"> <thead> <tr> <th>HID (mm)</th> <th>2-year bone loss</th> </tr> </thead> <tbody> <tr> <td><2</td> <td>1.9 (0.7)</td> </tr> <tr> <td>2-3</td> <td>1.4 (0.6)</td> </tr> <tr> <td>3-4</td> <td>1.3 (0.7)</td> </tr> <tr> <td>>4</td> <td>1.0 (0.3)</td> </tr> </tbody> </table> | HID (mm) | 2-year bone loss | <2 | 1.9 (0.7) | 2-3 | 1.4 (0.6) | 3-4 | 1.3 (0.7) | >4 | 1.0 (0.3) | When HID was <2 mm, BL was significantly greater than in the group with HID > 4 mm. |
| HID (mm) | 2-year bone loss | | | | | | | | | | | | |
| <2 | 1.9 (0.7) | | | | | | | | | | | | |
| 2-3 | 1.4 (0.6) | | | | | | | | | | | | |
| 3-4 | 1.3 (0.7) | | | | | | | | | | | | |
| >4 | 1.0 (0.3) | | | | | | | | | | | | |

HID: horizontal inter-implant distance
BL: bone loss at the proximal bone crest

Table 4c. *Inter-implant units - experimental studies.* Overview of studies investigating the relationship between inter-implant distance and bone crest alterations.

| Authors | Material | Crestal bone resorption (CBR) at different horizontal inter-implant distances (HID): mean mm (SD) | Findings | | | | | | | | | | | | | | |
|-------------------------|--|--|----------|----------------------|---|-----------|-----|-----------|---|-----------|--|-----------|--|---|-----------|-----------|--|
| Hatley et al. 2001 | 80 Osseotite micro-miniimplants in 20 New Zealand White Rabbits | <table border="1"> <thead> <tr> <th>HID (mm)</th> <th>Vertical bone growth</th> </tr> </thead> <tbody> <tr> <td>1</td> <td>1.3 (0.6)</td> </tr> <tr> <td>1.5</td> <td>1.0 (0.5)</td> </tr> <tr> <td>3</td> <td>0.8 (0.5)</td> </tr> </tbody> </table> <p>Examination at 90 days after implant placement</p> | HID (mm) | Vertical bone growth | 1 | 1.3 (0.6) | 1.5 | 1.0 (0.5) | 3 | 0.8 (0.5) | Placing implants closer together may increase bone growth. | | | | | | |
| HID (mm) | Vertical bone growth | | | | | | | | | | | | | | | | |
| 1 | 1.3 (0.6) | | | | | | | | | | | | | | | | |
| 1.5 | 1.0 (0.5) | | | | | | | | | | | | | | | | |
| 3 | 0.8 (0.5) | | | | | | | | | | | | | | | | |
| Scarano et al. 2004 | 60 sand-blasted, acid etched Bone system implants placed in 6 dogs | <table border="1"> <thead> <tr> <th>HID (mm)</th> <th>CBR</th> </tr> </thead> <tbody> <tr> <td>2</td> <td>2.0 (0.2)</td> </tr> <tr> <td>3</td> <td>1.8 (0.2)</td> </tr> <tr> <td>4</td> <td>1.0 (0.2)</td> </tr> <tr> <td>5</td> <td>0.2 (0.1)</td> </tr> </tbody> </table> <p>Examination at 12 months after implant placement</p> | HID (mm) | CBR | 2 | 2.0 (0.2) | 3 | 1.8 (0.2) | 4 | 1.0 (0.2) | 5 | 0.2 (0.1) | CBR between implants was significantly different between different HID groups. | | | | |
| HID (mm) | CBR | | | | | | | | | | | | | | | | |
| 2 | 2.0 (0.2) | | | | | | | | | | | | | | | | |
| 3 | 1.8 (0.2) | | | | | | | | | | | | | | | | |
| 4 | 1.0 (0.2) | | | | | | | | | | | | | | | | |
| 5 | 0.2 (0.1) | | | | | | | | | | | | | | | | |
| de Oliveira et al. 2006 | 56 Ankylos implants in 7 dogs | <table border="1"> <thead> <tr> <th rowspan="2">HID (mm)</th> <th colspan="2">CBR</th> </tr> <tr> <th>NS</th> <th>S</th> </tr> </thead> <tbody> <tr> <td>1</td> <td>1.5 (1.9)</td> <td>1.7 (1.2)</td> </tr> <tr> <td>2</td> <td>0.6 (1.2)</td> <td>1.7 (1.5)</td> </tr> <tr> <td>3</td> <td>1.9 (1.0)</td> <td>2.1 (0.9)</td> </tr> </tbody> </table> <p>Examination at 20 weeks after implant placement</p> | HID (mm) | CBR | | NS | S | 1 | 1.5 (1.9) | 1.7 (1.2) | 2 | 0.6 (1.2) | 1.7 (1.5) | 3 | 1.9 (1.0) | 2.1 (0.9) | HID of 1 to 3 mm did not affect CBR of submerged (S) or nonsubmerged (NS) implants in the dog model. |
| HID (mm) | CBR | | | | | | | | | | | | | | | | |
| | NS | S | | | | | | | | | | | | | | | |
| 1 | 1.5 (1.9) | 1.7 (1.2) | | | | | | | | | | | | | | | |
| 2 | 0.6 (1.2) | 1.7 (1.5) | | | | | | | | | | | | | | | |
| 3 | 1.9 (1.0) | 2.1 (0.9) | | | | | | | | | | | | | | | |
| Novaes et al. 2006a | 56 Frialit implants in 7 dogs | <table border="1"> <thead> <tr> <th rowspan="2">HID (mm)</th> <th colspan="2">CBR</th> </tr> <tr> <th>NS</th> <th>S</th> </tr> </thead> <tbody> <tr> <td>1</td> <td>0.2 (0.1)</td> <td>0.2 (0)</td> </tr> <tr> <td>2</td> <td>0.2 (0.1)</td> <td>0.1 (0.1)</td> </tr> <tr> <td>3</td> <td>0.2 (0.1)</td> <td>0.2 (0)</td> </tr> </tbody> </table> <p>Examination at 20 weeks after implant placement</p> | HID (mm) | CBR | | NS | S | 1 | 0.2 (0.1) | 0.2 (0) | 2 | 0.2 (0.1) | 0.1 (0.1) | 3 | 0.2 (0.1) | 0.2 (0) | HID of 1, 2 and 3 mm did not show significant difference in CBR at S or NS. |
| HID (mm) | CBR | | | | | | | | | | | | | | | | |
| | NS | S | | | | | | | | | | | | | | | |
| 1 | 0.2 (0.1) | 0.2 (0) | | | | | | | | | | | | | | | |
| 2 | 0.2 (0.1) | 0.1 (0.1) | | | | | | | | | | | | | | | |
| 3 | 0.2 (0.1) | 0.2 (0) | | | | | | | | | | | | | | | |
| Novaes et al. 2006b | 48 Frialit implants in 6 dogs | <table border="1"> <thead> <tr> <th>HID (mm)</th> <th>CBR</th> </tr> </thead> <tbody> <tr> <td>2</td> <td>0.6 (0.5)</td> </tr> <tr> <td>3</td> <td>1.5 (1.0)</td> </tr> </tbody> </table> <p>Examination at 20 weeks after implant placement</p> | HID (mm) | CBR | 2 | 0.6 (0.5) | 3 | 1.5 (1.0) | HID of 2 and 3 mm did not show significant difference in CBR. | | | | | | | | |
| HID (mm) | CBR | | | | | | | | | | | | | | | | |
| 2 | 0.6 (0.5) | | | | | | | | | | | | | | | | |
| 3 | 1.5 (1.0) | | | | | | | | | | | | | | | | |

HID: horizontal inter-implant distance

CBR: crestal bone resorption between implants

NS: non-submerged implant

S: submerged implant

Implant design and surface characteristics

The magnitude of bone loss around an implant may vary depending on its design and surface topography (Malevez et al. 1996, Norton 1998, Hansson 1999, Lazzara & Porter 2006). A conical implant-abutment interface was shown to more effectively counteract the stress concentration at the level of the marginal bone than a platform interface (Hansson 2000, 2003), which in clinical studies was evidenced by a reduced bone resorption (Gotfredsen & Karlsson 2001, Engquist et al. 2002, Wennstrom et al. 2004). Other features of the marginal portion of the implant, e.g. surface modifications/roughness (Hansson & Norton 1999), micro-threading (Hansson 1999, Palmer et al. 2000, Shin et al. 2006) and platform switching (Lazzara & Porter 2006), may also be of significance for the maintenance of the peri-implant bone level. The Astra Tech ST implant[®], which includes all these features, was in animal and human studies shown to cause minimal amount of peri-implant bone loss (Palmer et al. 2000, Wennström et al. 2005, Berglundh et al. 2005, Abrahamsson & Berglundh 2006, Lee et al. 2007). However, whether the reduced peri-implant bone resorption might reduce the risk for bone loss at the adjacent tooth in case of a close relationship to the implant has not been addressed in previous studies.

Vertical change of adjacent tooth in relation to the single implant

Similar to ankylotic teeth (Kawanami et al. 1999), the osseointegrated single implant restoration faces the risk to be positioned in infra-occlusion by time because of continuous eruption of the adjacent teeth and/or facial bone growth (Heij et al. 2006). Longitudinal studies reported development of infra-occlusal positioning of single implant-supported restorations in the anterior maxilla among both adolescents and adults (Thilander et al. 2001, Bernard et al. 2004, Jemt et al. 2007) (Table 5). Jemt et al. (2007) observed a higher incidence of infra-occlusion in females than males, and this was suggested to be due to a greater increase of anterior face height and posterior rotation of the mandible among female. In case of development of infra-occlusal positioning, discrepancy of the incisal edges as well as of the facial soft-tissue margins between the single implant-supported crown and adjacent teeth may be so evident that a new crown restoration and/or soft tissue corrections will be required to regain esthetic harmony (Avivi-Arber & Zarb 1996, Poggio & Salvato 2001, Tarlow 2004, Jemt 2005).

Table 5. Overview of studies on infra-occlusion of single implants and ankylosed teeth.

| Authors | Subjects (age) /follow-up period | Methods | Findings | | | | | | | | | | | | | | | | | | | | | | | | | |
|-----------------------|--|--|--|------------------------------|--------------|--------|-------------|----------|-------------|------|---------|------|---|----------------|------|--------|---------|----|---|---------|---|---|---------|---|---|---------|---|---|
| Kawanami et al. 1999 | 52 patients (6-48 years) / 1-21 (mean 4.2) years; 52 ankylosed maxillary incisors | Assessment in photos of study cast models | Mean infra-position rate: 0.07 mm/year in males and 0.07 mm/year in females who developed ankylosis at 20 - 30 years of age. Marked infra-position of teeth traumatized before the age of 16 in boys and before the age of 14 in girls. | | | | | | | | | | | | | | | | | | | | | | | | | |
| Thilander et al. 2001 | 15 patients (13-17 years) /10 years; 29 single implants in premolars, canines, and upper incisors position | Study model assessment of infra-occlusion | In the upper incisor region <table border="1"> <thead> <tr> <th>Crown placement to</th> <th>Mean (SD) mm</th> </tr> </thead> <tbody> <tr> <td>1 year</td> <td>0.13 (0.14)</td> </tr> <tr> <td>10 years</td> <td>0.98 (0.62)</td> </tr> </tbody> </table> *Range: 0.1-2.2 mm Infra-occlusion at 3 years follow-up: Canine regions: 0 Premolar region: 0.1-0.6 mm. | Crown placement to | Mean (SD) mm | 1 year | 0.13 (0.14) | 10 years | 0.98 (0.62) | | | | | | | | | | | | | | | | | | | |
| Crown placement to | Mean (SD) mm | | | | | | | | | | | | | | | | | | | | | | | | | | | |
| 1 year | 0.13 (0.14) | | | | | | | | | | | | | | | | | | | | | | | | | | | |
| 10 years | 0.98 (0.62) | | | | | | | | | | | | | | | | | | | | | | | | | | | |
| Bernard et al. 2004 | 28 patients (16-55 years) / 1-9 (mean 4.2) years; 28 single implants in the maxillary anterior region | Radiographic assessment of eruption of the adjacent tooth | Young subjects: 0.10-1.65 (mean 0.69) mm. Adult subjects: 0.12-1.86 (mean 0.67) mm. No difference in the amount of vertical eruption between males and females, nor according to localization of the implant. | | | | | | | | | | | | | | | | | | | | | | | | | |
| Jemt et al. 2007 | 25 patients (25.4 ± 10 years) /15.9 ± 0.7 years; 28 single implants in the maxillary anterior region | Clinical index <table border="1"> <thead> <tr> <th></th> <th>Vertical infra-position (mm)</th> </tr> </thead> <tbody> <tr> <td>Score A</td> <td>No</td> </tr> <tr> <td>Score B</td> <td><0.5</td> </tr> <tr> <td>Score C</td> <td>≤1.0</td> </tr> <tr> <td>Score D</td> <td>>1.0</td> </tr> </tbody> </table> | | Vertical infra-position (mm) | Score A | No | Score B | <0.5 | Score C | ≤1.0 | Score D | >1.0 | Numbers of implants (n=28) <table border="1"> <thead> <tr> <th>Infra-position</th> <th>Male</th> <th>Female</th> </tr> </thead> <tbody> <tr> <td>Score A</td> <td>11</td> <td>0</td> </tr> <tr> <td>Score B</td> <td>5</td> <td>5</td> </tr> <tr> <td>Score C</td> <td>2</td> <td>1</td> </tr> <tr> <td>Score D</td> <td>2</td> <td>2</td> </tr> </tbody> </table> The risk for major tooth movements significantly higher in females than in males ($p<0.05$). | Infra-position | Male | Female | Score A | 11 | 0 | Score B | 5 | 5 | Score C | 2 | 1 | Score D | 2 | 2 |
| | Vertical infra-position (mm) | | | | | | | | | | | | | | | | | | | | | | | | | | | |
| Score A | No | | | | | | | | | | | | | | | | | | | | | | | | | | | |
| Score B | <0.5 | | | | | | | | | | | | | | | | | | | | | | | | | | | |
| Score C | ≤1.0 | | | | | | | | | | | | | | | | | | | | | | | | | | | |
| Score D | >1.0 | | | | | | | | | | | | | | | | | | | | | | | | | | | |
| Infra-position | Male | Female | | | | | | | | | | | | | | | | | | | | | | | | | | |
| Score A | 11 | 0 | | | | | | | | | | | | | | | | | | | | | | | | | | |
| Score B | 5 | 5 | | | | | | | | | | | | | | | | | | | | | | | | | | |
| Score C | 2 | 1 | | | | | | | | | | | | | | | | | | | | | | | | | | |
| Score D | 2 | 2 | | | | | | | | | | | | | | | | | | | | | | | | | | |

Remarks

- Soft tissue dimensions at implant-supported restorations have been described but intra-individual comparison with those at contra-lateral natural teeth is lacking in the literature.
- Patient's esthetic satisfaction with an implant-supported prosthesis is one of several success criteria used in implant therapy. Although the literature indicates that dentists and patients generally express a high degree of satisfaction with the esthetic outcome of single implant-supported crown restorations, there is a lack of information with respect to factors of significance for the esthetic satisfaction.
- A conical implant-abutment interface was shown to more effectively counteract the stress concentration at the level of the marginal bone than a platform interface, which in clinical studies was evidenced by a reduced bone resorption. However, whether the reduced peri-implant bone resorption might reduce the risk for bone loss at the adjacent tooth in case of a close relationship to the implant has not been addressed in previous studies.
- At the replacement of multiple teeth with an implant-supported restoration, the topography of the bone crest is crucial for the position of the soft tissue margin in the inter-implant area. Whether maintenance of the mid-proximal bone crest level may be related to the design of the implant-abutment interface needs to be documented in longitudinal studies.
- The consequence of the loss of peri-implant bone support for the bone crest level and the soft tissue topography might differ between the two types of proximal units in a bridge construction supported by multiple implants, i.e., tooth-implant and inter-implant units because of a potentially positive influence on the maintenance of the bone height from the periodontal support at an adjacent tooth. However, whether soft tissue improvement will occur over time in the embrasure spaces at multiple implant-supported prostheses, similar to that observed for papillae next to single implant-supported restorations, has not been studied.

AIMS

The specific objectives of the studies included in the thesis were:

- to make a comparative evaluation of crown and soft tissue dimensions between implant-supported single-tooth replacements and the contra-lateral natural teeth (*Study I*).
- to assess and compare patients' and dentists' judgment of the esthetic outcome of implant-supported single-tooth replacements (*Study II*).
- to evaluate longitudinal changes in bone topography and tooth/implant relationship in patients with single implants with a micro-threaded, conical marginal part (*Study III*).
- to longitudinally evaluate bone alterations around implants with a conical implant-abutment interface in relation to implant-tooth and inter-implant distances (*Study IV*).
- to longitudinally evaluate soft and hard tissue alterations at implant-supported fixed partial dentures from time of implant placement (*Study V*).

MATERIAL AND METHODS

Subject samples

Subjects for *Study I & II* were recruited among those who had been treated with an implant-supported single-tooth replacement in the esthetic zone of the maxillary jaw (tooth region 14-24) at the Clinic for Implants and Material Development (SIM Clinic), Mölndal, Sweden, and were subjected to a recall examination during a 7-month period. Out of the available 29 patients, 20 subjects who had (i) a non-restored contra-lateral natural tooth and (ii) completed the implant-supported crown restoration at least 6 months prior to the follow-up examination were included for comparative evaluation of crown and soft tissue dimensions between implant-supported single-tooth replacements and the contra-lateral natural tooth (*Study I*). Twelve patients, who had clinical photographs available at the time of the crown insertion, were in addition evaluated with respect to longitudinal alterations in papilla fill at proximal sites adjacent to the implant-supported crown. For *Study II*, which focused on esthetic evaluations, all 29 patients were included.

Subjects for *Study III-V* were recruited from those who had been treated with implant-supported restorations at the Department of Periodontology, Institute of Odontology, the Sahlgrenska Academy at University of Gothenburg, Sweden. To be included in *Study III*, the patient had to have a single implant (Astra Tech[®] ST) placed in the esthetic zone of the maxillary jaw and functionally loaded for at least 5 years. Furthermore, radiographs of the implant site had to be available at crown cementation and at 1, 5 and preferably 8 years of follow-up.

Subjects for *Study IV* and *V* were patients who had been referred due to advanced chronic periodontitis, had received comprehensive periodontal treatment of the remaining dentition (Nyman & Lindhe 2003) before the implant placement, and were included in an individually designed supportive care program (Lang & Lindhe 2003). *Study IV* included patients who had received fixed partial dentures (FPDs) supported by Astra implants (Astra Tech[®] Dental Implant System; Mölndal, Sweden) and had their original FPDs in place at the 5-year follow-up examination. Patients who were candidates for treatment with implant-supported fixed partial dentures in the premolar-molar regions of the jaws were invited to participate in *Study V*. Exclusion

criteria were (i) smoking >10 cigarettes/day, (ii) inadequate self-performed infection control and (iii) need of bone augmentation or sinus lift procedures in the site of intended implant placement.

Characteristics of the various subject samples are presented in Table 6.

Table 6. Characteristics of the subject samples.

| | <i>Study I</i> | <i>Study II</i> | <i>Study III</i> | <i>Study IV</i> | <i>Study V</i> |
|----------------------|----------------|-----------------|-------------------------|-------------------------|---------------------------|
| No. patients | 20 | 29 | 31 | 43 | 16 |
| Mean age (range) | 34 (18-49) | 32 (18-67) | 40 (19-71) | 59 (36-76) | 63 (48-73) |
| Male/female | 13/7 | 18/11 | 18/13 | 16/27 | 5/11 |
| Implant system | Branemark | Branemark | Astra Tech [®] | Astra Tech [®] | 3i Osseotite [®] |
| No. implants | 21 | 41 | 33 | 130 | 43 |
| Position of implants | | | | | |
| Incisors | 19 | 37 | 19 | 11 | - |
| Canines | 1 | 3 | - | 10 | - |
| Premolars | 1 | 1 | 14 | 76 | 26 |
| Molars | - | - | - | 33 | 17 |
| Type of prosthesis * | SC | SC | SC | FPD | FPD |
| No. Prostheses | 21 | 41 | 33 | 48 | 18 |
| No. Proximal units | | | | | |
| Tooth-implant | - | - | - | 36 | 17 |
| Inter-implant | - | - | - | 67 | 25 |

*SC: single crown, FPD: fixed partial denture.

Ethical approval

All subjects for the studies were informed about the purpose and design of the study and gave their written consent before they entered the study. Approval of the study protocols was obtained from the Ethics Committee at the Sahlgrenska Academy, University of Gothenburg (*Study III-V*).

Implant treatment

All subjects in *Study I & II* had received commercially available standard Brånemark

dental implants (Nobel Biocare AB, Göteborg, Sweden) inserted according to routine surgical principles (Lekholm & Jemt 1989). After a healing period of 6 months, the fixture was uncovered and an abutment was connected. The abutment, the CeraOne[®] system or the CerAdapt[®] system, was manually connected to the fixture with a gold screw. The prosthetic procedure was performed after approximately 3 weeks of soft tissue healing. Except for 3 cases with a conventionally made metal-ceramic crown, all ceramic crowns were used. Instructions in oral hygiene measures using regular toothbrush but no interdental devices were given to all patients following installation of the implant-supported crown.

Subjects involved in *Study III* had been treated with Astra Tech[®] ST implants with a body diameter of 3.5 mm and a marginal conical diameter of 4.5 mm (Astra Tech AB, Mölndal, Sweden), which were inserted in a submerged procedure according to the manufacturer's manual. About 6 months after implant installation, standard ST-Abutments[®] varying in length from 0 and 1.5 mm, were connected to the implants. Immediately after abutment connection, an acrylic crown restoration was fabricated and inserted as a temporary prosthesis. The final porcelain fused to metal crown was cemented about 4 weeks after the abutment connection.

In *Study IV*, all implants (Astra Tech[®] Dental Implant System) had a diameter of 3.5 mm while the length varied between 8-19 mm. Abutment connection was performed in a second stage surgical procedure 3 months (mandible) or 6 months (maxilla) after implant installation. Standard, Uni-abutments[®] (Astra Tech[®] Dental Implant System) of varying length were used. The final, screw retained fixed partial denture (FPD) was completed and delivered about 4 weeks after abutment connection. In conjunction with the delivery of the FPDs, the patients were given additional oral hygiene instruction with special emphasis on how the implants must be cleaned.

In *Study V*, the surgical treatment was performed according to a 1-stage surgical protocol. In each treated jaw segment, two to three Osseotite[®] implants (3i/Implant Innovations, Palm Beach Gardens, FL, USA), depending on the space available, were inserted (diameter 3.75 mm; length varying between 8.5 and 15 mm). The preparation of the recipient sites was done without counter-sinking, i.e., the platform of the inserted implants was located approximately 0.7 mm supra-crestally. After implant installation, one-unit healing abutments were attached, followed by adaptation and closure of the flaps with interrupted sutures. A temporary acrylic restoration was

fabricated and inserted 8 weeks post-surgery. At 6 months, the temporary FPDs were exchanged to screw-retained porcelain-fused-to-metal FPDs. Careful oral hygiene instructions with an emphasis on how to clean the implants with a regular toothbrush and inter-dental brushes were given to all patients in conjunction with the installation of the temporary as well as the final FPDs. Throughout the 3-year period of monitoring, the patients were enrolled in an individually designed SPT program that called for examination of the periodontal and peri-implant soft tissues once every 6 months. Sites that showed bleeding following probing were carefully instrumented and polished by use of rubber cups and low abrasive polishing pastes. In addition, the loading on the implant-supported prosthesis was carefully evaluated at annual follow-up examinations and adjustments were made when indicated.

Assessments

Clinical, radiographic, photographic and study model assessments as well as questionnaire assessments were included in the various studies (Table 7).

Table 7. Description of assessment methods.

| | <i>Study I</i> | <i>Study II</i> | <i>Study III</i> | <i>Study IV</i> | <i>Study V</i> |
|---------------------------|----------------|-----------------|------------------|-----------------|----------------|
| Clinical assessments | √ | - | - | - | √ |
| Photographic assessments | √ | √ | - | - | √ |
| Study model assessments | - | - | - | - | √ |
| Radiographic assessments | - | - | √ | √ | √ |
| Questionnaire assessments | √ | √ | - | - | - |

Clinical assessments

In *Study I* the following variables were assessed clinically at the implant-supported crown as well as at the contra-lateral natural tooth (Fig. 1):

- *Clinical crown length*; the distance between the soft tissue margin and the incisal edge measured to the nearest 0.5 mm.
- *Width of the crown*; the widest mesio-distal dimension of the crown measured to the nearest 0.5mm.

- *Facio-lingual crown dimension*; the distance between the facial and lingual aspect of the crown at the soft tissue margin measured to the nearest 0.1 mm with a gauge.
- *Soft tissue margin level*; the distance between the most apical point of the soft tissue margin at the facial aspect of the crown and a line connecting the midfacial level of the soft tissue margin at the adjacent teeth, measured to the nearest 0.5 mm with the periodontal probe.
- *Papilla height*; the distance between the top of the mesial and distal papilla to a line connecting the midfacial level of the soft tissue margin of the two adjacent teeth, measured to the nearest 0.5 mm with the periodontal probe (Olsson et al 1993).

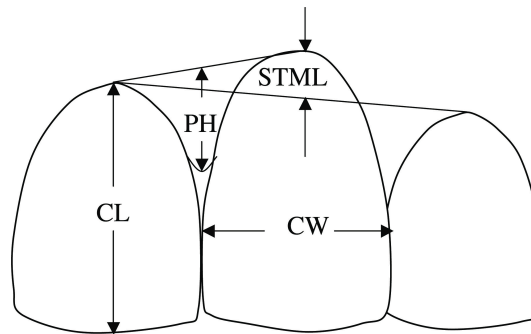


Fig. 1. Schematic illustration of various crown and soft tissue dimensions: crown length (CL), crown width (CW), soft tissue margin level (STML), and papilla height (PH).

In *Study I & V*:

- *Width of keratinized mucosa*; the distance between the soft tissue margin and the mucogingival junction, measured to the nearest 0.5 mm with the periodontal probe.
- *Thickness of mucosa*; assessed with an ultrasonic device (SDM, Krupp Corp., Essen, Germany; Eger et al. 1996) mid-buccally at a level corresponding to the bottom of the probeable pocket. Double recordings were obtained and the mean value was calculated.

In *Study V*:

- *Soft tissue height* coronal to the implant/abutment level measured to the nearest 0.5 mm with the periodontal probe.

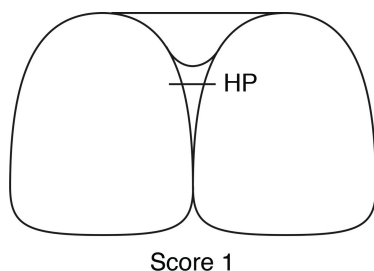
In addition, the following assessments of the clinical conditions at implants and adjacent teeth (mesial, buccal, distal and lingual) were included:

- *Oral hygiene status (plaque score)*; presence/absence of visible plaque at the soft tissue margin (*Study I*).
- *Soft tissue condition (mucositis score)*; determined according to criteria described by Bengazi et al. (1996) (*Study I*).
- *Probing depth*; measured to the nearest mm with a calibrated periodontal probe having 1 mm markings (HuFriedy™, tip diameter 0.45 mm), using a standardized probing pressure of 0.35N (0.25N in *Study V*). Furthermore, bleeding following probing (within 15 sec) was recorded (*Study I & V*).

Photographic assessments

At the follow-up examination (*Study I & II*), clinical photographs were obtained of the implant-supported crown and the contralateral natural tooth as well as of the anterior teeth when smiling. All photographs were taken at a fixed distance and with the same camera system equipped with a 100 mm macro lens with ring flash illumination, and the use of Kodak Elite II 200 color slide films. Photographs obtained at the time of crown cementation were compared with those at the follow-up examination to assess longitudinal alterations of the Papilla Index (Fig 2) at the mesial and distal aspects of each implant (*Study I*). For the assessment of the esthetic outcome by prosthodontists, the photographs taken at the follow-up examination were projected on a screen in the following order; an extra-oral smile view and 3 simultaneously projected intra-oral photographs, i.e., a front view of the anterior teeth (magnification 1:1.5) and 2 photographs viewing the implant-supported crown and the contra-lateral natural tooth (magnification 1:1). The smile type (Tjan et al. 1984) and abutment visibility of each single implant-supported crown restoration were also determined (*Study II*).

Fig 2. The Papilla Index according to the description by Jemt (1997).



- Index score 0 - No papilla is present.
- Index score 1 - Less than half of the height of the papilla (HP) is present.
- Index score 2 - Half or more of the height of the papilla is present.
- Index score 3 - The papillae fill up the entire proximal space and are in good harmony with the adjacent papillae.
- Index score 4 - The papillae are hyperplastic.

In *Study V*, digital photographs of the implant-supported FPDs were taken after insertion at 6 months and at 1, 2 and 3 years of follow-up. The ratio between clinical crown height measured on the study model (see below) and in the photograph was calculated, and used for calibration of the linear measurements in the individual photographs. Photographs of the FPDs taken at various follow-up intervals were calibrated with the use of the vertical length of proximal contact area between two crown units, or the crown height if visible cervical crown border. The following variables were assessed at implants and the adjacent teeth with the use of the measuring tool available in Photoshop® (Adobe® Photoshop® 7.0; Adobe Systems Inc., USA).

- *Facial soft tissue level*; the distance between the soft tissue margin and incisal edge of the crown.
- *Papilla level*; measured at the mesial and distal sites from a reference line connecting the occlusal edge of the crowns.

Furthermore, the degree of *papilla fill* was determined at tooth-implant and implant-implant proximal areas using the scoring system of the Papilla Index (Jemt 1997).

Study model assessment (Study V)

The following variable was measured to the nearest 0.1 mm on study models obtained at the 3-year follow-up examination:

- *Facial soft tissue level*; the distance between the soft tissue margin and the incisal edge of the crown measured with the use of a Boley gauge® (Hu-Friedy Chicago, Chicago, USA).

Radiographic assessments (Study III, IV & V)

Standardized radiographs, with the film (Kodak Ektaspeed Plus, Eastman Kodak Co., Rochester, NY, USA) kept parallel and the X-ray beam (Heliodent MD, 60 kV, 7mA, Siemens AG, Bensheim, Germany) perpendicular to the implant, were taken using individually fabricated film holders (Have-Super-Bite, Hawe-Neos dental, Genilino, Switzerland). The film holder was attached to the occlusal surface of the supra-structure using an impression material (Optosil®P, Bayer Dental, Leverkusen, Germany).

In the radiographs, peri-implant bone level assessments (bone-to-implant contact level) were performed by two experienced radiologists working together and by the

use of a magnifying lens (x7) to the nearest 0.1 mm (for details see Wennström et al. 2004 & 2005) (*Study III & IV*).

All other measurements were performed by the use of the image measurement program, NIH Image (Wayne Rasband, U.S. National Institutes of Health, available electronically via Internet from the NIH Image website at <http://rsb.info.nih.gov/ni-image>; Wyatt et al. 2001), on scanned images of the radiographs (resolution 500 dpi; PowerLook1000® UMAX Technologies, Inc., USA). The known implant dimensions were used for calibration with regard to magnification. With the use of a reference line drawn perpendicular to the implant surface at the corner between the vertical and conical parts of the implant head (0.3 mm below the implant/abutment level) (*Study III & IV*) and implant/abutment connection level (*Study V*), linear distances were assessed to the nearest 0.1 mm by a trained examiner (MC). The implant in the implant-tooth unit, and the anterior implant in the inter-implant units, were used as a reference implant for the linear measurements.

The following variables were assessed at the mesial and distal sites of the implant and the implant-facing sites of the adjacent tooth (Fig. 3 & Table 8);

Table 8. Variables in radiographic assessments.

| | <i>Study III^a</i> | <i>Study IV^b</i> | <i>Study V^c</i> |
|--|------------------------------|-----------------------------|----------------------------|
| Implant position | | | |
| <i>Vertical implant-tooth distance</i> | √ | √ | √ |
| <i>Vertical inter-implant distance</i> | - | √ | √ |
| <i>Horizontal implant-tooth distance</i> | √ | √ | √ |
| <i>Horizontal inter-implant distance</i> | - | √ | √ |
| <i>Root apex position</i> | √ | - | - |
| Bone topography | | | |
| <i>Bone level at tooth</i> | √ | √ | √ |
| <i>Bone level at implant</i> | √ | √ | √ |
| <i>Mid-proximal bone crest level</i> | - | √ | √ |

Radiographic assessments were performed at:

a. crown placement, 1, 5 and 8 years of follow-up

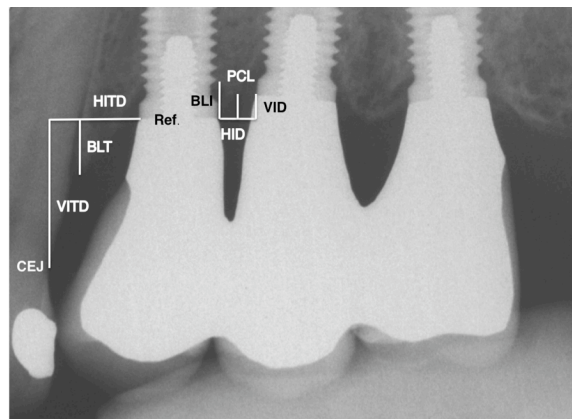
b. bridge insertion, 1 and 5 years of follow-up

c. implant placement surgery, 2 and 6 months, 1, 2 and 3 years of follow-up

Implant position

- *Vertical implant-tooth distance (VITD)*: the distance between the reference level and the location of the cement–enamel junction (CEJ) on the neighboring tooth.
- *Vertical inter-implant distance (VIID)*: the distance between two neighboring implants at the reference level.
- *Horizontal implant-tooth distance (HIID)*: the distance between implant and adjacent tooth at the reference level.
- *Horizontal inter-implant distance (HID)*: the distance between two neighboring implants at the reference level.
- *Root apex position (RAP)*: the position of the apex of the adjacent tooth in relation to the thread level of the implant (lower half thread, i.e. 0.3 mm) assessed from the apical extension of the conical part of the implant. Two implants had to be excluded with regard to this assessment because the apex of the teeth was not reproduced in the radiographs.

Fig. 3 Assessments performed on scanned images of radiographs. CEJ = Cemento-enamel junction, VITD = vertical implant-tooth distance, BLT = bone level at the tooth, HITD = horizontal implant-tooth distance, Ref = Implant-abutment junction, BLI = bone level at implant, PCL = mid-proximal bone crest level, HID = horizontal inter-implant distance, VID = vertical inter-implant distance.



Bone topography

- *Bone level at tooth (BLT)*: the vertical distance between the reference level and the most coronal bone level at which the width of the periodontal ligament space was considered normal.
- *Bone level at implant (BLI)*: the vertical distance between the reference level and the bone-to-implant contact.

- *Mid-proximal bone crest level (PCL)*: the mid-proximal vertical distance between the bone crest and reference level.

Questionnaire assessments (Study I & II)

According to the general guidelines in the construction of continuous scales, questionnaires were designed with the use of visual analogue scale (VAS) (Streiner & Norman 1995). The patients were asked to mark their assessments on a 100 mm line having end-phrases "not at all satisfied" on the left and "completely satisfied" on the right. The distance from the left end of the VAS line to the mark made by the patient was measured to the nearest mm and reported as a percentage. To avoid bias, i.e. interpersonal reactions, the patients completed the questionnaire at the recall examination under the supervision of a staff member who did not know the patients.

Patients

At the follow-up examination, the patients were asked to respond to a VAS question "What is your esthetic appreciation of your implant-supported single crown?" (*Study I*). A questionnaire*, composed of 7 questions using VAS scales and two categorical questions, was utilized to assess the patient's satisfaction with respect to the esthetic outcome of the single implant-supported crown (*Study II*).

Dentists

Five prosthodontists at the department of Prosthetic dentistry, University of Gothenburg, Sweden, who were not involved in the treatment of the patients individually assessed the esthetic outcome of the implant-supported crowns from a professional point of view. Extra- and intra-oral photographs taken at the recall examination were used for the assessment. The prosthodontists responded to a questionnaire** composed of 8 VAS questions and one question related to the identification of the implant-supported crown. Three VAS questions shared the same content with the questions used for the patients (*Study II*).

* Appendix I

** Appendix I

Error of methods

With an interval of 1 month, the papilla index of 10 randomly selected patients was determined twice (*Study I*). The scorings were found to be identical at 90% of the sites.

The 5 prosthodontists performed repeated assessments by use of the questionnaire of 3 randomly selected implant-supported crowns in order to evaluate the reproducibility of the method (*Study II*). The mean difference between the two assessments was 6.3 % (S.D. 7.2). The calculated Spearman rank correlation coefficient was 0.79 ($p < 0.001$).

The measurement error of the radiographic assessments in *Study III & IV* was estimated by repeated assessments with a time interval of 2 weeks of 10 randomly selected images (20 mesial and distal sites). The mean differences between the double assessments of the various distances varied between 0.01 - 0.04 mm (SD 0.03 - 0.06). The mean difference between double recordings of the bone-to-implant level with the use of the magnifying lens was 0.04 mm (SD 0.33) (Wennström et al. 2004).

The assessment of the apex level of adjacent tooth in relation to the implant threads (*Study III*) was equal in 25 out of 28 cases (89 %), and in the remaining 3 cases the difference was half a thread (0.3 mm).

In *Study V* one radiograph per patient (16 radiographs) was randomly selected for repeated measurements during a 2-month interval. The mean difference between the measurements was 0.02 mm (S.D. 0.05) for periodontal bone level, 0.01 mm (0.04) for peri-implant bone level, 0.02 mm (0.03) for horizontal tooth-implant distance, and 0.03 mm (0.04) for horizontal inter-implant distance, and 0.02 mm (0.04) for proximal bone crest level.

The validity of the photographic assessments in *Study V* was examined by the comparison of the facial soft tissue level at 29 units in 15 patients measured on photographs and study models. Mean difference between the two measurements was 0.01 mm (S.D. 0.48). In 83% of the paired assessments the difference was less than 0.5 mm.

Data analyses

Data handling and statistical testing were performed with the use of StatView 4.5 (Abacus Concepts, Inc., Berkeley, CA, USA) (*Study I & II*), SPSS 16 software package (SPSS Inc., Chicago, Illinois, USA) (*Study III-IV*) and SAS 9.1 (SAS Institute Inc., Cary, NC, USA) (*Study V*). For data description, frequencies, mean values, standard deviations and 95% confidence intervals were calculated for the various assessments (*Study I-V*).

Study I

Differences in clinical variables between implant-supported crowns and contralateral control teeth were analyzed using the paired t-test. The Wilcoxon signed rank test was used in analysis of differences in papilla index score between the time of crown placement and the follow-up examination.

Study II

The Mann-Whitney U test was employed to compare VAS scores between subgroups of patients. In the comparison of the dentists' assessments of satisfaction with the color of the incisal and cervical half of the crown, Wilcoxon signed rank test was used. Multiple regression analyses were utilized to evaluate the influence of various variables on the patients' and dentists' overall satisfaction with the appearance of the single implant-supported crowns.

Study III

To analyze the influence of various factors on the 5-year longitudinal marginal bone level change at the adjacent teeth, a multiple regression model was formulated including horizontal and vertical implant-tooth distances, longitudinal bone level change at the implant, and difference in marginal bone level between tooth and implant at baseline as explanatory variables. A potential relationship of age, gender, and implant position (incisor or premolar) to the presence of vertical change in position of the adjacent teeth relative to the implant was analyzed with the use of logistic regression models.

Study IV

Multiple regression models were formulated to analyze the influence of various factors on the bone level changes over the 5-year interval. The model for the *tooth/implant units* employed the 5-year bone level change at the neighboring tooth as

the dependent variable, and 5-year bone level change at implant, horizontal and vertical tooth-implant distances as explanatory variables. With regard to change in mid-proximal bone level at *implant/implant units*, the 5-year bone level change at implants, horizontal and vertical inter-implant distances were included as independent variables.

Study V

Conditions at proximal sites of the implants were described with respect to the presence of adjacent tooth or implant, i.e. tooth-facing and implant-facing sites, respectively. Because of clustering of sites in subjects, linear mixed-effect models (SAS Proc Mixed) were applied to detect differences between the two categories of proximal units and between various examinations following control of normal distribution of the data (Shapiro-Wilk test). The potential influence of various factors on the papilla height at 6 months and mid-proximal bone crest change at 3 years was evaluated by the use of multiple regression analysis.

RESULTS AND DISCUSSION

Study I

Crown dimensions

The clinical crown of the implant-supported reconstructions was found to be on average 1.0 mm longer than the contralateral natural tooth and 0.8 mm smaller in facio-lingual dimension ($p < 0.01$) (Table 9). The difference in clinical crown height may already have been present at time of crown insertion due to loss of bone height following extraction of the natural tooth. However, retraction (recession) of the soft tissue margin may also have taken place subsequent to crown placement, as has been reported in previous studies on implant-supported prostheses (Adell et al. 1986, Apse et al. 1991, Jemt et al. 1994, Bengazi et al. 1996, Grunder 2000, Small & Tarnow 2000, Cardaropoli et al. 2006).

Table 9. Crown and soft tissue dimensions at implant-supported single crown restorations and contralateral teeth. Mean values (SD).

| Variable | Implants | Teeth | Difference |
|------------------------------------|------------|------------|-------------|
| Clinical crown length (mm) | 11.0 (1.8) | 10.0 (1.5) | 1.0 (1.3)* |
| Facio-lingual crown thickness (mm) | 6.8 (0.6) | 7.6 (1.0) | -0.8 (1.1)* |
| Width of keratinized mucosa (mm) | 3.9 (1.4) | 4.6 (1.1) | -0.7 (1.5) |
| Mucosa thickness (mm) | 2.0 (0.7) | 1.1 (0.3) | 0.9 (0.7)** |
| Papilla height (mm) | | | |
| mesial | 3.9 (0.9) | 4.1 (0.9) | -0.2 (0.7) |
| distal | 3.6 (0.9) | 4.5 (1.2) | -0.9 (1.3)* |
| Papilla Index (Jemt 1997) | | | |
| mesial | 2.5 (0.7) | 2.7 (0.6) | -0.2 (0.4) |
| distal | 2.3 (0.8) | 2.8 (0.5) | -0.5 (0.8)* |

* $p < 0.01$, ** $p < 0.001$

Soft tissue dimensions

The thickness of the facial mucosa, assessed at a level corresponding to the bottom of the probeable pocket, was greater at the implants than at the teeth (2.0 mm versus 1.1 mm; $p < 0.001$) (Table 9). The difference was most evident in the central incisor

position. Diameter discrepancies between the implant and the root to be replaced could be one reason for the different thickness of the facial mucosa. Furthermore, it has been suggested that the head of the implant should be positioned in line with the labial root surface of neighboring teeth and apical to their cervix in order to be able to achieve a favorable emergence profile of the crown and a natural-looking soft tissue profile (Palacci et al. 1995). In the present patient material such a positioning of the implants was obviously not obtained in the majority of the cases since the implants had a thicker facial mucosa than the contralateral teeth.

With respect to the dimension of the papillae the data revealed that the papilla at the distal aspect of the implants showed a lower height than that at the corresponding site of contra-lateral teeth ($p < 0.01$). Since a majority of the single implants were placed in a central incisor position, the comparison at the mesial aspect of implants and teeth is hampered by the fact that the papilla is shared between the two units, and that the loss of a central incisor most likely affects the papilla height at the mesial aspect of the other central incisor. Furthermore, the reduced height of the distal papilla was most marked for implant-supported restorations in the central incisor position, both in comparison to the distal papilla at the contra-lateral tooth and to the mesial papilla at the implant. It is suggested that the anatomy of adjacent teeth (e.g. the diameter of the root, the proximal outline/curvature of the cemento-enamel junction/connective tissue attachment level), and the width of the space between the implant unit and the natural tooth, are factors that may influence the dimension of the papilla lateral to an implant. Palmer et al. (2007) also found differences between mesial and distal papillae at single-tooth implant restorations and attributed this to an approximately 1.5 mm difference in contact point distance from the implant head.

A statistically significant increase in the mean value for Papilla Index – describing the degree of soft tissue fill - was observed at both mesial and distal sites of the single implants during the follow-up period, which corroborates finding reported by other authors (e.g. Jemt 1997, Jemt et al. 1999, Choquet et al. 2000, Henriksson & Jemt 2004, Cardaropoli et al. 2006). Since signs of soft tissue inflammation at proximal sites were frequent findings in the present patient material (BoP 60% for both implants and teeth; Table 10), it cannot be ruled out that plaque-induced inflammation and an associated swelling of the soft tissue could have accounted for the improved soft tissue height, as suggested in a publication by Jemt (1997). However, the

observed increase in tissue volume at the follow-up examination may also partly be due to a remodeling potential of the soft tissues in order to establish a proper biological height after the surgical manipulation in conjunction with the abutment connection. To consider is also the fact that the assessment of the Papilla Index is made in relation to a reference line determined by the facial soft tissue margin at adjacent teeth (Jemt 1997), and that the improved soft tissue fill in the proximal sites might have been overestimated if retraction of the facial soft tissue margin at the adjacent teeth had taken place.

Table 10. Soft tissue conditions at implant-supported single crown restorations and contralateral teeth. Mean values (SD).

| Variable | Implants | Teeth | Difference |
|-------------------------|-----------|-----------|-------------|
| Probing depth (mm) | | | |
| facial | 2.9 (0.6) | 2.5 (0.7) | 0.4 (0.8) |
| lingual | 3.5 (0.8) | 2.1 (0.5) | 1.4 (0.9)** |
| proximal | 3.5 (0.7) | 2.5 (0.6) | 1.0 (0.8)* |
| Plaque (%) | | | |
| facial | 14 | 14 | |
| lingual | 24 | 16 | |
| proximal | 31 | 38 | |
| Bleeding on probing (%) | | | |
| facial | 67 | 19 | |
| lingual | 62 | 5 | |
| proximal | 60 | 60 | |

$p < 0.01$, ** $p < 0.001$

Interestingly, the VAS scoring of the patients' satisfaction with the appearance of their single implant-supported crown restoration revealed a high value; median value 96%, range 70-100%. Hence, the observed differences in clinical crown height and soft tissue topography between implant-supported single-tooth replacements and the contra-lateral natural tooth may in most patients be of minor importance for the appreciation of the esthetic outcome of implant therapy.

Study II

Smile line categories

Thirty-one percent of the patients were classified as having a high smile, 17 % a low smile, and 52 % an average smile.

Abutment visibility

The metal part of one CeraOne[®] abutment and the ceramics of 4 CerAdapt[®] abutments were found to be exposed supra-mucosally. However, the 5 patients who presented with oral exposure of the abutment did not deviate in their assessment of "overall satisfaction with appearance" from the patients without abutment exposure. The most likely explanation for the lack of difference in "overall satisfaction with appearance" despite exposure of the abutment may be that none of the 5 patients was characterized as having a high smile line.

Patient satisfaction

All variables assessed by the patients, except "importance of abutment visibility", showed a mean value above 90% and a median value close to 100%. The range of the assessments was smallest for "overall satisfaction with the crown" (84-100), and widest for "importance of abutment visibility" (0-100). One and the same patient was consistently responsible for the lowest recordings.

The patients' high satisfaction with the treatment result in this patient material may be attributed to the use of the specially developed abutments for optimizing the esthetic results (CeraOne[®] or CerAdapt[®] abutments) and the placement of the crown border in a submucosal position, whenever possible. Furthermore, the all-ceramic crowns used for the majority of the patients are usually regarded as providing better esthetics than metal ceramic crowns or acrylic resin crowns. In addition, none of the patients had a ridge lap type of the facings or severely over-contoured form of the crown due to the positioning problem of the implants.

On the question regarding preference between function and appearance of the implant-supported single-tooth replacement, 62% of the patients marked preference for function. Female patients usually expressed preference for appearance, while males considered function to be more important than esthetics. Similar observations

were reported in other publications (e.g. Neumann et al. 1989, Vallittu et al. 1996, Wagner et al. 1996, Carlsson et al. 1998).

Five of the 29 patients responded positively on the question whether they wanted to change something with respect to the appearance of the implant-supported crown, and remarked on color, crown rotation, soft tissue recession, lack of interdental papilla or difference in appearance in comparison with adjacent teeth. For these 5 patients, the "overall satisfaction with appearance" was found to be significantly lower than for the remaining group of patients (85% versus 96%, $p < 0.05$).

In studies attempting to identify factors accounting for the patient's esthetic satisfaction with natural teeth, age, gender and "tooth shade" have been reported to be the factors that show the strongest influence on satisfaction with appearance (Neumann et al. 1989, Dunn et al. 1996, Vallittu et al. 1996). In the present study on single implant-supported crown restorations, none of these factors were found to have a significant impact on the patient's satisfaction with the esthetic outcome of the therapy. One reason for this difference could be that, in the studies referred to, the patients assessed the dentition in general, while in the present study only the implant-supported crown was the target for the assessment.

Professional assessments of esthetics

The five prosthodontists could correctly locate the single implant-supported crowns at the smile view in 89 % of the cases. In patients with a low smile line, 70% of the implant-supported crowns were recognized, while the corresponding figure for patients with a high smile was 97%. "Satisfaction with appearance" of the implant-supported crowns in patients with an average or a low smile was rated significantly higher than that for patients with a high smile ($p < 0.01$), when the assessment was done based on the extra-oral view only.

The results of the prosthodontists' assessments performed on the intra-oral views revealed lower mean and median values and wider ranges for all variables in comparison with those of the patients' assessments. "Surface texture of the crown" was the variable that rendered the highest satisfaction score, while the lowest score was obtained for "surrounding soft tissue appearance". With regard to the color of the crown, the color of incisal half of the crown rendered a higher degree of satisfaction than that of the cervical half of the crown ($p < 0.001$).

A multiple regression analysis was applied to evaluate the influence of various variables on the "overall satisfaction with appearance" at the intra-oral view. The model explained 76% of the variance in "overall satisfaction with appearance" ($p < 0.0001$). "Surrounding soft tissue appearance", "form of the crown", "contact point position", and "color of the incisal half of the crown" were all found to have a statistically significant influence on the "overall satisfaction with appearance". Hence, the findings emphasize the significance of the appearance of the cervical part of the crown and the surrounding soft tissue in the professional judgment of the esthetic outcome of implant therapy.

Comparison between patients' and professional assessments

Three variables addressed by the questions to both patients and dentists could be compared: "color", "crown form", and "overall satisfaction with appearance". Box and whisker plots of the data (Fig.4) illustrate that, for all three variables, the patients displayed higher scores, as well as lower variance, with regard to satisfaction than the dentists. This finding may be interpreted to indicate that the dentists are more critical and/or place greater emphasis on certain factors in their esthetic evaluation than the patients.

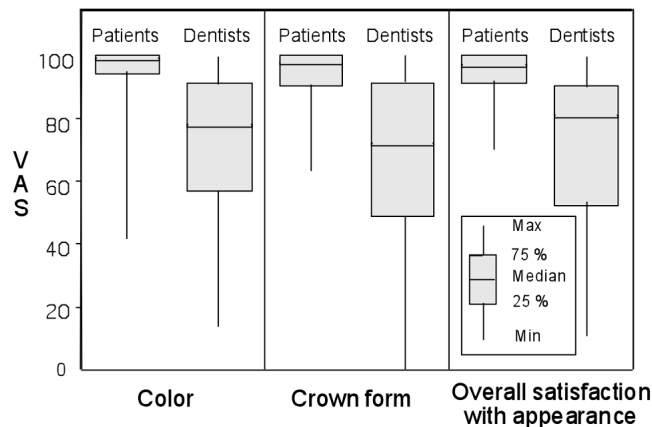


Fig. 4. Box and whisker plots of the 3 variables addressed in the questions to both patients and dentists. The dentists' assessment of color represents the mean value for the cervical and incisal half of the crown.

Study III

Bone topography

The mean marginal bone loss at the implants amounted to 0.1 mm at both 5- and 8-year of follow-up. These figures with respect to peri-implant bone alterations are well in agreement with data from other longitudinal studies on the use of Astra Tech ST[®] implants for single tooth replacement (e.g. Palmer et al. 2000, Gotfredsen 2004, Norton 2006, Cooper et al. 2007), and demonstrate an excellent long-term performance of the implant with regard to maintenance of the marginal bone level.

The mean bone loss at the tooth sites adjacent to the implants was 0.0 mm at 5 years and 0.1 mm at 8 years of follow-up, respectively. The finding of maintained support level is important in relation to the esthetic outcome of implant-supported single-tooth replacements because loss of marginal bone and periodontal support at the adjacent teeth may cause recession of the proximal soft tissue.

The multiple regression analysis failed to identify significant explanatory factors for the observed variance in bone level change at the adjacent teeth during the follow-up period ($p=0.074$). Other studies utilizing single implants with a platform connection between implant and abutment reported increased degree of bone loss at the adjacent tooth when the horizontal implant-tooth distance decreased (Esposito et al. 1993, Henry et al. 1996, Andersson et al. 1995 & 1998, Thilander et al. 2001, Krennmair et al. 2003). In these studies it was reported that the bone loss showed large variation between subjects and that the recorded bone loss differed significantly between the anterior (mean 1.6 mm) and posterior tooth regions (mean 0.4 mm) (Krennmair et al. 2003). Furthermore, from radiographic examinations of young individuals who received their single implant therapy during adolescent, Thilander et al. (2001) reported 1.4-2.2 mm bone loss between crown cementation and 10-year follow-up at adjacent teeth to single implants placed in incisors position. Esposito et al. (1993) on the other hand found that the increased bone loss at adjacent teeth was confined to the time period before loading and that no increased bone loss was detected during the period of functioning loading. The latter finding is supported by data from a 3-year retrospective study of adult subjects (Cardaropoli et al. 2003) and the current study showing lack of a relationship between the inter-unit distance and longitudinal marginal bone loss at the proximal tooth surface next to an implant.

Change in vertical relationship between the single implant and adjacent teeth

In relation to the single implant, the vertical position of adjacent teeth had changed coronally on average 0.1 mm (S.D. 0.2) at 1 year, 0.3 mm (0.3) at 5 years, and 0.4 mm (0.5) at 8 years. The % frequency of cases showing a coronal shift in position was 29%, 55%, and 58% at 1, 5 and 8 years, respectively. The magnitude of vertical change in the position of the teeth was significantly greater in the incisor compared to the premolar tooth region (0.37 vs. 0.19 mm at 5 years, 0.53 vs. 0.15 mm at 8 years), but not significantly associated with gender or age.

Infra-occlusion positioning of the single implant in relation to adjacent teeth has been observed in longitudinal studies of adolescents and young adults (Thilander et al. 1999, 2001), but also in mature adults (Bernard et al. 2004). Similar to ankylotic teeth, the osseo-integrated single implant faces the risk to be positioned in infra-occlusion by time because of continuous eruption of the adjacent teeth and/or facial bone growth (Kawanami et al. 1999, Heij et al. 2006). Jemt et al. (2007) reported from a 15-year follow-up study that all females and 45 % of males showed vertical change of the tooth adjacent to a single implant. Bernard et al. (2004) found that in all examined subjects the adjacent teeth to single implants had changed in vertical position during a mean follow-up period of 4.2 years, ranging from 0.12 mm to 1.86 mm. Thilander et al. (1999) observed a mean vertical difference of 0.46 mm after 3 years and 0.95 mm after 8 years in 10 adolescents with 15 single implants in incisor position. The reason for the less frequent and smaller magnitude of vertical change observed in the current study may be due to the fact that single implants in premolar position were included, while the studies referred to were limited to single implants in anterior region, i.e., canine to canine (Bernard et al. 2004, Jemt et al. 2007) or only incisors (Thilander et al. 1999). In fact, in the current study more pronounced vertical change of adjacent teeth was observed in incisor than premolar position (0.4 mm vs. 0.2 mm at 5-year follow-up, 0.5 mm vs. 0.2 mm at 8-year follow-up).

The binary logistic regression analysis of factors with potential relationship to the presence of a vertical change of adjacent tooth relative the single implant at 5 years revealed that presence of infra-occlusion of the implant restoration was more common in incisor position (OR=8.7; $p=0.025$), while gender and age showed no significant association. Jemt et al. (2007) found a higher incidence of infra-occlusion in females than males, and this was suggested to be due to a greater increase of anterior face

height and posterior rotation of the mandible in the female group. The mean age of the subjects in our study was 40 years (S.D. 12.6, range 19-71) at the time of implant placement, compared to 25.4 years (S.D. 10) in the study by Jemt et al. (2007). Hence, because of a higher age of our patient material, increase of anterior face height and posterior rotation of the mandible potentially affecting the vertical change in the female group might be less likely, and may explain the difference in frequency and amount of the vertical change in the current study in comparison to studies including adolescents or young adults (Thilander et al. 1999, Bernard et al. 2004, Jemt et al. 2007).

Study IV

Bone topography

Tooth/implant units

The mean marginal bone loss at the tooth and implant during the 5-year follow-up period was 0.1 mm (95% CI -0.26/-0.02) and 0.4 mm (95% CI -0.84/-0.09), respectively. The mid-proximal bone crest level showed a mean apical displacement of 0.2 mm (95% CI -0.26/-0.07). The most coronal proximal bone level was always found adjacent to the tooth. Multiple regression model formulated to explore potential effects of various variables (bone level change at implant, horizontal and vertical tooth-implant distances) on the 5-year bone level alteration at the tooth failed to reach statistical significance ($p=0.61$).

Since the patients involved in the current study had all been edentulous in the area for implant therapy for a period of at least one year, it is unlikely that the marginal bone remodeling that can be expected to take place following extraction of a tooth (Schropp et al. 2003) has had a significant effect on observed bone alterations at the implants and the adjacent tooth. Furthermore, all patients were throughout the period of monitoring enrolled in an individually designed supportive periodontal therapy program (Lang & Lindhe 2003) that called for examination of the teeth, the implants and the surrounding soft tissues once every 4-6 months, and all patients showed low plaque and soft tissue inflammation scores at the follow-up examinations (Wennström et al. 2004).

A few previous studies (Esposito et al. 1993, Andersson et al. 1998) reported increased bone loss at the tooth with decreased distance to the implant, however this loss was confined to the time period between implant placement and crown placement, and no further loss was observed during the subsequent follow-up period. Also data reported from a 3-year retrospective study by Cardaropoli et al. (2003) support the interpretation of a lack of a relationship between the inter-unit distance and longitudinal marginal bone loss at the proximal tooth surface next to an implant.

Implant/implant units

The mean 5-year bone level change amounted to -0.5 mm (95% CI -0.81/-0.17) at the implants and -0.3 mm (95% CI -0.47/-0.17) at the mid-proximal bone crest. Multiple regression analysis explained 24 % of the variance in the 5-year mid-proximal bone crest change, and revealed that peri-implant bone level change ($p < 0.001$) and the horizontal inter-implant distance ($p < 0.05$) significantly influenced the outcome variable.

Sub-analysis according to inter-unit distance identified a borderline at 2 mm with respect to loss in height in bone crest level; 0.7 mm (S.D. 0.8) mean loss in mid-proximal bone crest height for units with < 2 mm inter-unit distance compared to 0.2 mm (0.3) for sites with ≥ 2 mm inter-unit distance. The finding partly corroborates observations reported in studies related to the use of implants with a platform abutment connection (Tarnow et al. 2000, Cardaropoli et al. 2003) suggesting a borderline at 3 mm inter-implant distance for more advanced loss in bone crest height, but also indicates that the use of a conical seal designed implant/abutment interface may allow a closer placement of two adjacent implants without altered risk for reduced proximal bone crest level (following prosthesis insertion). Other features of the marginal portion of the implant, e.g. surface modifications/roughness (Hansson & Norton 1999) and micro-threading (Hansson 1999, Palmer et al. 2000, Shin et al. 2006), may also be of significance for maintenance of the peri-implant bone level and minimal bone crest resorption. The implants used in the current study, however, were not designed with microthreading. In this context also the position of the implant/abutment junction in relation to the surrounding bone level at implant placement must be taken into consideration (Berglundh et al. 2005).

Study V

The data describing the soft tissue conditions revealed that the frequency of bleeding on probing was low throughout the observation period, although an increase in the frequency was observed for proximal tissue units at the 3-year follow-up examination (12-19%). The probing depths at the implants showed only minor alterations during the observation period. In comparison to the adjacent teeth, the implants showed at 3 years statistically significantly deeper probing depths and a greater thickness of the facial mucosa.

Soft tissue assessments

After completion of the implant placement surgery, the mean soft tissue height assessed from the implant/abutment level varied between 2.5-2.8 mm for the various sites. At facial implant sites, the soft tissue height showed a statistically significant decrease over the first 6 months (mean 0.6 mm), whereas at proximal sites a significantly increased height was observed at *tooth-facing sites* (mean 1.1 mm) but no change at *implant-facing sites*. Between 6 months (placement of the permanent FPD) and 3 years no significant changes in the soft tissue level at facial and proximal sites were observed. The findings are partly contradictory to observations made in a prospective study by Small & Tarnow (2000), in which a mean recession of 0.5-0.8 mm at proximal sites 6 months after implant placement/abutment connection surgery was reported. However, the studies are difficult to compare since in the study by Small & Tarnow (2000), tooth-facing and implant-facing sites were not analyzed separately and patients with fixed as well as removable prostheses were included. With regard to changes in the soft tissue height at facial implant sites, a similar magnitude of peri-implant marginal soft tissue recession was reported after crown installation in studies that used a two-stage surgical protocol for implant placement and prosthesis delivery about 1 months after the second stage surgery for abutment connection (Bengazi et al. 1996, Grunder 2000, Small & Tarnow 2000, Cardaropoli et al. 2006, *Study I*). Hence, these findings indicate that the change in the facial position of the soft tissue margin is primarily related to the healing phase following the surgical intervention, and likely the result of a modeling process of the peri-implant soft tissues for its adaptation to adequate biological dimensions in accord to the concept of “biological width” (Berglundh & Lindhe 1996, Cochran et al. 1997) and the thickness of the supracrestal mucosa (Bengazi et al. 1996, Cardaropoli et al. 2006).

At proximal sites, the soft tissue height increased at tooth-facing sites (mean 1.1 mm) during the time interval from implant placement surgery to 6-month follow-up, but no significant change was observed at implant-facing sites. Furthermore, regression analysis revealed that the proximal bone crest level influenced the proximal soft tissue height assessed from the implant/abutment level at 6 months ($p < 0.001$). Taking into account that at 6 months the proximal bone crest was located 0.7 mm apical to the implant/abutment level, the mean supra-crestal height of the soft tissue amounted to 3.4 mm in the inter-implant site, and subsequent to the placement of the definitive FPD at 6 months no further significant alterations in soft tissue dimension was observed. A similar mean dimension of the supra-crestal soft tissue at inter-implant sites (3.1-3.4 mm) was reported by Tarnow et al. (2003) and Lee et al. (2006) based on transmucosal probing assessments (“sounding”).

The Papilla index scorings revealed limited alterations in the distribution of the various scores between 6 months and 3 years. A slight reduction in score 1 was observed during the observation period at both tooth/implant and inter-implant units, but comparatively few units showed complete papilla fill (score 3) at 3 years (about 20% of tooth/implant sites and <10% of inter-implant sites). Previous reports on single-tooth replacements (e.g. Jemt 1997, Choquet et al. 2001, Cardaropoli et al. 2006) showed an improved papilla fill after crown placement (about 1 month following abutment surgery). Taken together with our findings of gain in proximal soft tissue height mainly during the early phase of healing after the 1-stage implant placement surgery, the observations indicate that the topography of the proximal soft tissue in most cases might establish its final outline within an interval of 6 months. In this context it should however also be acknowledged that the patient included in our study showed various degree of attachment loss at the neighboring teeth, and were instructed to use interproximal brushes for daily cleaning, which may have contributed to the low prevalence of proximal sites with complete soft tissue fill.

Radiographic bone level assessments

Immediately following implant placement the proximal bone crest was on average even with the implant/abutment level at inter-implant units, and 1.6 mm coronal to the reference at tooth/implant units. At the 3-year follow-up examination, the height of the proximal bone crest was maintained more or less unaltered at tooth/implant units,

while a mean loss in height of 0.6 mm was observed at inter-implant units, and confined to the first 6 months after implant placement. The multivariate analysis revealed horizontal inter-unit distance and peri-implant bone level change as significant explanatory factors for loss in proximal bone crest level over the 3 years.

The findings with regard to bone crest changes in the current study are in large in line with observations previously reported in the literature. Cardaropoli et al. (2003) reported on marginal bone alterations following a 2-stage implant placement surgical procedure and made radiographic assessments from the time of abutment connection to 3 years of follow-up. They found a mean bone crest reduction of 0.5 mm at inter-implant units compared to 0.3 mm at tooth/implant units, and that the degree of loss in bone crest height was significantly associated with reduced horizontal distance between two implants but not between implant and tooth. From a cross-sectional study of the height of the inter-implant bone crest in relation to the inter-implant distance, Tarnow et al. (2000) reported a lower height of the bone crest in areas with an inter-implant distance of ≤ 3 mm as compared to areas with >3 mm between the implants, and suggested that this difference may be the result of lateral bone loss at the implants. With respect to tooth/implant units, studies on single-tooth replacements in the anterior maxilla utilizing machined Brånemark implants (Esposito et al. 1993, Andersson et al. 1998, Thilander et al. 2001) reported an increased bone loss at the adjacent tooth with reduced distance between the implant and the tooth. However, Cardaropoli et al. (2003) could not verify such a relationship for tooth/implant units in a 3-year study of implant-supported fixed partial dentures, in which the baseline was defined as the time of prosthesis placement.

MAIN CONCLUSIONS

- Only minor differences in crown form between implant-supported single-tooth replacements and contra-lateral natural teeth were found, whereas the topography and appearance of the periodontal/peri-impant soft tissues showed pertinent differences. However, despite observed differences in the outline of the soft tissue margin, the patients' appreciation of the esthetic outcome of the implant therapy was rated high (*Study I*).
- The appreciation of the esthetic outcome of the implant-supported single-tooth replacements was rated higher by patients than by prosthodontists. Factors often considered by professionals to be of significance for the esthetic result of restorative therapy may not be of decisive importance for the patients's satisfaction (*Study II*).
- The marginal bone level at teeth adjacent to single implants with a micro-threaded conical portion was not influenced by horizontal and vertical tooth-implant distances. Continuous eruption of adjacent teeth may result in infra-occlusal positioning of a single implant restoration (*Study III*).
- Loss in height of the mid-proximal bone crest in inter-implant areas was influenced by the bone loss at the two bordering implants and the horizontal inter-unit distance, while no such relationships were evident for the proximal area between implant and tooth (*Study IV*).
- Soft and hard tissue alterations occurred predominately during the first 6 months following 1-stage implant placement surgery. Presence of a tooth next to the implant positively affected the maintenance of the proximal bone crest level and the topography of the inter-unit soft tissues. At the proximal site between two implants, reduced distance between the implants and peri-implant bone loss negatively affected the maintenance of the proximal bone crest level and thereby the height of the soft tissues (*Study V*).

CONCLUDING REMARKS

Since the patients' satisfaction with the esthetic outcome of the implant therapy evaluated in the present studies was very high, observed differences in clinical crown height and soft tissue topography in relation to the contra-lateral natural tooth could, in most patients, be considered to be of minor importance for his/her appreciation of the esthetic outcome of the restorative treatment. In the professional judgment of the esthetic outcome, on the other hand, these factors were found to be of significance. These observations suggest that evaluations of the esthetic outcome of restorative therapies should be focused on assessments made by the patients rather than professionals, since factors often considered by professionals to be of significance for the esthetic results of restorative therapy may not be of decisive importance for the patients' satisfaction.

Considering that continuous eruption of the teeth adjacent to a single implant restoration, particularly in the anterior part of the jaws, may result in infra-occlusal positioning of the implant-supported crown, it is important to inform the patient about the risk of a future esthetic complication.

In relation to the esthetic outcome, the presence of a tooth next to the implant positively affects the maintenance of the proximal bone crest level and the topography of the inter-unit soft tissues both at single implant-supported restorations and tooth-implant units of multi-implant supported reconstruction. In the proximal area between two implants the bone crest serves as a foundation for the soft tissues, and to preserve optimal bone height, implants should be placed with adequate inter-implant distance.

From an esthetic perspective, knowledge about the biology of the peri-implant tissues is crucial. As potential factors influencing the soft tissue topography, facio-lingual dimensions of the peri-implant tissues i.e., the thickness of facial soft tissues and bone crest as well as implant dimension and design should be considered in future research.

REFERENCES

- Abrahamsson, I., Berglundh, T., Wennstrom, J. & Lindhe, J. (1996) The peri-implant hard and soft tissues at different implant systems. A comparative study in the dog. *Clinical Oral Implants Research* **7**: 212-219.
- Abrahamsson, I. & Berglundh, T. (2006) Tissue characteristics at microthreaded implants: An experimental study in dogs. *Clinical Implant Dentistry and Related Research* **8**: 107-113.
- Adell, R., Lekholm, U., Rockler, B., Branemark, P.I., Lindhe, J., Eriksson, B. & Sbordone, L. (1986) Marginal tissue reactions at osseointegrated titanium fixtures (i). A 3-year longitudinal prospective study. *International Journal of Oral and Maxillofacial Surgery* **15**: 39-52.
- Albashaireh, Z.S., Alhusein, A.A. & Marashdeh, M.M. (2009) Clinical assessments and patient evaluations of the esthetic quality of maxillary anterior restorations. *International Journal of Prosthodontics* **22**: 65-71.
- Andersson, B., Odman, P., Lindvall, A.M. & Lithner, B. (1995) Single-tooth restorations supported by osseointegrated implants: Results and experiences from a prospective study after 2 to 3 years. *International Journal of Oral and Maxillofacial Implants* **10**: 702-711.
- Andersson, B., Odman, P., Lindvall, A.M. & Branemark, P.I. (1998) Cemented single crowns on osseointegrated implants after 5 years: Results from a prospective study on ceraone. *International Journal of Prosthodontics* **11**: 212-218.
- Anusavice, K.J. (1996) Dental ceramics. In: Anusavice, K.J. eds. *Phillip's science of dental materials*, pp 583-618. Philadelphia: W.B. Saunders.
- Apse, P., Zarb, G.A., Schmitt, A. & Lewis, D.W. (1991) The longitudinal effectiveness of osseointegrated dental implants. The toronto study: Peri-implant mucosal response. *International Journal of Periodontics and Restorative Dentistry* **11**: 94-111.
- Avivi-Arber, L. & Zarb, G.A. (1996) Clinical effectiveness of implant-supported single-tooth replacement: The toronto study. *International Journal of Oral and Maxillofacial Implants* **11**: 311-321.
- Belser, U.C., Buser, D., Hess, D., Schmid, B., Bernard, J.P. & Lang, N.P. (1998) Esthetic implant restorations in partially edentulous patients--a critical appraisal. *Periodontology* **2000** **17**: 132-150.
- Belser, U.C., Schmid, B., Higginbottom, F. & Buser, D. (2004a) Outcome analysis of implant restorations located in the anterior maxilla: A review of the recent literature. *International Journal of Oral and Maxillofacial Implants* **19 Suppl**: 30-42.
- Belser, U., Buser, D. & Higginbottom, F. (2004b) Consensus statements and recommended clinical procedures regarding esthetics in implant dentistry. *International Journal of Oral and Maxillofacial Implants* **19 Suppl**: 73-74.
- Belser, U.C., Grutter, L., Vailati, F., Bornstein, M.M., Weber, H.P. & Buser, D. (2009) Outcome evaluation of early placed maxillary anterior single-tooth implants using objective esthetic criteria: A cross-sectional, retrospective study in 45 patients with a 2- to 4-year follow-up using pink and white esthetic scores. *Journal of Periodontology* **80**: 140-151.
- Bengazi, F., Wennstrom, J.L. & Lekholm, U. (1996) Recession of the soft tissue margin at oral implants. A 2-year longitudinal prospective study. *Clinical Oral Implants Research* **7**: 303-310.
- Berglundh, T. & Lindhe, J. (1996) Dimension of the periimplant mucosa. Biological width revisited. *Journal of Clinical Periodontology* **23**: 971-973.
- Berglundh, T., Abrahamsson, I. & Lindhe, J. (2005) Bone reactions to longstanding functional load at implants: An experimental study in dogs. *Journal of Clinical Periodontology* **32**: 925-932.
- Bernard, J.P., Schatz, J.P., Christou, P., Belser, U. & Kiliaridis, S. (2004) Long-term vertical changes of the anterior maxillary teeth adjacent to single implants in young and mature adults. A retrospective study. *Journal of Clinical Periodontology* **31**: 1024-1028.
- Blomberg, S. (1985) Psychiatric aspects of patients treated with bridges on osseointegrated

- fixtures. *Swedish Dental Journal. Supplement* **28**: 183-192.
- Boudrias, P. (1993) The implant-supported single-tooth restoration. Preoperative evaluation and clinical procedure. *Dental Clinics of North America* **37**: 497-511.
- Bouri, A., Jr., Bissada, N., Al-Zahrani, M.S., Faddoul, F. & Nouneh, I. (2008) Width of keratinized gingiva and the health status of the supporting tissues around dental implants. *International Journal of Oral and Maxillofacial Implants* **23**: 323-326.
- Bragger, U., Burgin, W.B., Hammerle, C.H. & Lang, N.P. (1997) Associations between clinical parameters assessed around implants and teeth. *Clinical Oral Implants Research* **8**: 412-421.
- Brisman, A.S. (1980) Esthetics: A comparison of dentists' and patients' concepts. *Journal of the American Dental Association* **100**: 345-352.
- Buser, D., Martin, W. & Belser, U.C. (2004) Optimizing esthetics for implant restorations in the anterior maxilla: Anatomic and surgical considerations. *International Journal of Oral and Maxillofacial Implants* **19 Suppl**: 43-61.
- Buser, D., Halbritter, S., Hart, C., Bornstein, M.M., Grutter, L., Chappuis, V. & Belser, U.C. (2009) Early implant placement with simultaneous guided bone regeneration following single-tooth extraction in the esthetic zone: 12-month results of a prospective study with 20 consecutive patients. *Journal of Periodontology* **80**: 152-162.
- Cardaropoli, G., Wennstrom, J.L. & Lekholm, U. (2003) Peri-implant bone alterations in relation to inter-unit distances. A 3-year retrospective study. *Clinical Oral Implants Research* **14**: 430-436.
- Cardaropoli, G., Lekholm, U. & Wennstrom, J.L. (2006) Tissue alterations at implant-supported single-tooth replacements: A 1-year prospective clinical study. *Clinical Oral Implants Research* **17**: 165-171.
- Carlsson, G.E., Wagner, I.V., Odman, P., Ekstrand, K., MacEntee, M., Marinello, C., Nanami, T., Ow, R.K., Sato, H., Speer, C., Strub, J.R. & Watanabe, T. (1998) An international comparative multicenter study of assessment of dental appearance using computer-aided image manipulation. *International Journal of Prosthodontics* **11**: 246-254.
- Chang, L.C. (2007) The association between embrasure morphology and central papilla recession. *Journal of Clinical Periodontology* **34**: 432-436.
- Chang, L.C. (2008) Assessment of parameters affecting the presence of the central papilla using a non-invasive radiographic method. *Journal of Periodontology* **79**: 603-609.
- Chen, S.T., Darby, I.B. & Reynolds, E.C. (2007) A prospective clinical study of non-submerged immediate implants: Clinical outcomes and esthetic results. *Clinical Oral Implants Research* **18**: 552-562.
- Cho, H.S., Jang, H.S., Kim, D.K., Park, J.C., Kim, H.J., Choi, S.H., Kim, C.K. & Kim, B.O. (2006) The effects of interproximal distance between roots on the existence of interdental papillae according to the distance from the contact point to the alveolar crest. *Journal of Periodontology* **77**: 1651-1657.
- Choquet, V., Hermans, M., Adriaenssens, P., Daelemans, P., Tarnow, D.P. & Malevez, C. (2001) Clinical and radiographic evaluation of the papilla level adjacent to single-tooth dental implants. A retrospective study in the maxillary anterior region. *Journal of Periodontology* **72**: 1364-1371.
- Chung, D.T., Bogle, G., Bernardini, M., Stephens, D., Riggs, M.L. & Egelberg, J.H. (2003) Pain experienced by patients during periodontal maintenance. *Journal of Periodontology* **74**: 1293-1301.
- Cibirka, R.M., Razzoog, M. & Lang, B.R. (1997) Critical evaluation of patient responses to dental implant therapy. *Journal of Prosthetic Dentistry* **78**: 574-581.
- Cochran, D.L., Hermann, J.S., Schenk, R.K., Higginbottom, F.L. & Buser, D. (1997) Biologic width around titanium implants. A histometric analysis of the implanto-gingival junction around unloaded and loaded nonsubmerged implants in the canine mandible. *Journal of Periodontology* **68**: 186-198.
- Conny, D.J., Tedesco, L.A., Brewer, J.D. & Albino, J.E. (1985) Changes of attitude in fixed prosthodontic patients. *Journal of Prosthetic Dentistry* **53**: 451-454.
- Conrad, H.J., Seong, W.J. & Pesun, I.J. (2007) Current ceramic materials and systems with

- clinical recommendations: A systematic review. *Journal of Prosthetic Dentistry* **98**: 389-404.
- Cooper, L., Felton, D.A., Kugelberg, C.F., Ellner, S., Chaffee, N., Molina, A.L., Moriarty, J.D., Paquette, D. & Palmqvist, U. (2001) A multicenter 12-month evaluation of single-tooth implants restored 3 weeks after 1-stage surgery. *International Journal of Oral and Maxillofacial Implants* **16**: 182-192.
- Cooper, L.F., Ellner, S., Moriarty, J., Felton, D.A., Paquette, D., Molina, A., Chaffee, N., Asplund, P., Smith, R. & Hostner, C. (2007) Three-year evaluation of single-tooth implants restored 3 weeks after 1-stage surgery. *International Journal of Oral and Maxillofacial Implants* **22**: 791-800.
- Cooper, L.F. (2008) Objective criteria: Guiding and evaluating dental implant esthetics. *Journal of Esthetic and Restorative Dentistry* **20**: 195-205.
- Cordaro, L., Torsello, F., Mirisola Di Torresanto, V. & Rossini, C. (2006) Retrospective evaluation of mandibular incisor replacement with narrow neck implants. *Clinical Oral Implants Research* **17**: 730-735.
- de Bruyn, H., Collaert, B., Linden, U. & Bjorn, A.L. (1997) Patient's opinion and treatment outcome of fixed rehabilitation on branemark implants. A 3-year follow-up study in private dental practices. *Clinical Oral Implants Research* **8**: 265-271.
- De Bruyn, H., Linden, U., Collaert, B. & Bjorn, A.L. (2000) Quality of fixed restorative treatment on branemark implants. A 3-year follow-up study in private dental practices. *Clinical Oral Implants Research* **11**: 248-255.
- de Grandmont, P., Feine, J.S., Tache, R., Boudrias, P., Donohue, W.B., Tanguay, R. & Lund, J.P. (1994) Within-subject comparisons of implant-supported mandibular prostheses: Psychometric evaluation. *Journal of Dental Research* **73**: 1096-1104.
- de Oliveira, R.R., Novaes, A.B., Jr., Papalexiou, V., Muglia, V.A. & Taba, M., Jr. (2006) Influence of interimplant distance on papilla formation and bone resorption: A clinical-radiographic study in dogs. *Journal of Oral Implantology* **32**: 218-227.
- De Rouck, T., Collys, K. & Cosyn, J. (2008) Immediate single-tooth implants in the anterior maxilla: A 1-year case cohort study on hard and soft tissue response. *Journal of Clinical Periodontology* **35**: 649-657.
- DeAngelo, S.J., Kumar, P.S., Beck, F.M., Tatakis, D.N. & Leblebicioglu, B. (2007) Early soft tissue healing around one-stage dental implants: Clinical and microbiologic parameters. *Journal of Periodontology* **78**: 1878-1886.
- Degidi, M., Nardi, D. & Piattelli, A. (2008a) Peri-implant tissue and radiographic bone levels in the immediately restored single-tooth implant: A retrospective analysis. *Journal of Periodontology* **79**: 252-259.
- Degidi, M., Novaes, A.B., Jr., Nardi, D. & Piattelli, A. (2008b) Outcome analysis of immediately placed, immediately restored implants in the esthetic area: The clinical relevance of different interimplant distances. *Journal of Periodontology* **79**: 1056-1061.
- Dueled, E., Gotfredsen, K., Trab Damsgaard, M. & Hede, B. (2009) Professional and patient-based evaluation of oral rehabilitation in patients with tooth agenesis. *Clinical Oral Implants Research* **20**: 729-736.
- Dunn, W.J., Murchison, D.F. & Broome, J.C. (1996) Esthetics: Patients' perceptions of dental attractiveness. *Journal of Prosthodontics* **5**: 166-171.
- Eger, T., Muller, H.P. & Heinecke, A. (1996) Ultrasonic determination of gingival thickness. Subject variation and influence of tooth type and clinical features. *Journal of Clinical Periodontology* **23**: 839-845.
- Ekfeldt, A., Carlsson, G.E. & Borjesson, G. (1994) Clinical evaluation of single-tooth restorations supported by osseointegrated implants: A retrospective study. *International Journal of Oral and Maxillofacial Implants* **9**: 179-183.
- Ekfeldt, A., Johansson, L.A. & Isaksson, S. (1997) Implant-supported overdenture therapy: A retrospective study. *International Journal of Prosthodontics* **10**: 366-374.
- Engquist, B., Nilson, H. & Astrand, P. (1995) Single-tooth replacement by osseointegrated branemark implants. A retrospective study of 82 implants. *Clinical Oral Implants Research* **6**: 238-245.

- Engquist, B., Astrand, P., Dahlgren, S., Engquist, E., Feldmann, H. & Grondahl, K. (2002) Marginal bone reaction to oral implants: A prospective comparative study of astra tech and branemark system implants. *Clinical Oral Implants Research* **13**: 30-37.
- Ericsson, I., Nilson, H., Lindh, T., Nilner, K. & Randow, K. (2000) Immediate functional loading of branemark single tooth implants. An 18 months' clinical pilot follow-up study. *Clinical Oral Implants Research* **11**: 26-33.
- Esposito, M., Ekstubbe, A. & Grondahl, K. (1993) Radiological evaluation of marginal bone loss at tooth surfaces facing single branemark implants. *Clinical Oral Implants Research* **4**: 151-157.
- Evans, C.D. & Chen, S.T. (2008) Esthetic outcomes of immediate implant placements. *Clinical Oral Implants Research* **19**: 73-80.
- Furhauser, R., Florescu, D., Benesch, T., Haas, R., Mailath, G. & Watzek, G. (2005) Evaluation of soft tissue around single-tooth implant crowns: The pink esthetic score. *Clinical Oral Implants Research* **16**: 639-644.
- Garber, D.A. (1995) The esthetic dental implant: Letting restoration be the guide. *Journal of the American Dental Association* **126**: 319-325.
- Gargiulo, A.W., Wentz, F.M. & Orban, B. (1961) Dimensions and relations of the dentogingival junction in humans. *Journal of Periodontology* **32**: 261-267.
- Gastaldo, J.F., Cury, P.R. & Sendyk, W.R. (2004) Effect of the vertical and horizontal distances between adjacent implants and between a tooth and an implant on the incidence of interproximal papilla. *Journal of Periodontology* **75**: 1242-1246.
- Gehrke, P., Degidi, M., Lulay-Saad, Z. & Dhom, G. (2008a) Reproducibility of the implant crown esthetic index - rating esthetics of single-implant crowns and adjacent soft tissues with regard to observer dental specialization. *Clinical Implant Dentistry and Related Research* **xx**, 2008; 000-000. doi: 10.1111/j.1708-8208.2008.00107.x.
- Gehrke, P., Lobert, M. & Dhom, G. (2008b) Reproducibility of the pink esthetic score--rating soft tissue esthetics around single-implant restorations with regard to observer specialization. *Journal of Esthetic and Restorative Dentistry* **20**: 375-384; discussion 385.
- Gibbard, L.L. & Zarb, G. (2002) A 5-year prospective study of implant-supported single-tooth replacements. *Journal / Canadian Dental Association. Journal de l'Association Dentaire Canadienne* **68**: 110-116.
- Glantz, P.O., Nilner, K., Jendresen, M.D. & Sundberg, H. (1993) Quality of fixed prosthodontics after 15 years. *Acta Odontologica Scandinavica* **51**: 247-252.
- Glauser, R., Schupbach, P., Gottlow, J. & Hammerle, C.H. (2005) Periimplant soft tissue barrier at experimental one-piece mini-implants with different surface topography in humans: A light-microscopic overview and histometric analysis. *Clinical Implant Dentistry and Related Research* **7 Suppl 1**: S44-51.
- Goldstein, R.E. & Lancaster, J.S. (1984) Survey of patient attitudes toward current esthetic procedures. *Journal of Prosthetic Dentistry* **52**: 775-780.
- Goodacre, C.J., Bernal, G., Rungcharassaeng, K. & Kan, J.Y. (2003) Clinical complications with implants and implant prostheses. *Journal of Prosthetic Dentistry* **90**: 121-132.
- Gotfredsen, K. & Karlsson, U. (2001) A prospective 5-year study of fixed partial prostheses supported by implants with machined and tio2-blasted surface. *Journal of Prosthodontics* **10**: 2-7.
- Gotfredsen, K. (2004) A 5-year prospective study of single-tooth replacements supported by the astra tech implant: A pilot study. *Clinical Implant Dentistry and Related Research* **6**: 1-8.
- Grunder, U. (2000) Stability of the mucosal topography around single-tooth implants and adjacent teeth: 1-year results. *International Journal of Periodontics and Restorative Dentistry* **20**: 11-17.
- Haas, R., Mensdorff-Pouilly, N., Mailath, G. & Watzek, G. (1995) Branemark single tooth implants: A preliminary report of 76 implants. *Journal of Prosthetic Dentistry* **73**: 274-279.
- Hakestam, U., Karlsson, T., Soderfeldt, B., Ryden, O. & Glantz, P.O. (1997) Does the quality of advanced prosthetic dentistry determine patient satisfaction? *Acta Odontologica*

- Scandinavica* **55**: 365-371.
- Hansson, S. (1999) The implant neck: Smooth or provided with retention elements. A biomechanical approach. *Clinical Oral Implants Research* **10**: 394-405.
- Hansson, S. & Norton, M. (1999) The relation between surface roughness and interfacial shear strength for bone-anchored implants. A mathematical model. *Journal of Biomechanics* **32**: 829-836.
- Hansson, S. (2000) Implant-abutment interface: Biomechanical study of flat top versus conical. *Clinical Implant Dentistry and Related Research* **2**: 33-41.
- Hansson, S. (2003) A conical implant-abutment interface at the level of the marginal bone improves the distribution of stresses in the supporting bone. An axisymmetric finite element analysis. *Clinical Oral Implants Research* **14**: 286-293.
- Hatley, C.L., Cameron, S.M., Cuenin, M.F., Parker, M.H., Thompson, S.H. & Harvey, S.B. (2001) The effect of dental implant spacing on peri-implant bone using the rabbit (*Oryctolagus cuniculus*) tibia model. *Journal of Prosthodontics* **10**: 154-159.
- Hawkins, C.H., Sterrett, J.D., Murphy, H.J. & Thomas, J.C. (1991) Ridge contour related to esthetics and function. *Journal of Prosthetic Dentistry* **66**: 165-168.
- Heij, D.G., Opdebeeck, H., van Steenberghe, D., Kokich, V.G., Belser, U. & Quirynen, M. (2006) Facial development, continuous tooth eruption, and mesial drift as compromising factors for implant placement. *International Journal of Oral and Maxillofacial Implants* **21**: 867-878.
- Henriksson, K. & Jemt, T. (2004) Measurements of soft tissue volume in association with single-implant restorations: A 1-year comparative study after abutment connection surgery. *Clinical Implant Dentistry and Related Research* **6**: 181-189.
- Henry, P.J., Laney, W.R., Jemt, T., Harris, D., Krogh, P.H., Polizzi, G., Zarb, G.A. & Herrmann, I. (1996) Osseointegrated implants for single-tooth replacement: A prospective 5-year multicenter study. *International Journal of Oral and Maxillofacial Implants* **11**: 450-455.
- Hermann, J.S., Buser, D., Schenk, R.K., Higginbottom, F.L. & Cochran, D.L. (2000) Biologic width around titanium implants. A physiologically formed and stable dimension over time. *Clinical Oral Implants Research* **11**: 1-11.
- Hermann, J.S., Buser, D., Schenk, R.K., Schoolfield, J.D. & Cochran, D.L. (2001) Biologic width around one- and two-piece titanium implants. *Clinical Oral Implants Research* **12**: 559-571.
- Howells, D.J. & Shaw, W.C. (1985) The validity and reliability of ratings of dental and facial attractiveness for epidemiologic use. *American Journal of Orthodontics* **88**: 402-408.
- Huskisson, E.C. (1974) Measurement of pain. *Lancet* **2**: 1127-1131.
- Jemt, T., Lekholm, U. & Grondahl, K. (1990) 3-year followup study of early single implant restorations ad modum branemark. *International Journal of Periodontics and Restorative Dentistry* **10**: 340-349.
- Jemt, T., Carlsson, L., Boss, A. & Jorneus, L. (1991) In vivo load measurements on osseointegrated implants supporting fixed or removable prostheses: A comparative pilot study. *International Journal of Oral and Maxillofacial Implants* **6**: 413-417.
- Jemt, T., Book, K., Lie, A. & Borjesson, T. (1994) Mucosal topography around implants in edentulous upper jaws. Photogrammetric three-dimensional measurements of the effect of replacement of a removable prosthesis with a fixed prosthesis. *Clinical Oral Implants Research* **5**: 220-228.
- Jemt, T. (1997) Regeneration of gingival papillae after single-implant treatment. *International Journal of Periodontics and Restorative Dentistry* **17**: 326-333.
- Jemt, T. (1999) Restoring the gingival contour by means of provisional resin crowns after single-implant treatment. *International Journal of Periodontics and Restorative Dentistry* **19**: 20-29.
- Jemt, T. (2005) Measurements of tooth movements in relation to single-implant restorations during 16 years: A case report. *Clinical Implant Dentistry and Related Research* **7**: 200-208.
- Jemt, T., Ahlberg, G., Henriksson, K. & Bondevik, O. (2006) Changes of anterior clinical

- crown height in patients provided with single-implant restorations after more than 15 years of follow-up. *International Journal of Prosthodontics* **19**: 455-461.
- Jemt, T., Ahlberg, G., Henriksson, K. & Bondevik, O. (2007) Tooth movements adjacent to single-implant restorations after more than 15 years of follow-up. *International Journal of Prosthodontics* **20**: 626-632.
- Jornung, J. & Fardal, O. (2007) Perceptions of patients' smiles: A comparison of patients' and dentists' opinions. *Journal of the American Dental Association* **138**: 1544-1553; quiz 1613-1544.
- Jung, R.E., Pjetursson, B.E., Glauser, R., Zembic, A., Zwahlen, M. & Lang, N.P. (2008) A systematic review of the 5-year survival and complication rates of implant-supported single crowns. *Clinical Oral Implants Research* **19**: 119-130.
- Kalk, W., de Baat, C. & Kaandorp, A. (1991) Comparison of patients' views and dentists' evaluations 5 years after complete denture treatment. *Community Dentistry and Oral Epidemiology* **19**: 213-216.
- Kan, J.Y., Rungcharassaeng, K. & Lozada, J. (2003a) Immediate placement and provisionalization of maxillary anterior single implants: 1-year prospective study. *International Journal of Oral and Maxillofacial Implants* **18**: 31-39.
- Kan, J.Y., Rungcharassaeng, K., Umezu, K. & Kois, J.C. (2003b) Dimensions of peri-implant mucosa: An evaluation of maxillary anterior single implants in humans. *Journal of Periodontology* **74**: 557-562.
- Kawai, E.S. & Almeida, A.L. (2008) Evaluation of the presence or absence of papilla between tooth and implant. *Cleft Palate-Craniofacial Journal* **45**: 399-406.
- Kawanami, M., Andreasen, J.O., Borum, M.K., Schou, S., Hjorting-Hansen, E. & Kato, H. (1999) Infraposition of ankylosed permanent maxillary incisors after replantation related to age and sex. *Endodontics and Dental Traumatology* **15**: 50-56.
- Kim, B.S., Kim, Y.K., Yun, P.Y., Yi, Y.J., Lee, H.J., Kim, S.G. & Son, J.S. (2009) Evaluation of peri-implant tissue response according to the presence of keratinized mucosa. *Oral Surgery, Oral Medicine, Oral Pathology, Oral Radiology and Endodontics* **107**: e24-28.
- Kokich, V.O., Jr., Kiyak, H.A. & Shapiro, P.A. (1999) Comparing the perception of dentists and lay people to altered dental esthetics. *Journal of Esthetic Dentistry* **11**: 311-324.
- Krennmair, G., Piehslinger, E. & Wagner, H. (2003) Status of teeth adjacent to single-tooth implants. *International Journal of Prosthodontics* **16**: 524-528.
- Kupersmidt, I., Levin, L. & Schwartz-Arad, D. (2007) Inter-implant bone height changes in anterior maxillary immediate and non-immediate adjacent dental implants. *Journal of Periodontology* **78**: 991-996.
- Lai, H.C., Zhang, Z.Y., Wang, F., Zhuang, L.F., Liu, X. & Pu, Y.P. (2008) Evaluation of soft-tissue alteration around implant-supported single-tooth restoration in the anterior maxilla: The pink esthetic score. *Clinical Oral Implants Research* **19**: 560-564.
- Lamb, D.J. & Ellis, B. (1996) Comparisons of patient self-assessment of complete mandibular denture security. *International Journal of Prosthodontics* **9**: 309-314.
- Lamb, D.J., Ellis, B. & Patel, R. (1998) Restorative treatment need assessment by dentally and nondentally trained subjects. *Journal of Oral Rehabilitation* **25**: 34-39.
- Lamoureux, J., Tache, R. & de Grandmont, P. (1999) Patient evaluation of treatment success as related to denture tooth type. *International Journal of Prosthodontics* **12**: 272-278.
- Lang, N.P. & Lindhe, J. (2003) Maintenance of the implant patient. In: Lindhe, J., Karring, T. & Lang, N.P., eds. *Clinical Periodontology and Implant Dentistry*, 4th edition, p. 1024-1030. Oxford: Blackwell Munksgaard.
- Lazzara, R.J. & Porter, S.S. (2006) Platform switching: A new concept in implant dentistry for controlling postrestorative crestal bone levels. *International Journal of Periodontics and Restorative Dentistry* **26**: 9-17.
- Lee, D.W., Park, K.H. & Moon, I.S. (2005) Dimension of keratinized mucosa and the interproximal papilla between adjacent implants. *Journal of Periodontology* **76**: 1856-1860.
- Lee, D.W., Park, K.H. & Moon, I.S. (2006) Dimension of interproximal soft tissue between

- adjacent implants in two distinctive implant systems. *Journal of Periodontology* **77**: 1080-1084.
- Lee, D.W., Choi, Y.S., Park, K.H., Kim, C.S. & Moon, I.S. (2007) Effect of microthread on the maintenance of marginal bone level: A 3-year prospective study. *Clinical Oral Implants Research* **18**: 465-470.
- Lekholm, U. & Jemt, T. (1989) Principles for single tooth replacement. In: Albrektsson, T. & Zarb, G.A. eds. *The Brånemark Osseointegrated Implant*, 117-126. Chicago: Quintessence.
- Lekholm, U., Grondahl, K. & Jemt, T. (2006) Outcome of oral implant treatment in partially edentulous jaws followed 20 years in clinical function. *Clinical Implant Dentistry and Related Research* **8**: 178-186.
- Levi, A., Psoter, W.J., Agar, J.R., Reisine, S.T. & Taylor, T.D. (2003) Patient self-reported satisfaction with maxillary anterior dental implant treatment. *International Journal of Oral and Maxillofacial Implants* **18**: 113-120.
- Lindhe, J. & Meyle, J. (2008) Peri-implant diseases: Consensus Report of the Sixth European Workshop on Periodontology. *Journal of Clinical Periodontology* **35 suppl**: 282-285.
- Lops, D., Chiapasco, M., Rossi, A., Bressan, E. & Romeo, E. (2008) Incidence of interproximal papilla between a tooth and an adjacent immediate implant placed into a fresh extraction socket: 1-year prospective study. *Clinical Oral Implants Research* **19**: 1135-1140.
- Malevez, C., Hermans, M. & Daelemans, P. (1996) Marginal bone levels at branemark system implants used for single tooth restoration. The influence of implant design and anatomical region. *Clinical Oral Implants Research* **7**: 162-169.
- Martegani, P., Silvestri, M., Mascarello, F., Scipioni, T., Ghezzi, C., Rota, C. & Cattaneo, V. (2007) Morphometric study of the interproximal unit in the esthetic region to correlate anatomic variables affecting the aspect of soft tissue embrasure space. *Journal of Periodontology* **78**: 2260-2265.
- Marunick, M.T., Chamberlain, B.B. & Robinson, C.A. (1983) Denture esthetics: An evaluation of laymen's preferences. *Journal of Oral Rehabilitation* **10**: 399-406.
- Matthews, D.C. & McCulloch, C.A. (1993) Evaluating patient perceptions as short-term outcomes of periodontal treatment: A comparison of surgical and non-surgical therapy. *Journal of Periodontology* **64**: 990-997.
- McCord, J.F., Burke, T., Roberts, C. & Deakin, M. (1994) Perceptions of denture esthetics: A two-centre study of denture wearers and denture providers. *Australian Dental Journal* **39**: 365-367.
- McMillan, A.S., Allen, P.F. & Bin Ismail, I. (1998) A retrospective multicenter evaluation of single tooth implant experience at three centers in the united kingdom. *Journal of Prosthetic Dentistry* **79**: 410-414.
- Meijer, H.J., Stellingsma, K., Meijndert, L. & Raghoobar, G.M. (2005) A new index for rating esthetics of implant-supported single crowns and adjacent soft tissues--the implant crown esthetic index. *Clinical Oral Implants Research* **16**: 645-649.
- Meijering, A.C., Roeters, F.J., Mulder, J. & Creugers, N.H. (1997a) Patients' satisfaction with different types of veneer restorations. *Journal of Dentistry* **25**: 493-497.
- Meijering, A.C., Roeters, F.J., Mulder, J. & Creugers, N.H. (1997b) Recognition of veneer restorations by dentists and beautician students. *Journal of Oral Rehabilitation* **24**: 506-511.
- Meijndert, L., Meijer, H.J., Stellingsma, K., Stegenga, B. & Raghoobar, G.M. (2007) Evaluation of esthetics of implant-supported single-tooth replacements using different bone augmentation procedures: A prospective randomized clinical study. *Clinical Oral Implants Research* **18**: 715-719.
- Mitrani, R., Adolfi, D. & Tacher, S. (2005) Adjacent implant-supported restorations in the esthetic zone: Understanding the biology. *Journal of Esthetic and Restorative Dentistry* **17**: 211-222; discussion 222-213.
- Moberg, L.E., Kondell, P.A., Kullman, L., Heimdahl, A. & Gynther, G.W. (1999) Evaluation of single-tooth restorations on iti dental implants. A prospective study of 29 patients.

- Clinical Oral Implants Research* **10**: 45-53.
- Neumann, L.M., Christensen, C. & Cavanaugh, C. (1989) Dental esthetic satisfaction in adults. *Journal of the American Dental Association* **118**: 565-570.
- Noelken, R., Morbach, T., Kunkel, M. & Wagner, W. (2007) Immediate function with nobelperfect implants in the anterior dental arch. *International Journal of Periodontics and Restorative Dentistry* **27**: 277-285.
- Norton, M.R. (1998) Marginal bone levels at single tooth implants with a conical fixture design. The influence of surface macro- and microstructure. *Clinical Oral Implants Research* **9**: 91-99.
- Norton, M.R. (2006) Multiple single-tooth implant restorations in the posterior jaws: Maintenance of marginal bone levels with reference to the implant-abutment microgap. *International Journal of Oral and Maxillofacial Implants* **21**: 777-784.
- Novaes, A.B., Jr., Papalexiou, V., Muglia, V. & Taba, M., Jr. (2006a) Influence of interimplant distance on gingival papilla formation and bone resorption: Clinical-radiographic study in dogs. *International Journal of Oral and Maxillofacial Implants* **21**: 45-51.
- Novaes, A.B., Jr., de Oliveira, R.R., Muglia, V.A., Papalexiou, V. & Taba, M. (2006b) The effects of interimplant distances on papilla formation and crestal resorption in implants with a morse cone connection and a platform switch: A histomorphometric study in dogs. *Journal of Periodontology* **77**: 1839-1849.
- Nyman, S. & Lindhe, J. (2003) Examination of patients with periodontal disease. In: Lindhe, J., Karring, T. & Lang, N.P., eds. *Clinical periodontology and implant dentistry*, 4th edition, p. 403-413. Oxford: Blackwell Munksgaard.
- Odman, P., Nilsson, E. & Pietruszka, K. (1998) Cerana--a new method for the restoration of teeth with prefabricated ceramic inlays. *Journal of Oral Rehabilitation* **25**: 340-347.
- Olsson, M., Lindhe, J. & Marinello, C.P. (1993) On the relationship between crown form and clinical features of the gingiva in adolescents. *Journal of Clinical Periodontology* **20**: 570-577.
- Palacci, P., Ericsson, I. & Engstrand, P. (1995) Implant placement. In: Palacci, P., Ericsson, I., Engstrand, P. & Rangert, B., eds. *Optimal Implant Positioning & Soft Tissue Management for the Brånemark System*, p. 35-39. Chicago, Quintessence.
- Palmer, R.M., Palmer, P.J. & Smith, B.J. (2000) A 5-year prospective study of astra single tooth implants. *Clinical Oral Implants Research* **11**: 179-182.
- Palmer, R.M., Farkondeh, N., Palmer, P.J. & Wilson, R.F. (2007) Astra tech single-tooth implants: An audit of patient satisfaction and soft tissue form. *Journal of Clinical Periodontology* **34**: 633-638.
- Phillips, K. & Kois, J.C. (1998) Esthetic peri-implant site development. The restorative connection. *Dental Clinics of North America* **42**: 57-70.
- Pjetursson, B.E., Tan, K., Lang, N.P., Bragger, U., Egger, M. & Zwahlen, M. (2004) A systematic review of the survival and complication rates of fixed partial dentures (fpds) after an observation period of at least 5 years. *Clinical Oral Implants Research* **15**: 625-642.
- Poggio, C.E. & Salvato, A. (2001) Implant repositioning for esthetic reasons: A clinical report. *Journal of Prosthetic Dentistry* **86**: 126-129.
- Priest, G.F. (1996) Esthetic comparisons of alternatives for replacement of a single missing tooth. *Journal of Esthetic Dentistry* **8**: 58-65.
- Priest, G. (2003) Predictability of soft tissue form around single-tooth implant restorations. *International Journal of Periodontics and Restorative Dentistry* **23**: 19-27.
- Qualtrough, A.J. & Burke, F.J. (1994) A look at dental esthetics. *Quintessence International* **25**: 7-14.
- Reikie, D.F. (1993) Esthetic and functional considerations for implant restoration of the partially edentulous patient. *Journal of Prosthetic Dentistry* **70**: 433-437.
- Reikie, D.F. (1995) Restoring gingival harmony around single tooth implants. *Journal of Prosthetic Dentistry* **74**: 47-50.
- Romeo, E., Lops, D., Rossi, A., Storelli, S., Rozza, R. & Chiapasco, M. (2008) Surgical and

- prosthodontic management of interproximal region with single-implant restorations: 1-year prospective study. *Journal of Periodontology* **79**: 1048-1055.
- Rompen, E., Raepsaet, N., Domken, O., Touati, B. & Van Dooren, E. (2007) Soft tissue stability at the facial aspect of gingivally converging abutments in the esthetic zone: A pilot clinical study. *Journal of Prosthetic Dentistry* **97**: S119-125.
- Ryser, M.R., Block, M.S. & Mercante, D.E. (2005) Correlation of papilla to crestal bone levels around single tooth implants in immediate or delayed crown protocols. *Journal of Oral and Maxillofacial Surgery* **63**: 1184-1195.
- Scarano, A., Assenza, B., Piattelli, M., Thams, U., San Roman, F., Favero, G.A. & Piattelli, A. (2004) Interimplant distance and crestal bone resorption: A histologic study in the canine mandible. *Clinical Implant Dentistry and Related Research* **6**: 150-156.
- Scheller, H., Urgell, J.P., Kultje, C., Klineberg, I., Goldberg, P.V., Stevenson-Moore, P., Alonso, J.M., Schaller, M., Corria, R.M., Engquist, B., Toreskog, S., Kastenbaum, F. & Smith, C.R. (1998) A 5-year multicenter study on implant-supported single crown restorations. *International Journal of Oral and Maxillofacial Implants* **13**: 212-218.
- Schropp, L., Kostopoulos, L. & Wenzel, A. (2003) Bone healing following immediate versus delayed placement of titanium implants into extraction sockets: A prospective clinical study. *International Journal of Oral and Maxillofacial Implants* **18**: 189-199.
- Schropp, L. & Isidor, F. (2008) Clinical outcome and patient satisfaction following full-flap elevation for early and delayed placement of single-tooth implants: A 5-year randomized study. *International Journal of Oral and Maxillofacial Implants* **23**: 733-743.
- Shin, Y.K., Han, C.H., Heo, S.J., Kim, S. & Chun, H.J. (2006) Radiographic evaluation of marginal bone level around implants with different neck designs after 1 year. *International Journal of Oral and Maxillofacial Implants* **21**: 789-794.
- Small, P.N. & Tarnow, D.P. (2000) Gingival recession around implants: A 1-year longitudinal prospective study. *International Journal of Oral and Maxillofacial Implants* **15**: 527-532.
- Smedberg, J.I., Lothigius, E., Bodin, I., Frykholm, A. & Nilner, K. (1993) A clinical and radiological two-year follow-up study of maxillary overdentures on osseointegrated implants. *Clinical Oral Implants Research* **4**: 39-46.
- Spitzer, D., Kastenbaum, F. & Wagenberg, B. (1992) Achieving ideal esthetics in osseointegrated prostheses. Part ii. The single unit. *International Journal of Periodontics and Restorative Dentistry* **12**: 500-507.
- Streiner, D.L. & Norman, G.R. (1995) Devising the items, Scaling responses & Biases in responding. In: Streiner, D.L. & Norman, G.R. eds. *Health Measurement Scales: A practical guide to their development and use*, 15-27, 28-53 & 69-84. Oxford: Oxford University Press.
- Suissa, S. (1991) Binary methods for continuous outcomes: A parametric alternative. *Journal of Clinical Epidemiology* **44**: 241-248.
- Takei, H., Yamada, H. & Hau, T. (1989) Maxillary anterior esthetics. Preservation of the interdental papilla. *Dental Clinics of North America* **33**: 263-273.
- Tammaro, S., Berggren, U. & Bergenholtz, G. (1997) Representation of verbal pain descriptors on a visual analogue scale by dental patients and dental students. *European Journal of Oral Sciences* **105**: 207-212.
- Tarlow, J.L. (2004) The effect of adult growth on an anterior maxillary single-tooth implant: A clinical report. *Journal of Prosthetic Dentistry* **92**: 213-215.
- Tarnow, D.P., Magner, A.W. & Fletcher, P. (1992) The effect of the distance from the contact point to the crest of bone on the presence or absence of the interproximal dental papilla. *Journal of Periodontology* **63**: 995-996.
- Tarnow, D.P., Cho, S.C. & Wallace, S.S. (2000) The effect of inter-implant distance on the height of inter-implant bone crest. *Journal of Periodontology* **71**: 546-549.
- Tarnow, D., Elian, N., Fletcher, P., Froum, S., Magner, A., Cho, S.C., Salama, M., Salama, H. & Garber, D.A. (2003) Vertical distance from the crest of bone to the height of the interproximal papilla between adjacent implants. *Journal of Periodontology* **74**: 1785-1788.

- Thilander, B., Odman, J. & Jemt, T. (1999) Single implants in the upper incisor region and their relationship to the adjacent teeth. An 8-year follow-up study. *Clinical Oral Implants Research* **10**: 346-355.
- Thilander, B., Odman, J. & Lekholm, U. (2001) Orthodontic aspects of the use of oral implants in adolescents: A 10-year follow-up study. *European Journal of Orthodontics* **23**: 715-731.
- Tjan, A.H., Miller, G.D. & The, J.G. (1984) Some esthetic factors in a smile. *Journal of Prosthetic Dentistry* **51**: 24-28.
- Vallittu, P.K., Vallittu, A.S. & Lassila, V.P. (1996) Dental esthetics--a survey of attitudes in different groups of patients. *Journal of Dentistry* **24**: 335-338.
- Vermeylen, K., Collaert, B., Linden, U., Bjorn, A.L. & De Bruyn, H. (2003) Patient satisfaction and quality of single-tooth restorations. *Clinical Oral Implants Research* **14**: 119-124.
- Wagner, I.V., Carlsson, G.E., Ekstrand, K., Odman, P. & Schneider, N. (1996) A comparative study of assessment of dental appearance by dentists, dental technicians, and laymen using computer-aided image manipulation. *Journal of Esthetic Dentistry* **8**: 199-205.
- Wannfors, K. & Smedberg, J.I. (1999) A prospective clinical evaluation of different single-tooth restoration designs on osseointegrated implants. A 3-year follow-up of branemark implants. *Clinical Oral Implants Research* **10**: 453-458.
- Watson, J.F. & Crispin, B.J. (1981) Margin placement of esthetic veneer crowns. Part iii: Attitudes of patients and dentists. *Journal of Prosthetic Dentistry* **45**: 499-501.
- Watson, R.M., Jemt, T., Chai, J., Harnett, J., Heath, M.R., Hutton, J.E., Johns, R.B., Lithner, B., McKenna, S., McNamara, D.C., Naert, I. & Taylor, R. (1997) Prosthodontic treatment, patient response, and the need for maintenance of complete implant-supported overdentures: An appraisal of 5 years of prospective study. *International Journal of Prosthodontics* **10**: 345-354.
- Wennstrom, J.L. (1996) Mucogingival considerations in orthodontic treatment. *Seminars in Orthodontics* **2**: 46-54.
- Wennstrom, J.L., Ekestubbe, A., Grondahl, K., Karlsson, S. & Lindhe, J. (2004) Oral rehabilitation with implant-supported fixed partial dentures in periodontitis-susceptible subjects. A 5-year prospective study. *Journal of Clinical Periodontology* **31**: 713-724.
- Wennstrom, J.L., Ekestubbe, A., Grondahl, K., Karlsson, S. & Lindhe, J. (2005) Implant-supported single-tooth restorations: A 5-year prospective study. *Journal of Clinical Periodontology* **32**: 567-574.
- Wise, M. D. (1995) Examination procedure In: Wise, M.D., eds. *Failure in the restored dentition: Management and treatment*, p. 93-95. Chicago, Quintessence.
- Wood, M., Thompson, V.P., Romberg, E. & Morrison, G. (1996) Resin-bonded fixed partial dentures. Ii. Clinical findings related to prosthodontic characteristics after approximately 10 years. *Journal of Prosthetic Dentistry* **76**: 368-373.
- Wyatt, C.C., Bryant, S.R., Avivi-Arber, L., Chaytor, D.V. & Zarb, G.A. (2001) A computer-assisted measurement technique to assess bone proximal to oral implants on intraoral radiographs. *Clinical Oral Implants Research* **12**: 225-229.
- Yi, S.W., Carlsson, G.E., Ericsson, I. & Kim, C.K. (2001) Patient evaluation of treatment with fixed implant-supported partial dentures. *Journal of Oral Rehabilitation* **28**: 998-1002.
- Zarb, G.A. & Albrektsson, T. (1998) Consensus report: Towards optimized treatment outcomes for dental implants. *Journal of Prosthetic Dentistry* **80**: 641.
- Zarone, F., Sorrentino, R., Vaccaro, F. & Russo, S. (2006) Prosthetic treatment of maxillary lateral incisor agenesis with osseointegrated implants: A 24-39-month prospective clinical study. *Clinical Oral Implants Research* **17**: 94-101.
- Zigdon, H. & Machtei, E.E. (2008) The dimensions of keratinized mucosa around implants affect clinical and immunological parameters. *Clinical Oral Implants Research* **19**: 387-392.

APPENDIX I

Questionnaire presented to the patients

Place a mark (X) on the line that best indicates how you felt.

1) How satisfied are you with the **form** of your implant-supported crown ?

Not at all satisfied Completely satisfied

2) How satisfied are you with the **color** of your implant-supported crown ?

Not at all satisfied Completely satisfied

3) How satisfied are you with your **smile** after having the implant-supported crown?

Not at all satisfied Completely satisfied

4) How satisfied are you with the appearance of your implant-supported crown **in comparison to your contralateral natural teeth** ?

Not at all satisfied Completely satisfied

5) How satisfied are you with the **appearance** of your implant-supported crown?

Not at all satisfied Completely satisfied

6) How much would you object (concern) if the abutment metal does show?

Not at all important Very important

- 7) What is the more important to you between optimum esthetics and optimum health potential ?
- Optimum esthetics
 - Optimum health potential

- 8) How satisfied are you **generally** with your implant supported crown ?

Not at all satisfied Completely satisfied

- 9) Would you like to change anything about your implant-supported crown?
- Yes, If so, what? _____
 - No

Esthetic evaluation form presented to the dentists

Place a mark (X) on the line that best indicates how you assessed.

Smile view

1) Which tooth do you think is replaced by an implant-supported crown(s)? _____

2) How satisfied are you with the appearance of the patient's implant-supported crown?

Not at all satisfied Completely satisfied

Intra-oral view

Crown

3) Color of cervical half; Harmonious in comparison with adjacent teeth and the contralateral tooth

Not at all satisfied Completely satisfied

4) Color of incisal half; Harmonious in comparison with adjacent teeth and the contralateral tooth

Not at all satisfied Completely satisfied

5) Form; Harmonious in comparison with adjacent teeth and the contralateral tooth

Not at all satisfied Completely satisfied

6) Texture of the reflecting surface; Harmonious in comparison with adjacent teeth and the contralateral tooth

Not at all satisfied Completely satisfied

7) Contact point position; Contact properly positioned

Not at all satisfied Completely satisfied

Soft tissues

8) Soft tissue appearance; Harmonious in comparison with adjacent teeth and the contralateral tooth

Not at all satisfied Completely satisfied

9) How satisfied are you with the appearance of the patient's implant supported crown?

Not at all satisfied Completely satisfied